

Case report

A rare presentation of Tuberculosis as a splenic abscess

ABSTRACT

Aims: Splenic tubercular abscess is a very unusual clinical presentation in an immunocompetent host. This rare clinical condition which can occur in two forms. The first form where splenic involvement is seen as a part of miliary Tuberculosis especially in immune-compromised individuals. The second form is the primary involvement of the spleen which is extremely rare

Presentation of the case: We encountered a case of a middle aged immunocompetent male who presented with vague pain in the left hypochondrium for 3 months duration and fever for 3 days. On clinical examination he had tenderness over the left hypochondrium. On admission he had lymphocytosis with elevated ESR. His Mantoux test was positive. CT scan abdomen revealed multiple hypodensities in spleen, the largest measuring 12x11mm and suspected to be granulomas of Tuberculosis. Laparoscopic splenectomy was done. Histopathological examination showed large areas of caseation surrounded by multiple granulomas of epithelioid and Langerhans type of giant cells suggestive of tuberculosis. No primary focus of tuberculosis was detected in lungs or other organs. Anti-tubercular therapy was started and the patient became afebrile and his general condition improved.

Discussion: Splenic involvement was generally thought to be seen only in immunocompromised stages. However, there are sporadic case reports of splenic Tuberculosis in immunocompetent patients such as ours. Where splenic involvement is seen as a part of miliary Tuberculosis especially in immune-compromised individuals, which is less rare, the treatment includes classic antituberculous treatment, and surgical intervention is required as a rare exception. The second form, which is the primary involvement of the spleen, is extremely rare. Early splenectomy followed by oral antituberculous drugs may be considered the more appropriate approach for this entity.

Conclusion: Tuberculosis may have protean manifestations and becomes difficult to diagnose when it presents in an uncommon extrapulmonary site. Hence, although primary splenic tuberculosis is extremely rare, it should be also considered among the differential diagnoses of abscesses in the spleen in the regions with high prevalence of Tuberculosis.

Keywords: Primary tubercular abscess of spleen, immunocompetent.

1. INTRODUCTION

Though Tuberculosis continues to be a common infectious disease in large parts of the modern world, isolated Tuberculosis of the spleen is an extremely rare manifestation of the disease. The symptoms and signs of splenic Tuberculosis may be non-specific and confusing and this makes the diagnosis challenging. Abdominal pain, fever, and weight loss have been reported as the common symptoms. However, completely asymptomatic cases have also

been reported. A tubercular etiology must be considered for isolated splenic lesions even amongst immunocompetent patients in the regions with high prevalence of tuberculosis.

2. PRESENTATION OF CASE

A 50-year-old hypertensive south Indian male presented with a history of vague intermittent, dragging pain in the left hypochondrium for 3 months and fever for 3 days. He had no history of weight loss or vomiting. He had been previously diagnosed to have multiple gastric antral ulcers. On clinical examination, no pallor, icterus, cyanosis, clubbing, lymphadenopathy or edema was noted. He was febrile with a temperature of 100F and he had a heart rate 110/min and BP of 130/80mmHg.

On abdominal examination, there was tenderness over the left hypochondrium.

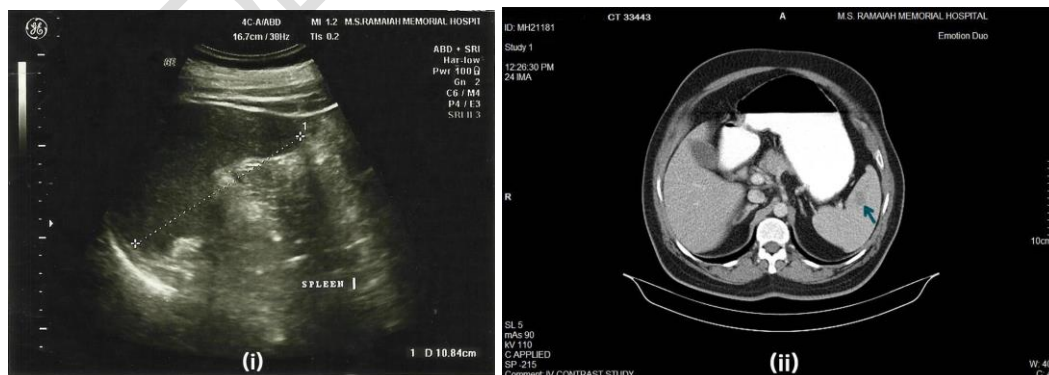
On admission his Hemoglobin was 16.3g/dl, total leucocytes of 10,890/dl, platelet count was 3,33000/dl and the ESR was 33mm/hr. Renal function was normal and AST-72.9U/L, ALP-107U/L. Serum Procalcitonin was 6.08. The urine routine showed 2-3 WBC/hpf and protein 1+. He was euglycemic and serological tests for Hepatitis B, Hepatitis C and HIV were negative. His Mantoux test was positive. Chest X ray was normal. 2D ECHO showed concentric left ventricular hypertrophy. Ultrasound abdomen and pelvis revealed multiple small vesicular lesions resembling splenic abscesses. (Figure 1).

CT abdomen revealed multiple hypodensities in spleen, largest measuring 12x11mm, which were suspected to be of tubercular etiology. (Figure2). Laparoscopic splenectomy was done.(Figure 3).

Histopathological examination revealed large areas of caseation surrounded by multiple granulomas of epithelioid and Langerhans Type Giant Cells typical of Tuberculosis.

Antitubercular therapy started following which the patient became afebrile and his general condition improved. He was discharged after 7 days. He received Antitubercular therapy with 2 months of Isoniazid (INH), Rifampicin , Pyrazinamide , and Ethambutol and a further 10 months of INH and Rifampicin.

The patient was asymptomatic and clinically stable on follow ups at 4 weeks,4 months,12 months and 24 months.






Fig. 1. Ultrasound abdomen and pelvis showing multiple small vesicular lesions resembling splenic abscesses.(indicated by the arrow)

Fig. 2. CT scan of the abdomen showing multiple hypodensities in spleen

Fig. 3. The enlarged spleen photographed post laparoscopic splenectomy.

3. DISCUSSION

Extra pulmonary Tuberculosis accounts for almost 15% of all cases of Tuberculosis. Among extra-pulmonary forms, splenic Tuberculosis is an exceptionally rare clinical condition which can occur in two forms. The first form where splenic involvement is seen as a part of miliary Tuberculosis especially in immune-compromised individuals, which is less rare, and its treatment includes classic antituberculous treatment, which might improve patients overall immunity 1 , 2 . This form requires surgical intervention as a rare exception 2 . The second form is the primary involvement of the spleen which is extremely rare 2 .

Splenic involvement was generally thought to be seen only in the immunocompromised stages. However, there are sporadic case reports of splenic Tuberculosis in immunocompetent patients 3 . The existence of such a clinical entity has been suspected as early as the 1930s 4 . However, in English, French and German literature dating from 1965 to 1992 just six cases were reported 5 . Unlike most most previously reported cases, our patient was immunocompetent and had only a short history of fever. Additionally, there was no other affected site. When the spleen is involved as an isolated organ, patient may have solitary tuberculous granuloma or tubercular abscess 5. In general, abscesses of the spleen are uncommon clinical entities and a tuberculous splenic abscess is particularly rare 6 . The common presenting clinical features are Pyrexia of Unknown Origin and thrombocytopenia. Our case showed that the presentation could also be with vague pain in the left hypochondrium without PUO or weight loss. Tuberculosis is difficult to diagnose when it presents in an uncommon extrapulmonary site. So, although splenic Tuberculosis is rare at the present time, it should be included in the differential diagnosis of pyrexia of unknown origin with splenomegaly 3,5 . It has been suggested that tuberculous splenic abscess should not be treated by anti tuberculous antibiotics alone and an early splenectomy followed by oral antituberculous drugs has been advised by some authors as a better approach 7 .

4. CONCLUSION

Tuberculosis may have protean manifestations and becomes difficult to diagnose when it presents in an uncommon extrapulmonary site. Hence, although primary splenic tuberculosis is extremely rare, it should be also considered among the differential diagnoses of abscesses in the spleen in the regions with high prevalence of Tuberculosis.

REFERENCES

1. Agarwala S, Bhatnagar V, Mitra DK, et al. Primary tubercular abscess of spleen. *J Pediatr Surg.* 1992; 27(12): 1580-1581.
2. Reichel C, Theisen A, Rockstroh JK, et al. Splenic abscess and abdominal tuberculosis in patients with AIDS. *Z-gastroenterol.* 1996 Aug; 34(8): 494-496.
3. Kogo H, Yoshida H, Mamada Y, Taniai N, Bando K, Mizuguchi Y, et al. Successful percutaneous ultrasound-guided drainage for treatment of a splenic abscess. *J Nippon Med Sch* 2007;74:257-260.
4. Gabriel WB. Primary tuberculosis of the spleen. *Proceedings of the Royal Society of Medicine* 46,1932; Clinical section 375-376.
5. Joshi S, Bankar M, Kagal A, Rane S, Bharadwaj R, Phadke M. Splenic tuberculosis– a rare case report. *Internet Journal of Medical Update* 2007 Jul-Dec;2(2):38-41.
6. Bhandarkar D, Katara A, Shankar M, Mittal G, Udwadia TE. Laparoscopic splenectomy for tuberculous abscess of the spleen. *Journal of Minimal Access Surgery* . 07/2010; 6(3):83-85.
7. Nayyar V, Ramakrishna B, Mathew G, et al. Response to antituberculous chemotherapy after splenectomy. *J Intern Med.* 1993; 233(1): 81-83.