

Laparoscopic assisted gastrostomy: A case report

ABSTRACT

Introduction: Percutaneous endoscopic gastrostomy (PEG), which was initially developed in 1980 by Gauderer and Ponsky for pediatric patients who were not consuming enough nutrition, has changed the way feeding tubes are placed by offering a dependable and safe alternative to laparotomy with a low rate of associated morbidity. PEG is now widely accepted.

Case presentation: We hereby report a case of a patient having undergone a laparoscopic-assisted percutaneous gastrostomy (LAPG) in our institution that was successfully attempted in an adult with laryngeal cancer and total dysphagia.

Discussion: There are different techniques for gastrostomy tube placement: open gastrostomy, PEG, and radiologic procedure. The PEG is associated with a significant risk of bowel perforation.

For those individuals in whom a PEG cannot be performed, LAPG appears to be a promising alternative for preventing an open gastrostomy. This is particularly true for obese individuals, in whom a transillumination is not feasible. In addition to the laparoscopic procedure, it provides an endoscopic view of the stomach, potentially reducing serious consequences.

Conclusion: This laparoscopic gastrostomy procedure should be particularly useful in patients for whom the endoscopic passage is not possible due to stenosis of the neck or esophagus. This technique allows a safe direct visualization of the stomach and other adjacent organs.

Keywords: PEG, LAPG, gastrostomy, laparoscopic.

INTRODUCTION:

Laparoscopic gastrostomy is a stoma equipped with a feeding tube placed in the stomach via a laparoscopic and percutaneous route (1-4).

This device enables medium- to long-term enteral feeding, and is widely indicated for patients suffering from dysphagia and when the gastric cavity is not accessible endoscopically or radiologically, or in cases of total or partial gastrectomy for jejunal nutritional access if the endoscopic route is not possible. (5,10-12). The success rate is 100% .

The aim of this case is to highlight the interest and contribution of this technique as an alternative feeding route to the endoscopic and radiological routes in dysphagic patients.

CASE PRESENTATION :

We report the case of a 68-year-old man who was hospitalized in our department for laryngeal cancer and presented with total dysphagia, necessitating the placement of a feeding gastrostomy.

Clinical examination found a patient in poor general condition, hemodynamically and respiratory stable, with no contraindications to anesthesia. The patient was prepared for laparoscopic gastrostomy tube placement.

After general anesthesia, the patient is placed in the supine position with legs apart, and conditioned, followed by the creation of the pneumoperitoneum and placement of trocars under visual control. Then we located the gastrostomy point at the level of the greater curvature and we made two reference points with silicone braided thread, which will be used for gastropexy.

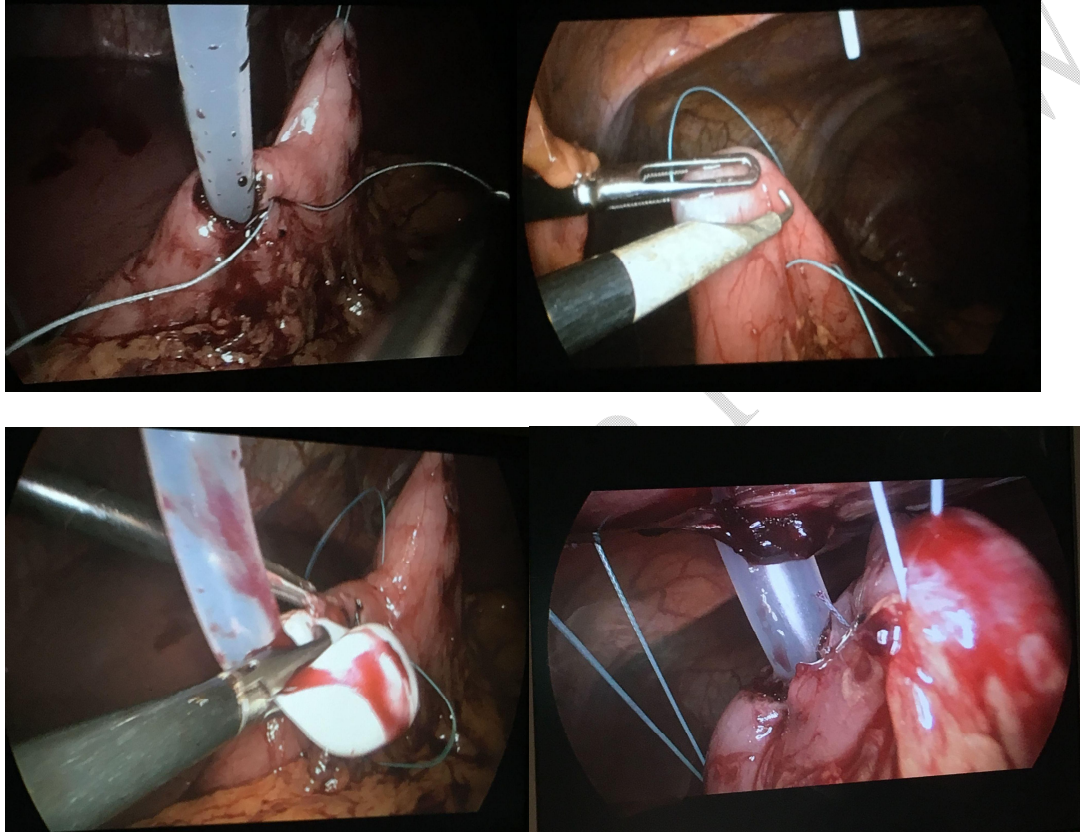


Fig 1:Images showing a laparoscopic view of the laparoscopic gastrostomy with gastropexy using two straight needles.

Then we carried out a percutaneous introduction of the intragastric tube, followed by the fixation of the gastrostomy orifice with 2 purse strings suture and we sutured the anterior wall of the gastric body to the abdominal wall (Fig 1) before the gas exsufflation and closure of trocar sites. (Fig 2)

The average operating time was 80 minutes, the postoperative course was uneventful, and feeding was started on the first postoperative day in all cases.

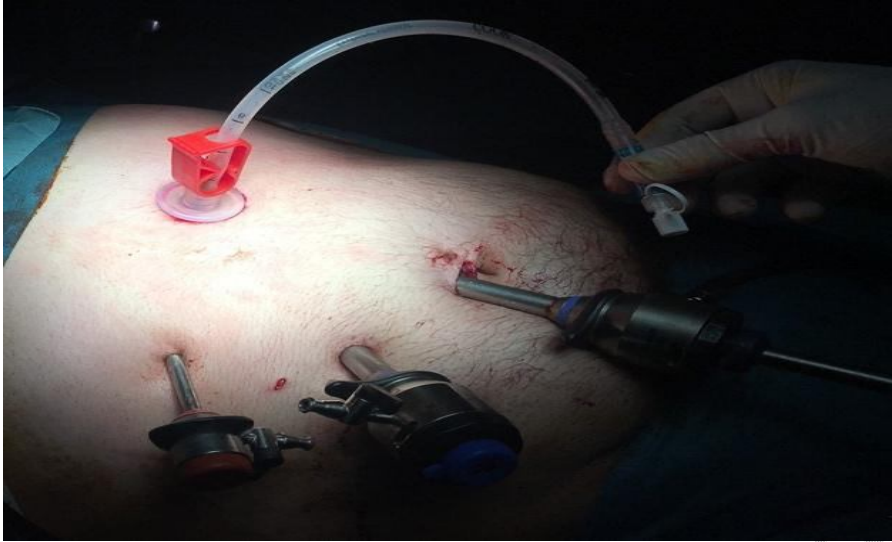

Fig 2: Final result of the gastrostomy and the trocars positions.

DISCUSSION :

In this case, we have used as technic the laparoscopic gastrostomy with laparoscopic gastropexy.

The sutureless 'pull method' for PEG has become a widespread endoscopic technique for transcutaneous gastric long-term nutrition.

"However, if the gastropexy was not successfully performed, early dislodgement of the PEG tube may lead to peritonitis, and blind reinsertion should not be attempted" (6)

"Furthermore, gastropexy can prevent gastric hemorrhage, inadvertent tube migration into the peritoneum, and leakage of gastric contents into the peritoneal cavity" (7).

"Thus, the tube placement along with laparoscopic gastropexy presented here should be a safe and feasible method for patients in whom the endoscopic passage is not feasible". [13] Dormann et al. (8) reported that "long-term follow-up in patients with gastrostomy using this gastropexy kit revealed only 2.1% peristomal infection and without any serious complications". Bolder et al. (9) demonstrated that "technic providing enteral access for patients with pharyngoesophageal obstruction was not suitable for PEG placement".

"This minimally invasive gastrostomy procedure, although it does require general anesthesia, should prove to be especially useful in patients in whom endoscopic passage is not possible due to a neck obstruction or esophageal stenosis, or who are suspected of having organs overlying the stomach due to obesity or previous upper abdominal surgery". [13]

CONCLUSION:

There are several techniques for inserting a gastrostomy. At present, the endoscopic technique is the most widely used.

Patients whose stenosis in the laryngopharyngeal carrefour prevents endoscopic passage should be specifically considered for this laparoscopic gastrostomy operation.

CONSENT:

Written informed consent was obtained from the patient for publication of this case report and any accompanying images.

ETHICAL APPROVAL :

As per international standards or university standards written ethical approval has been collected and preserved by the author(s).

Disclaimer (Artificial intelligence)

Option 1:

Author(s) hereby declare that NO generative AI technologies such as Large Language Models (ChatGPT, COPILOT, etc) and text-to-image generators have been used during writing or editing of manuscripts.

Option 2:

Author(s) hereby declare that generative AI technologies such as Large Language Models, etc have been used during writing or editing of manuscripts. This explanation will include the name, version, model, and source of the generative AI technology and as well as all input prompts provided to the generative AI technology

Details of the AI usage are given below:

- 1.
- 2.
- 3.

REFERENCES :

- (1) Gauderer MW, Ponsky JL, Izant RJ., Jr Gastrostomy without laparotomy: a percutaneous endoscopic technique. *J Pediatr Surg.* 1980;15(6):872–875
- (2) Silas , Pearce L.F., Lestina L.S., et. al.: Percutaneous radiologic gastrostomy versus percutaneous endoscopic gastrostomy: a comparison of indications, complications and outcomes in 370 patients. *Eur. J. Radiol.* 2005; 56: pp. 84-90.
- (3) Lopes ,Salcone M., Neff M.: Laparoscopic-assisted percutaneous endoscopic gastrostomy tube placement. *JLS* 2010; 14: pp. 66-69.
- (4) Shimizu ,Okuyama H., Sasaki T., et. al.: Laparoscopic-assisted percutaneous endoscopic gastrostomy: a simple and efficient technique for disabled elderly patients. *JPEN J. Parenter. Enteral. Nutr.* 2014; 38: pp. 475-480.

- (5) Larson , Burton D.D., Schroeder K.W., et. al.: Percutaneous endoscopic gastrostomy: indications, success, complications, and mortality in 314 consecutive patients. *Gastroenterology* 1987; 93: pp. 48-52.
- (6) Minchff TV: Early dislodgement of percutaneous and endoscopic gastrostomy tube. *J S C Med Assoc* 2007;103:13–15.
- (7) Saini S, Mueller PR, Gaa J, Briggs SE, Hahn PF, Forman BH, Tung GA, Silverman SG, Lee MJ, Morrison MC: Percutaneous gastrostomy with gastropexy: experience in 125 patients. *AJR Am J Roentgenol* 1990;154:1003–1006.
- (8) Dormann AJ, Wejda B, Kahl S, Huchzermeyer H, Ebert MP, Malfertheiner P: Long-term results with a new introducer method with gastropexy for percutaneous endoscopic gastrostomy. *Am J Gastroenterol* 2006;101:1229–1234.
- (9) Bolder U, Scherer MN, Schmidt T, Hornung M, Schlitt HJ, Vogel P: Percutaneous laparoscopic assisted gastrostomy (PLAG) – a new technique for cases of pharyngoesophageal obstruction. *Langenbecks Arch Surg* 2010;395:1107–1113.
10. Chukwurah SN, Menkiti FE, Ufoaroh CU, Ofiaeli OC, Chigbo CG, Okoye AOA. Clinical, Endoscopic and Histopathological Patterns among Patients with Dyspepsia. *Asian J. Med. Health*. [Internet]. 2023 Jul. 5 [cited 2024 May 22];21(9):154-65. Available from: <https://journalajmah.com/index.php/AJMAH/article/view/869>
11. Jatal SN, Jatal S, Jatal S, Swami G. Annular Pancreas with Intestinal Malrotation in 12 Years' Girl: A Rare Case Report. *Asian J. Res. Surg*. [Internet]. 2023 Dec. 1 [cited 2024 May 22];6(2):340-7. Available from: <https://journalajrs.com/index.php/AJRS/article/view/177>
12. Ponsky JL, Capone AC. Percutaneous endoscopic gastrostomy. In *Operative Endoscopic and Minimally Invasive Surgery* 2019 Mar 7 (pp. 140-147). CRC Press.
13. Tsujimoto H, Yaguchi Y, Kumano I, Matsumoto Y, Yoshida K, Hase K. Laparoscopy-assisted percutaneous gastrostomy tube placement along with laparoscopic gastropexy. *Digestive Surgery*. 2011 Jun 1;28(3):163-6.