Case report

TAKO-TSUBO mimicking a myocardial infarction in a young man: clinical case with review of the literature

Abstract

Stress cardiomyopathy or Tako-Tsubo syndrome is a heart disease which is most likely linked to an excessive discharge of catecholamines triggered by physical or emotional stress responsible for myocardial toxicity. Tako-tsubo constitutes the main differential diagnosis of an acute coronary syndrome. Women are most affected, but recently more and more men are described in the literature.

We describe here the case of a 45-year-old smoking man, followed for a manic-depressive illness who consulted for chest pain typical of ACS and in whom coronary angiography, transthoracic echocardiography, ventriculography and imaging cardiac magnetic resonance led to the diagnosis of Tako-Tsubo syndrome.

Keywords: Tako-Tsubo, Ventriculography, Heart failure

UNDER PEER REVIEW

INTRODUCTION:

Known as “stress cardiomyopathy” or “broken heart syndrome,” tako tsubo syndrome (TTS) is a disease usually triggered by emotional or physical stress [1].

It is characterized by transient regional left ventricular systolic dysfunction, the most implicated physiopathological mechanism of which is the toxicity of catecholaminergic discharge on cardiomyocytes[2]. Tako-Tsubo syndrome has been reported in approximately 1 to 3% of all suspected presentations of acute coronary syndrome “positive troponins” “electrical changes such as ST segment elevation, negative T waves in the anterior territory evolving toward giant T waves associated with prolonged QT.

Men are ten times less affected than women. The difficulty in diagnosing TTS lies in its very close proximity to its main differential diagnosis, ACS. Diagnostic criteria (InterTAK criteria) have been proposed, with the aim of guiding diagnostic management. The diagnosis is made by ventriculography revealing apical hypo/akinesia with ballooning and basal normokinesia. We report the case of a 45-year-old patient treated in our department for a TTS mimicking a heart attack.

Case presentation

A young adult aged 45, smoker and cannabis user, followed for 3 years for manic-depressive syndrome (on Olanzapine and Sodium Diproate) presented to the emergency room for chest pain. The pain was sudden in onset, evolving for 6 hours, it was constrictive retrosternal radiating towards the left upper limb. The clinical picture was established following intense stress, in this case, it was a romantic breakup.

He did not report any flu syndrome preceding the presentation, or any associated dyspnea. On examination, the patient was hemodynamically stable, blood pressure was 110/70 mmHg, heart rate was 92 beats per minute. He weighed 84 kg for a height of 180 cm. The heart sounds were regular without other added noises, the lungs were free. There were no signs of heart failure (HF). Biologically, troponins were 42,944 ng/mL (Normal <34 ng/mL), with a BNP level of 400. The infectious assessment and viral serologies, as well as the assessment of systemic diseases were negative.

The ECG realized in the cardiological emergency revealed a sinus rhythm at one hundred cycles per minute, with non-progressive ST segment elevation concave to septo-apico-lateral, absence of mirror image and pathological Q wave . The Smith formula equation for ST elevation is estimated to be 21.4 (<23.4) (Figure 1).

The coronary angiography was carried out in the emergency and found healthy coronary arteries. This allowed us to exclude an acute coronary syndrome due to coronary occlusion. Ventriculography confirmed the diagnosis by revealing apical ballooning associated with apical hypokinesia (figure 4). The international interTAK diagnostic score was estimated at 47%.

The patient was started on IC treatment. A psychiatric evaluation and psychological support were initiated in hospitalization. The evolution was favorable, marked by a rapid improvement of the pain, a clear resolution of the elevation on the third day without Q wave of necrosis with improvement of the LVEF to 55%, allowing a return home.

Three weeks after the event, the patient underwent cardiac magnetic resonance imaging showing good biventricular function, LVEF 60% and no sign of late enhancement after gadolinium injection.

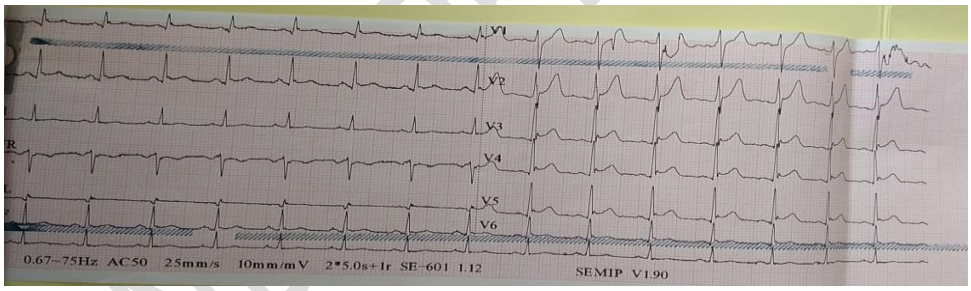

Figure 1: ECG on admission

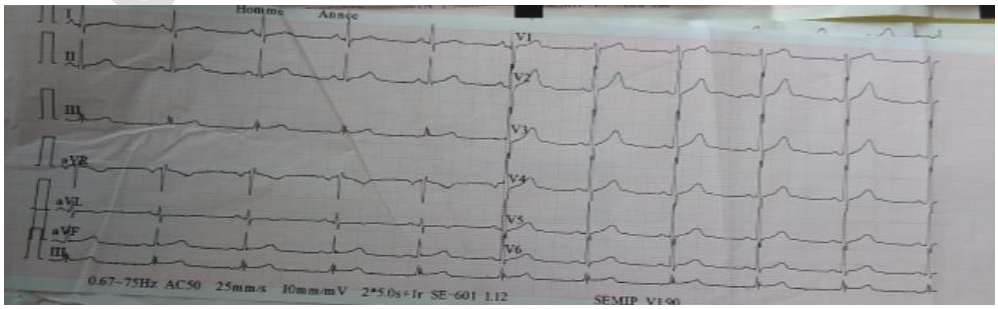

Figure 2: electrocardiogram on the third day of the event

UNDER PEER REVIEW

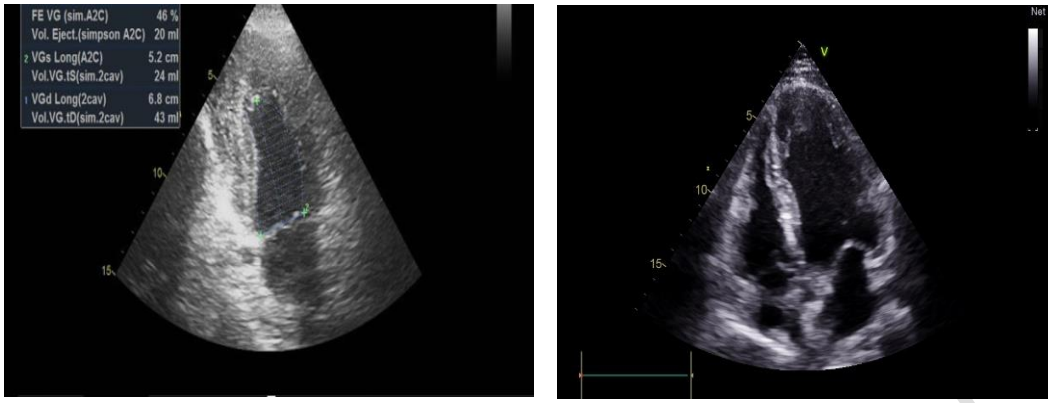

Figure 3: Left Ventricular Dysfunction

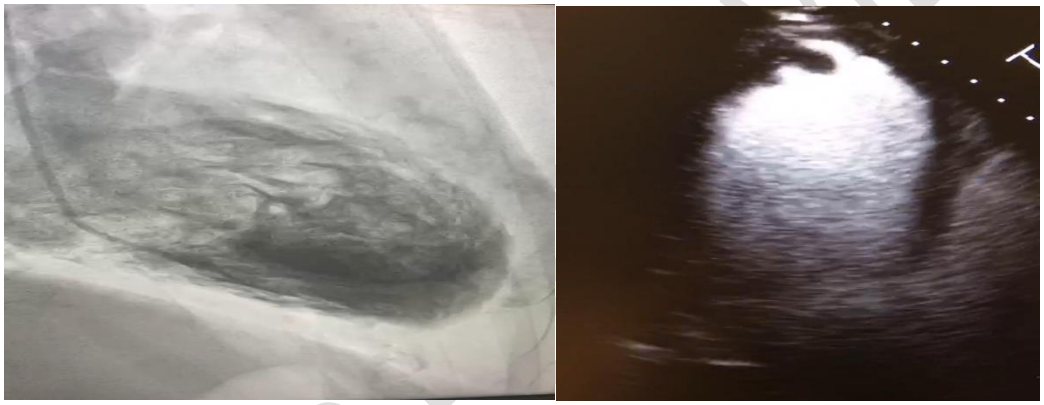

Figure 4: “Octopus trap” appearance

DISCUSSION:

Broken heart syndrome, also known as stress cardiomyopathy and tako-tsubo syndrome (TTS), was first described in the early 1990s. The exact pathophysiological mechanisms are still debated. Several hypotheses are invoked, the most plausible of which seems to be a sudden adrenergic discharge, linked to stress.

Coronary microvascular dysfunction has also been implicated. However, pericardial vasospasm at presentation, as well as with acetylcholine challenge, is well documented [3]. The mechanism by which catecholamines cause abnormalities in myocardial contractions is not currently clearly known.

The clear epidemiological preponderance of women after menopause suggests a hormonal influence in the genesis of Takotsubo syndrome [3,4]. Although data clearly showing a direct link between estrogen levels and the development of tako tsubo are lacking, several pathophysiological mechanisms are proposed. Thus, it is established that estrogens influence vasomotor tone by regulating endothelial production of nitric oxide. They can also alleviate catecholamine-related vasoconstriction. And finally, significant coronary damage does not contradict Tako Tsubo syndrome.

UNDER PEER REVIEW

Although it is relatively common among postmenopausal women, more and more men are affected by Taktsubo syndrome. However, the short and long term prognosis is less favorable in the male population compared to that of women. In our case, it was a young man being followed for a psychiatric illness with an emotional trigger. The clinical, electrical and echocardiographic evolution was spectacular, marked by a rapid return to normal from the third day. In many of the cases described in the literature [5], emotional triggers have a favorable short- and long-term prognosis compared to stress cardiomyopathy triggered by physical stress [5, 6]. Furthermore, a recent study carried out by Waddah et al… [7] on sex differences in stress-induced cardiomyopathy (Takotsubo) made it possible to identify female sex as an independent predictor of lower mortality.

This could make us understand that unlike women, the triggering factor in men would be physical stress in most cases, just as men are more exposed to developing ischemic coronary artery disease which is added to stress cardiomyopathy. . This is the case of a study carried out by Sameer et al who recorded concomitant coronary artery disease in tako-Tsubo patients with an incidence ranging from 10 to 29%[7].

The initial ECG during Tako Tsubo syndrome is abnormal in most cases. As in an ACS, the territory of ECG abnormalities corresponds to the affected myocardial segments. Most of the time, they are found in the antero-septo-apical position, thus mimicking an anterior infarction. Most often, the ECG shows ST segment elevation and/or negative T waves. Like an ACS, the ECG of a patient with Tako Tsubo syndrome evolves over time, most often with the resolution of ST segment elevation and the progressive appearance of T waves. negative and prolongation of the QT space, very rarely Q waves during the first days, then resolution of these abnormalities over the following weeks [6]. In this perspective, these electrical sequences largely match our case: supra-shift of the ST segment concave in septo-apical-lateral quickly resolving without other associated electrical anomalies.

In the face of coronary syndrome with ST segment elevation, coronary angiography must be performed quickly. The absence of coronary lesions associated with kinetic disturbances typical of ventriculography poses the diagnosis of stress cardiomyopathy. However, the presence of significant coronary artery disease no longer excludes the diagnosis of Tak-Tsubo [8]. In our case, the absence of coronary lesions allowed us to remove this ambiguity.

Four forms of Tako tsubo are described according to the myocardial distribution of kinetic disorders: the most frequent apical form most often giving the appearance of apical ballooning and rarely the forms with midventricular, basal or focal locations [7 8]. Our patient presented slight apical ballooning on ventriculography and transthoracic echocardiography revealed apical hypokinesis extending to the apical segments of the other walls.

Cardiac imaging by magnetic resonance is a central examination, making it possible not only to assess ventricular function with certainty but also to identify possible etiologies in the face of ventricular dysfunction and kinetic abnormalities with apparently healthy coronary arteries, however. its access to the acute phase is most often difficult. In our case, the rapid recovery of ventricular function and the absence of late enhancement after gadolinium injection were elements in favor of Tako Tsubo syndrome at this stage.

CONCLUSION:

UNDER PEER REVIEW

Many cases of stress cardiomyopathy have been reported in recent years. Women are most affected, but cases of men are increasingly being described. And this could help to further elucidate the pathophysiology of the disease which is not yet fully established. The case we presented highlights that the first differential diagnosis of an acute coronary syndrome would be Tako-tsubo syndrome. It also highlights that the emotional state could predispose to this type of illness and that the speed of progression would be linked to the mechanism of adaptation to stress of each patient.

REFERENCES:

1. Anais Luya Schmidt, François Macht ; Tako-Tsubo syndrome: myth or reality?; Rev Med Suisse 2009 ; 5 : 1184-94

2. Jelena-Rima Ghadri and al. International Expert Consensus Document on Takotsubo Syndrome (Part I): Clinical Characteristics, Diagnostic Criteria, and Pathophysiology, European Heart Journal, Volume 39, Issue 22, 7 June 2018, Pages 2032–2046

3. Sato H. Tako-Tsubo-like left ventricular dysfunction due to multivessel coronary spasm. In: K Kodama, K, Haze M Hori, eds. Clinical Aspect of Myocardial Injury : From Ischemia to Heart Failure. Tokyo: Kagakuhyoronsha

4. Deshmukh A, Kumar G, Pant S, Rihal C, Murugiah K, Mehta JL. Prevalence of Takotsubo cardiomyopathy in the United States. Am Heart J 2012;164: 66–71 e1

5. Ghizlane S, Hicham L, Fatima Z. Psychiatric and psychological evaluation of Tako Tsubo syndrome. Pan Afr Med 20178 ; 27 :70.

6. C Templin. et al. Clinical Features and Outcomes of Takotsubo (Stress) Cardiomyopathy. N Engl J Med 2015;373:929–938.

7. Waddah M. et al. Differences entre les sexes dans la cardiomyopathie induite par le stress (Takotsubo).CJC tome 5, numéro 2, p120-127.
8. Sato H. Tako-Tsubo-like left ventricular dysfunction due to multivessel coronary spasm. In: K Kodama, K, Haze M Hori, eds. Clinical Aspect of Myocardial Injury : From Ischemia to Heart Failure. Tokyo: Kagakuhyoronsha.

9. Sameer M et al. Takotsubo cardiomyopathy prevalence and associated factors in patients presenting with a clinical picture of acute myocardial infarction in Palestine.pubmed.ncbi.nlm.nih.gov/37578674.

UNDER PEER REVIEW