

## Fahr's Disease presenting with non febrile epileptic seizures: Case report and Systematic Literature Review

### **ABSTRACT**

Fahr's disease is a very rare condition characterized by abnormal, symmetrical, and bilateral deposits of calcifications in the basal ganglia without an identifiable cause. Fahr's disease must be differentiated from Fahr's syndrome, which is also a rare anatomic-clinical entity, characterized by the presence of intracerebral calcifications located in the basal ganglia, most often associated with phosphocalcic metabolism disorders, primarily hypoparathyroidism.

While Fahr's syndrome involves secondary intracerebral calcifications, Fahr's disease is primary or idiopathic with autosomal dominant or recessive inheritance. There are sporadic and familial forms.

The clinical presentations of Fahr's disease vary and can include confusion syndromes, cognitive disorders, cerebellar syndrome, abnormal movements, psychiatric syndrome, or epilepsy. Seizures are very rare clinical presentation of Fahr's disease. There are also asymptomatic forms.

We report the case of a 13-year-old boy with Fahr's disease revealed by a non-febrile epileptic seizure. The patient's brother has similar epileptic manifestations. The medical

history, clinical, biological and radiological findings were supportive of a familial form of Fahr's disease.

**Keywords:** symmetrically bilateral basal ganglia calcification, seizures, epilepsy, idiopathic basal ganglia calcifications

## INTRODUCTION

Fahr's disease, also known as idiopathic basal ganglia calcification (IBGC), was first described by Theodor Fahr in 1830. Fahr's syndrome, or secondary calcifications, is radiographically defined by the presence of striato-pallido-dentate, non-arteriosclerotic, bilateral, and symmetrical calcifications(1).

Epidemiologically, according to the Fahr's disease registry, the prevalence is 1/1,000,000 in the general population, with 67% of the studied population being symptomatic(2).

It is a rare condition with neuro-psychiatric or epileptic manifestation(4,19,20). The idiopathic form, or Fahr's disease, corresponds to sporadic or familial forms with autosomal dominant inheritance.

Genetically, mutations have recently been identified. Fahr's disease with a genetic component is referred to as *primary familial brain calcification*(2).

We report the case of a 13-year-old child who came to the pediatric emergency with a nonfebrile epileptic seizure associated with abnormal movements. The patient's biological and radiological assessments revealed Fahr's disease.

## **CASE REPORT**

A 13-year-old boy came to the pediatric emergency department with a tonic epileptic seizure and abnormal movements. In his medical history, there was no neonatal distress, no medication use, he had been wearing corrective lenses for 4 years, no history of dog bites, good psychomotor development, good school performance, and no history of head trauma. The child had been experiencing absence seizures for a year. The patient's brother is already being treated for epilepsy. There is also a history of first-degree consanguinity.

The complaint started with a sudden onset of abnormal movements and torticollis (twisted neck) with spontaneous regression. The progression was marked by the onset of generalized tonic seizures multiple times, more than 5 times, which prompted the family to seek emergency care.

On clinical examination, the patient was conscious, had a normal orientation to place and time, and had GCS of 15/15. Vital signs were in normal limit for his age, blood pressure 119/80, heart rate 80 bpm, respiratory rate 18 breaths per

minute, oxygen saturation 98% ,temperature 37.4°C and capillary blood glucose was 0.86 g/l, normal. The patient presented a generalized tonic seizure with opisthotonos posture and spasmodic torticollis lasting about 10 minutes with spontaneous resolution without deficit or postictal coma. Additionally, the mother reported previous epileptic seizures.

The brain CT scan showed a calcified appearance of the lenticular and dentate nuclei bilaterally and symmetrically. There were also right frontal subcortical calcifications without mass effect, no midline shift, and the cisterno-ventricular system had normal appearance and morphology (Fig.1). The brain MRI revealed signal abnormalities of the dentate nuclei of the cerebellum as well as the basal ganglia and thalami in T1 hyperintensity, indicative of calcifications. There were no other parenchymal signal abnormalities in the supratentorial and infratentorial regions or osseous signal abnormalities.

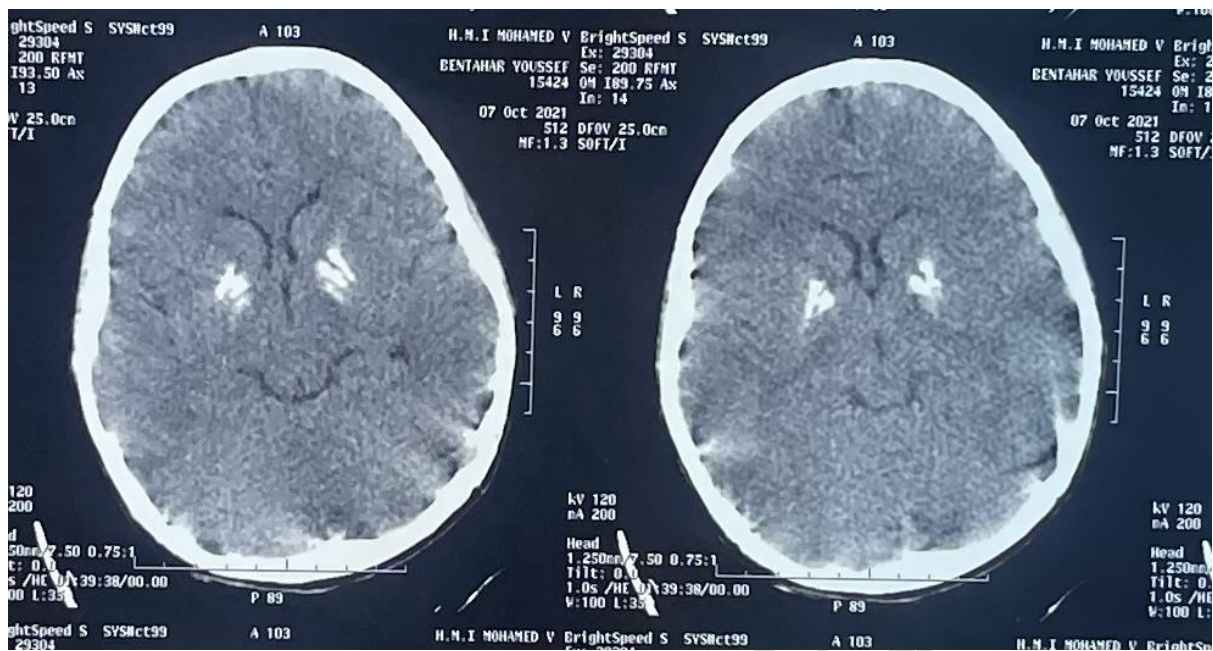
To distinguish between Fahr's disease and Fahr's syndrome required initial assessment for the most common etiologies of cerebral calcifications. The following diagnostic work up investigations were done to rule out all secondary causes of brain calcifications.

The laboratory investigations showed a normal blood count, C-reactive protein was negative, normal blood Urea and electrolytes with Sodium at 142 mmol/L and Potassium at 3.60 mmol/L. Urea 0.16 g/l , Creatinine 5mg/l and an estimated GFR using the CKD-EPI formula of 165 ml/min/1.73 m<sup>2</sup>. Phosphocalcic metabolism was normal with

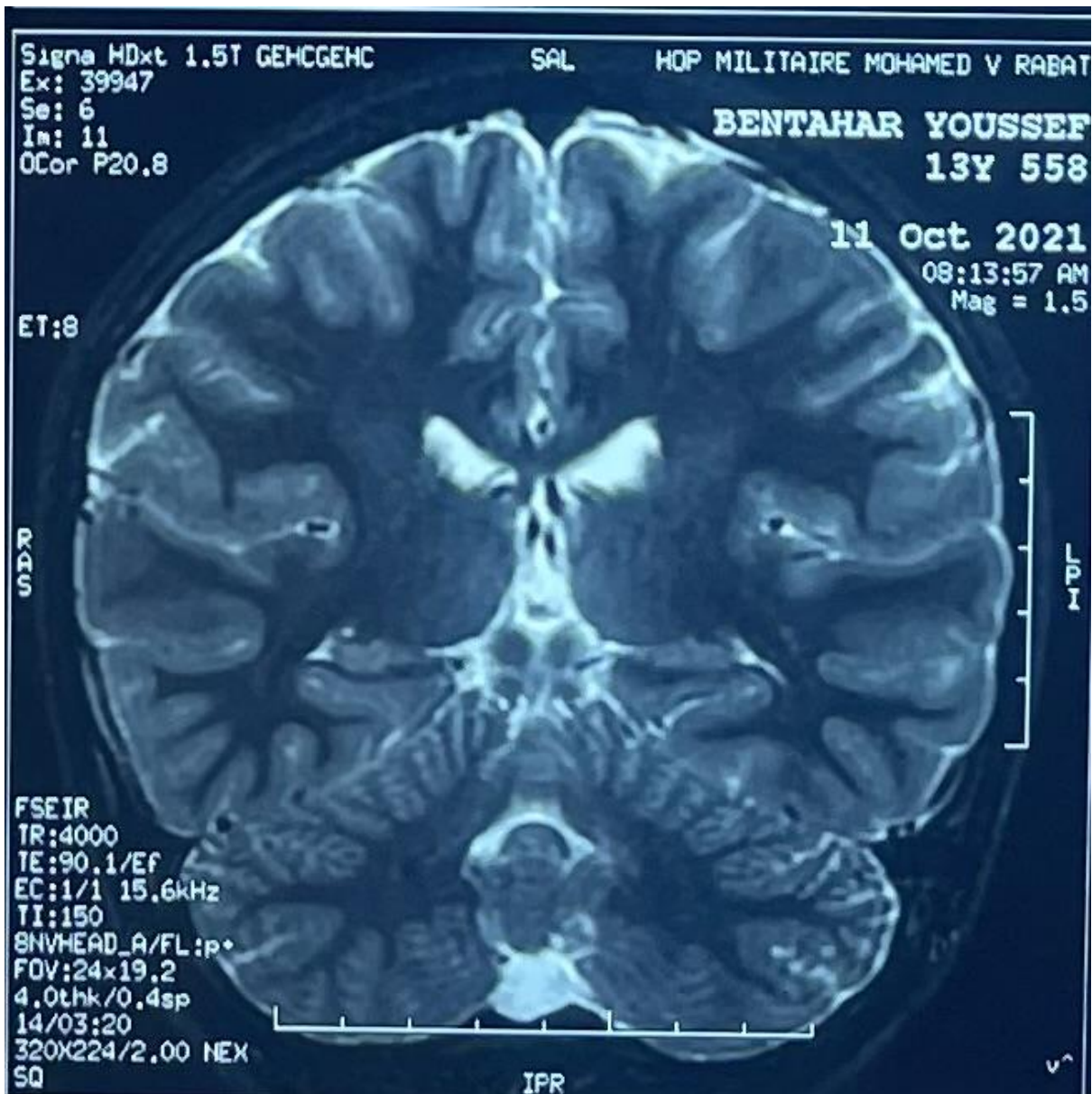
corrected total serum calcium at 2.957 mg/L, serum magnesium at 2.01 mg/dL, phosphorus at 48 mg/L, Vitamin D (25-OH D2-D3) at 35 ug/L, and PTH at 27 pg/mL. Liver function test was normal: ALP 222 UI/L, ALT 23 UI/L, AST 42 UI/L, GGT 16 UI/L. Thyroid function was normal: TSH 2.12  $\mu$ UI/mL, FT3 6.10 pmol/L, FT4 17.40 pmol/L, and cortisol (9:15 AM) 244 nmol/L. The immunological workup was negative (anti-DNA antibodies, anti-soluble nuclear antigens, anti-cytoplasm, antinuclear antibodies). The metabolic workup showed no abnormalities. Other radiological exams were unremarkable. An ultrasound of the neck showed no abnormalities, parathyroid glands were unremarkable, and a renal ultrasound was without anomalies. A standard X-ray of the upper and lower limbs showed no abnormalities, no soft tissue calcifications. Chest x ray and electrocardiography examination were normal. The ophthalmological examination revealed reduced visual acuity. The rest of the ophthalmological examination was unremarkable with a normal fundus examination.

The calcifications in the patient's imaging with normal calcium and phosphorus metabolism is a hallmark of Fahr's disease thus eliminating other causes of intracerebral calcifications.

The child was put on an antiepileptic treatment with levetiracetam. The evolution was marked by significant clinical improvement and the disappearance of abnormal movements. Routine clinical monitoring is done regularly to monitor the evolution of the disease.



**Figure.1** : A brain CT scan showing calcifications of the basal ganglia in our patient.



**Figure.2 :**  
A brain MRI showing calcifications of the dentate nuclei of the cerebellum, basal ganglia, and thalami.

## DISCUSSION

Idiopathic intracerebral calcification, or Fahr's disease, is characterized by bilateral and symmetrical calcium deposits in the basal ganglia and other regions of the cerebral cortex(4,9). It is a very rare neurodegenerative disease with a genetic component and autosomal dominant transmission, but there are also cases of autosomal recessive transmission(19). The disease was first described in 1830 by German neurologist Karl Theodor Fahr.

Epidemiologically, the incidence is 1/1,000,000 with fewer than 200 documented cases of Fahr's disease(6). Fahr's disease has a relative male predominance with a sex ratio of 2:1 and affects middle-aged patients with few cases reported among young individuals. Our patient presented the disease at a very young age, 13 years which is very interesting due to the rarity of the disease in younger populations.

It is important to distinguish Fahr's syndrome, which involves secondary intracerebral calcifications, from Fahr's disease, thereby the importance of a diagnostic criteria.

The diagnosis of Fahr's disease is made after excluding known causes of basal ganglia calcifications.

The diagnostic criteria for establishing the diagnosis are as follows(7):

1. Bilateral calcifications are found in the basal ganglia or other brain areas on brain imaging.
2. Progressive neurological deterioration with symptoms of motor decline and/or neuropsychiatric changes.

3.The disorder appears in the fourth or fifth decade of life but can begin in childhood.

4.There are no biochemical abnormalities or somatic characteristics suggesting mitochondrial or metabolic disorders or other systemic conditions.

5.No etiology of infection, poison, or trauma is found.

6.Autosomal dominant inheritance is supported by a family history of the disease.

7.In the absence of bilateral calcifications (criterion one) or progressive deterioration of neurologic and neuropsychiatric symptoms, the diagnosis is confirmed by a positive family history (criterion two).

There's another diagnostic criteria proposed by Saleem (8) et al and Perugula et al(9).

<b>Table 1. Consider the diagnosis of FS or FD in the presence of some or all of the following presentations:</b>		
Basal ganglia movement disorder (extrapyramidal). Cognitive disturbance. Cerebellar disorder. Pyramidal signs. Gait abnormalities. Speech dysfunction. Sensory changes. Psychiatric presentation.		
Considers the diagnosis of FD if:		Consider the
diagnosis of FS if:		
<b>Age</b>	40-60 years	30-40 years
<b>Associated</b>	Associated autosomal dominant or recessive pattern of inheritance	

Positive family history  
conditions

Any of the following endocrinopathies: idiopathic hypoparathyroidism, secondary hypoparathyroidism, pseudohypoparathyroidism, pseudopseudohypoparathyroidism, hyperparathyroidism and

One of the following conditions:

- Brucellosis (intrauterine/perinatal)
- Neuroferritinopathy
- Tuberous sclerosis
- Mitochondrial myopathy
- Lipoid proteinosis

**Pattern of calcification**

Coarse, progressive, symmetrical, and bilateral calcification of basal ganglia.

Symmetrical and bilateral intracranial calcification

**Management**

Symptomatically-directed treatment.

The treatment is aimed at the underlying pathology

Our patient meets the criteria for Fahr's disease after our laboratory, imaging and molecular investigations ruled out other causes of brain calcifications.

Histologically, calcium phosphate is the main component of the mineral deposits in the basal ganglia. The clinical expression of the disease is highly heterogeneous. It is asymptomatic in 30% of cases and symptomatic in 70%, with symptoms including cognitive disorders, psychiatric disorders, delirious episodes, seizures, dysarthria, abnormal movements (akineti-rigid syndrome, dystonia, or hyperkinetic movements, chorea, and dyskinesias). Cranial nerve involvement and benign intracranial hypertension are rare(8). Isolated headaches have been reported. Our patient presented seizures and abnormal movements.

The pathophysiological mechanism of the condition remains unknown. The brain CT scan is the radiological examination of choice(9). It reveals symmetrical calcifications of the putamen, globus pallidus, caudate nuclei, dentate nuclei of the cerebellum, or thalami. The white matter of the internal capsule, cerebellum, and cortical band are less commonly affected. Calcifications intensify with age. Our patient's symptoms aggravated with age as her mother reported episodes of seizures and absence epilepsy before the day he experienced the generalised tonic clonic seizures. The correlation between the extent of calcifications and clinical severity is assumed but not proven(10).

MRI shows magnetic susceptibility artifacts on T2-weighted gradient echo images(11).

Recently, four genes have been identified. The SLC20A2 gene (chromosome 8) encodes PiT2, an inorganic phosphate and sodium co-transporter(13). The mutation leads to loss of PiT2 function, resulting in the accumulation of inorganic phosphate and then calcium phosphate in the extracellular cerebral space, smooth muscle cells, and pericytes of the vessel walls. A second gene mutation, PDGFRB (chromosome 5), has been identified(14). It encodes PDGFR  $\beta$  (platelet-derived growth factor receptor  $\beta$ ). The receptor for this growth factor is present in vascular smooth muscle cells and pericytes. The mutation leads to disruption of the blood-brain barrier and calcification of brain microvessels. The PDGFB gene mutation (chromosome 22), which encodes PDGFB (platelet-derived growth factor B), was later discovered, leading to the same consequences(15). Finally, a mutation in a fourth gene, XPR1 (chromosome 1), has been identified(16). It acts as an exporter of inorganic phosphate.

In summary, primary brain calcifications could result from two pathophysiological pathways. The first is an alteration of phosphocalcic metabolism, and the second is an alteration of the blood-brain barrier. The severity of clinical expression is linked to the nature of the responsible gene, advanced onset age, and male sex. The cause of sporadic cases remains to be discovered, as well as factors promoting neurological and psychiatric signs(18).

The diagnosis of Fahr's disease is made after excluding the most common causes of brain calcifications, searching for a leukocyte mitochondrial DNA mutation, and performing a

muscle biopsy to look for a TREX1 mutation. TREX1 encodes a DNA polymerase and is involved in neuro-lupus.

The differential diagnosis of Fahr's disease is based on the search for a phosphocalcic metabolism disorder (hyper- or hypoparathyroidism, pseudohypoparathyroidism), mitochondrial disease (MELAS, MERRF), systemic disease (systemic lupus erythematosus, systemic sclerosis), metabolic disease (metachromatic leukodystrophy, hexosaminidase A and B deficiencies, Krabbe disease), infectious encephalitis, or calcified tumor. Fahr's disease presents as either sporadic cases or familial cases with autosomal dominant transmission with low clinical penetrance.

Our patient presented the typical criteria of Fahr's disease in the absence of phosphocalcic metabolism disturbance or other causes of calcification, with a family history suggesting idiopathic Fahr's disease.

The therapeutic management of Fahr's disease is symptomatic treatment. Antiepileptic treatment is implemented if necessary. Our patient received antiepileptic therapy for the seizures.

## **CONCLUSION**

Fahr's disease, or Idiopathic Basal Ganglia Calcification (IBGC), is a very rare disease. The diagnosis relies on a combination of clinical, biological, and radiological evidence.

Fahr's disease encompasses various undefined congenital or metabolic pathologies. The genetic form requires a genetic investigation to look for the presence of a familial form. Fahr's disease is characterized by bilateral abnormal brain calcifications, most commonly calcium deposits in the basal ganglia with a variety of heterogeneous clinical presentations. Our case report is interesting given the rarity of this disease, the young age of our patient which differs from previous literature which reported cases of patient of old age between the ages of 40-50 years. Clinical presentation by epileptic seizures in Fahr's disease is also rare hence the importance of reporting this case. Currently, there is no treatment to halt the progression of the disease.

#### Consent

As per international standards, parental written consent has been collected and preserved by the author(s).

#### Ethical Approval:

As per international standards or university standards written ethical approval has been collected and preserved by the author(s).

#### Disclaimer (Artificial intelligence)

##### Option 1:

Author(s) hereby declare that NO generative AI technologies such as Large Language Models (ChatGPT, COPILOT, etc) and text-to-image generators have been used during writing or editing of manuscripts.

##### Option 2:

Author(s) hereby declare that generative AI technologies such as Large Language Models, etc have been used during writing or editing of manuscripts. This explanation will include the name, version,

model, and source of the generative AI technology and as well as all input prompts provided to the generative AI technology

Details of the AI usage are given below:

1. we declare AI was not used to generate this article
- 2.
- 3.

## REFERENCES

1. Fahr TH. Idiopathische verkalkung der hirngefasse. Zentralbl Allg Pathol. 1930;50: 129-133. Google Scholar Şenoğlu M, Tuncel D, Orhan FÖ, Yuksel Z, Gokçe M. Fahr 's Syndrome : A Report of Two Cases. Firat Tip Derg. 2007;12(1):70–2.
2. Manyam BV, Walters AS, Narla KR. Bilateral striopallidodentate calcinosis: clinical characteristics of patients seen in a registry. Movement Disorders. 2001;16(2): 258-264. PubMed| Google Scholar
3. Malik R, Pandya V, Naik D. FAHR Disease – a rare neurodegenerative disorder. Movement Disorders. 2001;16(2): 258-264. Google Scholar Samuels CR, Khanni JL, Espinosa PS, Barkley K, Azhar M. Case Report: An Incidental Finding of Fahr's Disease in a Patient with Hypochondria. Cureus.2018;10(12):1–6..07.042
4. Hsu SC, Sears RL, Lemos RR, Quintáns B, Huang A, Spiteri E et al. Mutations in SLC20A2 are a major cause of familial

idiopathic basal ganglia calcification. Neurogenetics. 2013;14(1): 11-22. PubMed| Google Scholar

5. Lester J, Zuñiga C, Díaz S, Rugilo C, Micheli F. Diffuse Intracranial calcinosis: Fahr disease. Arch Neurol. 2006;63(12): 1806-180 PubMed Ongun N, Degirmenci E, Erdogan C. Fahr's syndrome presenting with epileptic seizure: Two case reports. North Clin Istanb. 2016;3(1): 71-74. PubMed

7. Samuels CR, Khanni JL, Espinosa PS, Barkley K, Azhar M. Case Report: An Incidental Finding of Fahr's Disease in a Patient with Hypochondria. Cureus. 2018;10(12):1-6

Rangaswamy null, Ranjith V, Vikas L, Santosh R. Fahr's Disease with seizure presentation. J Assoc Physicians India. 2016;64(8): 85-86. Google Scholar

8. Chouaib N, Rafai M, Belkouch A, Bakkali H, Belyamani L. Fortuitous discovery of Fahr's syndrome after seizures. Rev Neurol (Paris). 2015;171(12): 894-895. PubMed

Saleem S, Aslam HM, Anwar M, Anwar S, Saleem M, Saleem A, et al. Fahr's syndrome: Literature review of current evidence.

Orphanet J Rare Dis [Internet]. 2013;8(1):1. Available from: Orphanet Journal of Rare Diseases

9. Perugula ML, Lippmann S. Fahr's disease or Fahr's syndrome? Innov Clin Neurosci. 2016;13(7-8):45.

Harrington MG, Macpherson P, McIntosh WB, Allam BF, Bone I. The significance of the incidental finding of basal ganglia calcification on computed tomography. Journal of Neurology,

Neurosurgery & Psychiatry. 1981;44(12): 1168-1170.  
PubMed | Google Scholar Sinha R, Sodhi K, John BM, Singh D.  
Fahr's  
disease: A case report. J Nepal Paediatr Soc.2010;30(1):44–5.  
Ma A, Sm K, Salma U. Fahr's Syndrome: A rare  
Neurodegenerative Disorder.2017;29(01):39–41.

10. Loeb JA, Sohrab SA, Huq M, Fuerst DR. Brain calcifications induce neurological dysfunction that can be reversed by a bone drug. Journal of the Neurological Sciences. 2006;243(1-2): 77-81. PubMed | Google Scholar  
. Donzuso G, Mostile G, Nicoletti A, Zappia M. Basal ganglia calcifications (Fahr's syndrome): related conditions and clinical features. Neurol Sci. 2019;40(11):2251–63.  
. Durante A, Audino N, Cristiano M, Tanga M, Martino MT, Noschese I, et al. Basal ganglia calcification: a Fahr's disease case report. Radiol Case Reports [Internet]. 2021;16(10):3055–9. Available from: <https://doi.org/10.1016/j.radcr.2021>

11. López-Villegas D, Kulisevsky J, Deus J, Junqué C, Pujol J, Guardia E, Grau JM, (1996) Neuropsychological alterations in patients with computed tomography-detected basal ganglia calcification. Arch Neurol 53: 251–256  
Ayoub B, Chakib C, Khalil M, Hicham B.  
Article Case report Fahr ' s disease  
presenting with epileptic seizures : a case  
report. 2020;3(55):1–5.  
Manyam B V., Walters AS, Narla KR.

Bilateral Striopallidodentate calcinosis:  
Clinical characteristics of patients seen in a  
registry. *Mov Disord.* 2001;16(2):258–64.

12. Manyam BV, Moore WD, Devleschoward AB, Anderson DR, Calne DB, (1992) Bilateral striopallidodentate calcinosis: cerebrospinal fluid. Imaging and electrophysiological studies. *Ann Neurol* 31: 379–384

Gligorievski A. CT Diagnosis of Fahr disease, a case report. *Clin Case Reports Rev.* 2018;4(2):1–3.

13. Avrahami E, Cohn DF, Feibel M, Tadmor R, (1994) MRI demonstration and CT correlation of the brain in patients with idiopathic intracerebral calcification. *J Neurol* 241: 381–384

14. Wang C, Li Y, Shi L, Ren J, Patti M, Wang T, De Oliveira JR, Sobrido MJ, Quintans B, Baquero M, Cui X, Zhang XY, Wang L, Xu H, Wang J, Yao J, Dai X, Liu J, Zhang L, Ma H, Gao Y, Ma X, Feng S, Liu M, Wang QK, Forster IC, Zhang X, Liu JY, (2012) Mutations in SLC20A2 link familial idiopathic basal ganglia calcification with phosphate homeostasis. *Nat Genet* 44: 254–256

15. Nicolas G, Pottier C, Maltete D, Coutant S, Rovelet-Lecrux A, Legallic S, Rousseau S, Vaschalde Y, Guyant-Marechal L, Augustin J, Martinaud O, Defebvre L, Krystkowiak P, Pariente J, Clanet M, Labauge P, Ayrignac X, Lefaucheur R, Le Ber I, Frébourg T, Hannequin D, Campion D, (2013) Mutation of the PDGFRB gene as a cause of idiopathic basal ganglia

calcification. *Neurology* 80: 181–187 Asokan AG, D'souza A S, Jeganathan J, Pai S.

Fahr's syndrome- An interesting case presentation. *J Clin Diagnostic Res.* 2013;7(3):532–3.

16. Keller A, Westenberger A, Sobrido MJ, García-Murias M, Domingo A, Sears RL, Lemos RR, Ordoñez-Ugalde A, Nicolas G, da Cunha JE, Rushing EJ, Hugelshofer M, Wurnig MC, Kaech A, Reimann R, Lohmann K, Dobričić V, Carracedo A, Petrović I, Miyasaki JM, Abakumova I, Mäe MA, Raschperger E, Zatz M, Zschiedrich K, Klepper J, Spiteri E, Prieto JM, Navas I, Preuss M, Dering C, Janković M, Paucar M, Svenningsson P, Saliminejad K, Khorshid HR, Novaković I, Aguzzi A, Boss A, Le Ber I, Defer G, Hannequin D, Kostić VS, Champion D, Geschwind DH, Coppola G, Betsholtz C, Klein C, Oliveira JR, (2013) Mutations in the gene encoding PDGF $\beta$  cause brain calcifications in humans and mice. *Nat Genet* 45: 1077–1082

17. Legati A, Giovannini D, Nicolas G, Lopez-Sanchez U, Quintans B, Oliveira JR, sears RL, Ramos EM, Spiteri E, Sobrido MJ, Carracedo A, Castro-Fernandez C, Cubizolle S, Fogel BL, Goizet C, Jen JC, Kirdlarp S, Lang AE, Miedzybrodzka Z, Mitarnun W, Paucar M, Paulson H, Pariente J, Richard AC, Salins NS, Simpson SA, Striano P, Svenningsson P, Tison F, Unni VK, Vannaker O, Wessels MW, Wetchaphanphesat S, Yang M, Boller F, Champion D, Hannequin D, Sitbon M, Geschwind DH, Battini JL, Coppola G, (2015) Mutations in XPR1 cause primary familial brain calcification associated with altered phosphate export. *Nat Genet* 47: 579–581

18. Nicolas G, Pottier C, Charbonnier C, Guyant-Marechal L, Le Ber I, Pariente J, Labauge P, Ayrignac X, Defebvre L, Maltête D, Martinaud O, Lefaucheur R, Guillin O, Wallon D, Chaumette B,

Rondepierre P, Derache N, Fromager G, Schaeffer S, Krystkowiak P, Verny C, Jurici S, Sauvée M, Vérin M, Lebouvier T, Rouaud O, Thauvin-Robinet C, Rousseau S, Rovelet-Lecrux A, Frebourg T, Champion D, Hannequin D, (2013) Phenotypic spectrum of probable and genetically-confirmed idiopathic basal ganglia calcification. *Brain*; 136: 3395–3407

**19 Daidano, J. K., Makheja, H. K., Bhatia, M. R., Memon, W. R., Jamali, A. A., Tunio, S. A. P. and Ahmer, A. (2021) "Clinical Presentation of the Epileptic Patients at People Medical College Hospital, Nawabshah, Pakistan", *Journal of Pharmaceutical Research International*, 33(53A), pp. 267–273. doi: 10.9734/jpri/2021/v33i53A33659.**

**20 Batla A, Tai XY, Schottlaender L, Erro R, Balint B, Bhatia KP. Deconstructing Fahr's disease/syndrome of brain calcification in the era of new genes. *Parkinsonism & related disorders*. 2017 Apr 1;37:1-0.**