

Study of haematological and biochemical alterations in clinical cases of canine ehrlichiosis to understand the clinical picture of the disease

ABSTRACT

Aims: To study the effect of *Ehrlichia canis* infection on various haematological and biochemical parameters as compared to the normal healthy animals in order to understand the disease in dogs.

Study design: Dogs who comes to the veterinary hospital with symptoms of ehrlichiosis were included in the study. Haematological and biochemical parameters of dogs found positive for ehrlichiosis were analysed. The values of these parameters were subsequently compared to healthy animals in order to identify any significant difference caused by ehrlichiosis.

Place and Duration of Study: The studied was conducted at Department of Veterinary Medicine, Veterinary University Mathura, India. The investigation involved collecting samples from February 2023 to March 2024.

Methodology: 119 dogs infected with *Ehrlichia canis* were studied for changes in biochemical parameters like blood urea nitrogen, creatinine, alkaline phosphatase, alanine transaminase, aspartate amino transferase, total leucocyte count, total erythrocyte count, haemoglobin, haematocrit, erythrocyte indices (MCV, MCH, MCHC), differential leucocyte count, platelet count and platelet indices (MPV, PDW, PCT). Student's t-test in Graphpad Prism was used to compare these values to healthy animals.

Results: The study confirms that ehrlichiosis leads to significant haematological and biochemical changes in dogs. Infected dogs have lower Hb, TEC, and PCV than healthy animals, indicating anaemia. Thrombocytopenia and leukopenia were also observed in the infected animals. Non-significant differences in MCV, MCH, and MCHC between healthy and infected dogs indicate normocytic, normochromic anaemia. Anisocytosis is indicated by significant RDW-CV increases in infected dogs compared to healthy dogs. Increased liver-specific enzymes like ALT, AST, and ALP and kidney-related enzymes like BUN and CRT suggest hepatic and renal involvement in disease pathophysiology.

Conclusion: The results indicate that clinicians can use standard haematological and biochemical markers obtained upon admission of diseased animals to predict and assess the risk of ehrlichiosis. These findings can be utilized to improve the diagnosis and treatment of canine ehrlichiosis.

Keywords: *Ehrlichia canis*; Dog; Haematology; Biochemical study; RDW-CV; Mathura; India.

1. INTRODUCTION

Canine ehrlichiosis is an infectious tick borne disease of dogs caused by *Ehrlichia*, belonging to the family Ehrlichiaeae. *Ehrlichia* spp. is gram-negative bacteria that are intracellular pathogens and have a particular preference for hematopoietic cells. *E. canis* is responsible for tropical canine pancytopenia, which is characterized by a sudden decrease in many cellular components of the blood, most commonly known as pancytopenia and

thrombocytopenia [1]. In tropical and subtropical regions like India, ehrlichiosis is mainly caused by *E. canis* [2].

Ehrlichiosis was first reported in Algeria, North Africa in 1935 [3]. Its historical significance was recognised in the 1970s during the Vietnam War, when a significant number of military German shepherd dogs succumbed to the disease [4]. The geographical distribution of canine ehrlichiosis is determined by the presence of tick vectors, *Rhipicephalus sanguineus*, which is a worldwide carrier of *E. canis*. *R. sanguineus* is a widely distributed tick species that is commonly seen on dogs and is known to transmit infections to both dogs and humans [5,40,41,42].

The size of individual *Ehrlichia* organisms in the blood is approximately one μm , and they often have a coccoid or ellipsoid form. Within the canine body, these microorganisms are engulfed by phagosomes and undergo replication through binary fission, resulting in the formation of densely packed clusters of elementary bodies. The host cell rupture liberates the elementary entities, which then proceed to infect other cells [6]. The presence of infected cells in the bloodstream can lead to the development of vasculitis, the creation of blood clots, and ultimately result in pancytopenia and thrombocytopenia. Leukocytes and erythrocytes may get destroyed, results in clinical leukopenia and anaemia, respectively.

Ehrlichiosis is characterised by three distinct clinical phases: acute, subclinical, and chronic. The acute phase commences with symptoms such as elevated body temperature, discharge from the eyes and nose, lack of appetite, reduction in body weight, difficulty in breathing, and swelling of the lymph nodes. Thrombocytopenia, leukopenia, and anaemia may persist during the subclinical period. While during the chronic phase, depression, a gradual loss of body weight, pale appearance of the mucous membranes, pain in the abdomen region, bleeding, enlargement of lymph nodes, increased levels of globin in the blood, enlargement of the spleen, difficulty in breathing, enlargement of the liver, irregularities in the pulse, excessive urination, and excessive thirst are seen [7]. The prognosis of dogs with the chronic severe form of ehrlichiosis is grave [8]. Pronounced pancytopenia and reduced platelet concentration are most important risk factor for mortality in ehrlichiosis [9]. However, the symptoms of the disease are mostly non-specific similar to other common diseases of dogs such as hepatozoonosis, babesiosis and anaplasmosis.

The primary target organs of this bacterium include the bone marrow, spleen, and lymph nodes; however, it also impacts other internal organs such as the liver, kidney, and lungs [10]. Renal failure may be one of the severe irreparable complications in ehrlichiosis, therefore, needs early diagnosis. In veterinary clinical practice, serum urea and creatinine concentrations are widely used as endogenous markers for evaluating renal function in dogs [11]. Anemia is considered to be the most common and consistent haematological abnormality of dogs naturally or experimentally infected with *E. canis*.

Laboratory findings such as haematological and biochemical tests can add significant value in deciding the disease severity and necessity of treatment. The current study included cases that were confirmed using a species-specific PCR test for ehrlichiosis. The purpose was to assess changes in several haematological and biochemical parameters in order to establish a comprehensive clinical model of the disease in dogs.

2. MATERIAL AND METHODS

2.1 Topography of studied area

The studied area was comprised of portion of semi-arid zone of Northern India. The study was conducted at Mathura region of western Uttar Pradesh. The area is located at 27.4924°N latitude and 77.6737°E longitude axis, respectively. The area is considered to be

endemic for various tick borne diseases owing to the weather which consists of warm temperatures and high humidity favoring the abundance of tick population.

2.2 Screening of dogs for study

This study was conducted on a total 119 dogs with ehrlichiosis, which were presented to Teaching Veterinary Clinical Complex of Veterinary University DUVASU, Mathura, The investigation involved collecting samples from February 2023 to March 2024. Blood samples were obtained from the positive animals through the cephalic or saphenous vein for haematological and biochemical analysis. Approximately 2 ml of blood from each dog was collected in vacutainer tubes containing EDTA under aseptic situations. The blood for serum required for biochemical parameters were collected in a 5 ml capacity test tubes with no anticoagulant. The study included dogs of any age, sex, and breed that exhibited two to three classical signs of ehrlichiosis, such as mucosal pallor, high fever, vomiting, bleeding diathesis, mucosal petechiae and ecchymoses, hind limb or scrotal oedema, epistaxis, melena, nervous signs, ascites, weight loss, ocular abnormalities, or depression.

2.3 Haematological analysis

Hematological parameters like total leucocyte count (TLC), total erythrocyte count (TEC), hemoglobin (Hb), haematocrit (HCT), erythrocyte indices [mean corpuscular volume (MCV), mean corpuscular hemoglobin (MCH), mean corpuscular hemoglobin concentration (MCHC)] differential leucocyte count (Monocytes, Eosinophil, Neutrophil, Lymphocyte), platelet count (PLT), platelet indices [Mean Platelet Volume (MPV), Platelet Distribution Width (PDW), Platelet Count and Plateletcrit (PCT)], and red cell distribution width (RDW-CV and RDW-SD) were done by fully automated hematology analyzer (Ceiltac α , Nihon Kohden).

2.4 Biochemical analysis

Biochemical studies were carried out with the help of autochem ingeniiious analyzer (AKRAY Healthcare Pvt. Ltd.) using diagnostic kits (Span Diagnostics). Various biochemical parameters studied with the serum samples were blood urea nitrogen (BUN), creatinine (CRT), alkaline phosphatase (ALP), alanine transaminase (ALT), aspartate amino transferase (AST), total protein (TP), albumin (ALB). Globulin (GLB) was calculated by subtracting albumin from total protein.

2.5 Statistical Analysis

The values of various parameters were expressed as mean \pm S.E. and data were analyzed by independent samples two tailed t-test using Graphpad Prism software. Values of different haematological parameters in different groups were tested for normality as per Shapiro-Wilk normality test. The level of statistical significance for all comparisons was established at ($P = .05$).

3. RESULTS AND DISCUSSION

3.1 Haematological Analysis

Hematological profile of dogs found positive with *E. canis* infection is depicted in Table 1 and Fig. 1. All the values in different groups for the haematological parameters were passed for normality as per Shapiro-Wilk normality test without any significant difference. The mean values of TLC, TEC, Hb, HCT, PLT and PCT were significantly ($P < .05$) lower in affected dogs as compared to healthy control while the mean values of lymphocytes and RDW-CV

were significantly ($P < .05$) higher in affected dogs as compared to healthy control. The mean values of remaining parameters in affected dogs were non-significantly different from those of healthy control.

Table 1 Hematological parameters (mean±SE) of dogs infected with ehrlichiosis

Parameter	Dogs with Ehrlichiosis (n=119)	Healthy dogs (n=10)	P-value
TLC ($\times 10^3/\mu\text{L}$)	6.58±1.29	10.75±0.79	$P < .001$
TEC ($\times 10^6/\mu\text{l}$)	3.63±1.12	6.67±0.44	$P < .001$
Hb (gm/dl)	7.91±1.51	13.80±0.64	$P < .001$
HCT (%)	22.98±6.16	41.30±2.29	$P < .001$
MCV (fL)	63.83±3.52	64.15±1.75	ns
MCH (pg)	22.16±2.37	23.15±0.62	ns
MCHC (gm/dl)	34.26±1.52	34.48±0.44	ns
Monocytes (%)	6.78±1.59	6.17±0.40	ns
Eosinophil (%)	1.93±0.27	2.73±0.54	ns
Neutrophil (%)	54.90±6.09	68.65±0.40	ns
Lymphocyte (%)	36.10±10.15	18.35±1.34	$P < .001$
PLT ($10^5/\mu\text{L}$)	27.73±17.90	351.60±49.53	$P < .001$
PCT (%)	0.04±0.02	0.37±0.05	$P < .001$
MPV (fl)	6.87±0.33	6.79±0.24	ns
PDW (%)	16.54±1.67	18.35±1.34	ns
RDW-CV (%)	14.25±1.15	11.66±1.37	$P = .001$
RDW-SD (fl)	36.23±2.90	33.08±4.15	ns

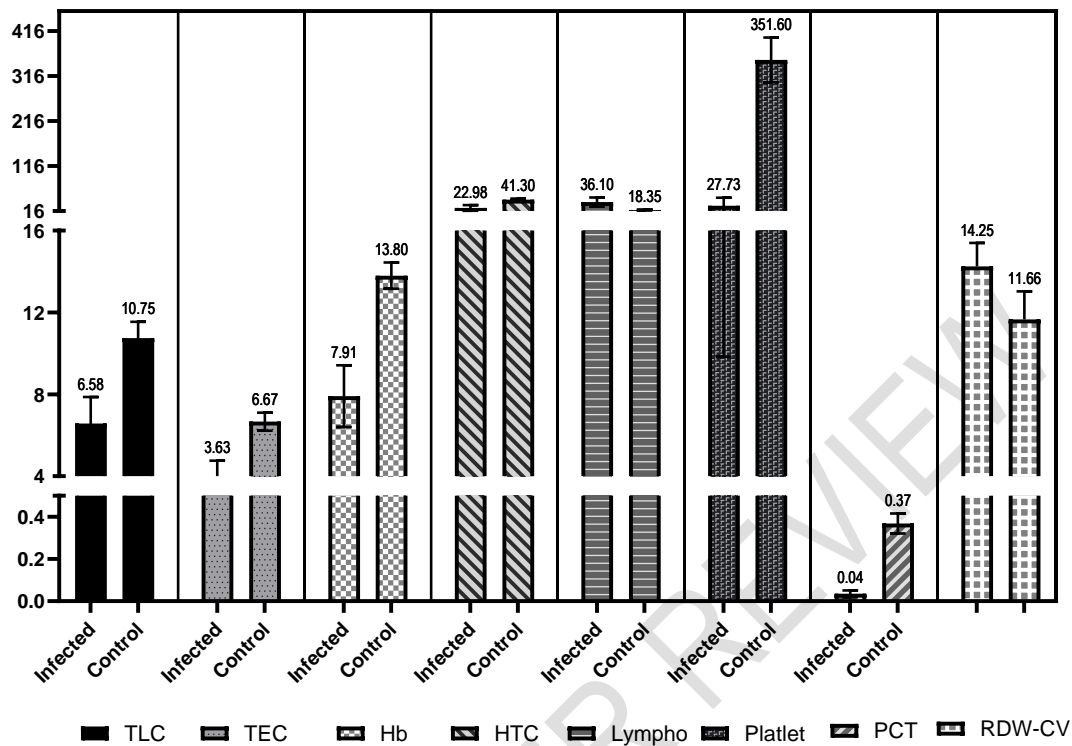


Fig.1 Level of significantly different haematological parameters in infected vs healthy animals

Results of the present study showing decreased TLC, TEC, Hb and HCT are consistent with other previous studies [12, 13, 14]. The anemia that occurs in dogs suffering from ehrlichiosis may be a sequel of bone marrow aplasia [15], severe haemorrhage caused by thrombocytopenia and platelet breakdown, immune-driven destruction of RBCs by means of the antibodies production and its subsequent binding to erythrocyte and platelet membranes, potentially destroying these cells [16]. *E. canis* infected erythrocytes initially opsonized by antibodies followed by phagocytosis which may be a contributing factor to anemia [17].

Additionally, in our study there was no significant difference observed in the MCV, MCH, or MCHC values in the infected animals compared to healthy animals. The current data, are consistent with the results of [18, 19, 20], which showed normocytic and normochromic anemia in dogs affected with ehrlichiosis. Similar outcomes showing negligible changes in the mean MCV and MCH values were also observed by other workers [12, 21, 22]. It has been suggested that the indices of RBCs quantify the size, shape, and physical properties of the RBCs. Anemia is a prevalent condition characterized by reduced numbers of erythrocytes, or an excess of malformed, poorly functioning RBCs. The various forms of anemia can be diagnosed using RBC indices and RBC counts. Thus, poor RBC indices may lead to anemia in the absence of changed MCV or MCH values. Low MCHC values indicate hypochromic conditions, which are defined as low comparative levels of Hb per unit volume of RBCs. MCH is the average amount of hemoglobin per RBC; therefore, reduced MCH values indicate a reduced Hb level, which in turn causes anemia without reducing the number of erythrocytes, leading to normocytic anemia. However, our findings showed a non-significant change in MCH values, yet the TEC reported a significant difference between the control and infected group.

Compared to microscopic findings of anisocytosis, which frequently result in misidentification, RDW is said to be more precisely predictive of anaemia [23]. MCV is the most often used metric for classifying anemia and determining the bone marrow response, along with RDW (24). However, for a change in MCV a large quantity of erythrocytes with altered volumes is required. Conversely, a slight alteration in the dimensions of these RBCs can alter the RDW [25], which can be utilized as potential marker for the diagnosis of anemia. RDW and MCV are invaluable parameters for categorizing anemia in canines [26, 27].

Our study revealed significantly higher RDW-CV values in infected groups as compared with control group with MCV values in the normal range. The results indicates normocytic non regenerative anaemia. Previous reports and literature also suggested the presence of normocytic, non-regenerative anaemia in ehrlichiosis (12, 19, 28). In the present study, blood samples were collected from the dogs that were presented to the veterinary clinical complex of the Veterinary University. The cases here are usually referred by the veterinary practitioners when they don't get success in the treatment as better diagnostics are available at this center. Due to this, most of the times chronically ill animals usually presented here. The presence of non-regenerative anaemia in the ehrlichiosis cases in the present study are in accordance to the previous study that suggests the similar condition in chronic ehrlichiosis (12, 29).

3.2 Biochemical Analysis

Values of different serum biochemical values of Ehrlichiosis positive dogs as compared to the healthy dogs are depicted in Table 2 and Fig. 2. All the values in different groups for the biochemical parameters were passed for normality as per Shapiro-Wilk normality test without any significant difference. There was found significant ($P < .001$) increase in mean values of ALT, AST, ALP and BUN in infected dogs than those of healthy control group. However, there was a significant ($P < .001$) decrease in Total protein and globulin concentration in the serum samples of infected dogs compared to the healthy animals. There was no significant difference found in the level of Albumin and Creatinine in infected dogs from those of healthy control.

Table 2 Serum biochemical parameters (mean±SE) of dogs infected with ehrlichiosis

Parameter	Dogs with Ehrlichiosis (n=119)	Healthy dogs (n=10)	P Value
Alanine transaminase (ALT) (IU/L)	86.59±1.13	25.03±1.06	$P < .001$
Aspartate transaminase (AST) (IU/L)	27.14±1.07	14.64±1.43	$P < .001$
Alkaline phosphatase (ALP) (IU/L)	221.73±1.98	34.60±1.43	$P < .001$
Total protein (TP) (gm/dl)	5.06±0.78	6.56±0.20	$P < .001$
Albumin (ALB) (gm/dl)	2.26±0.48	2.56±0.20	ns
Globulin (GLB) (gm/dl)	3.55±0.55	3.95±0.06	$P < .001$
Blood urea nitrogen (BUN) (mg/dl)	31.82±1.58	23.43±1.03	$P < .001$

Creatinine (CRT) (mg/dl)	0.87±0.37	0.63±0.06	ns
--------------------------	-----------	-----------	----

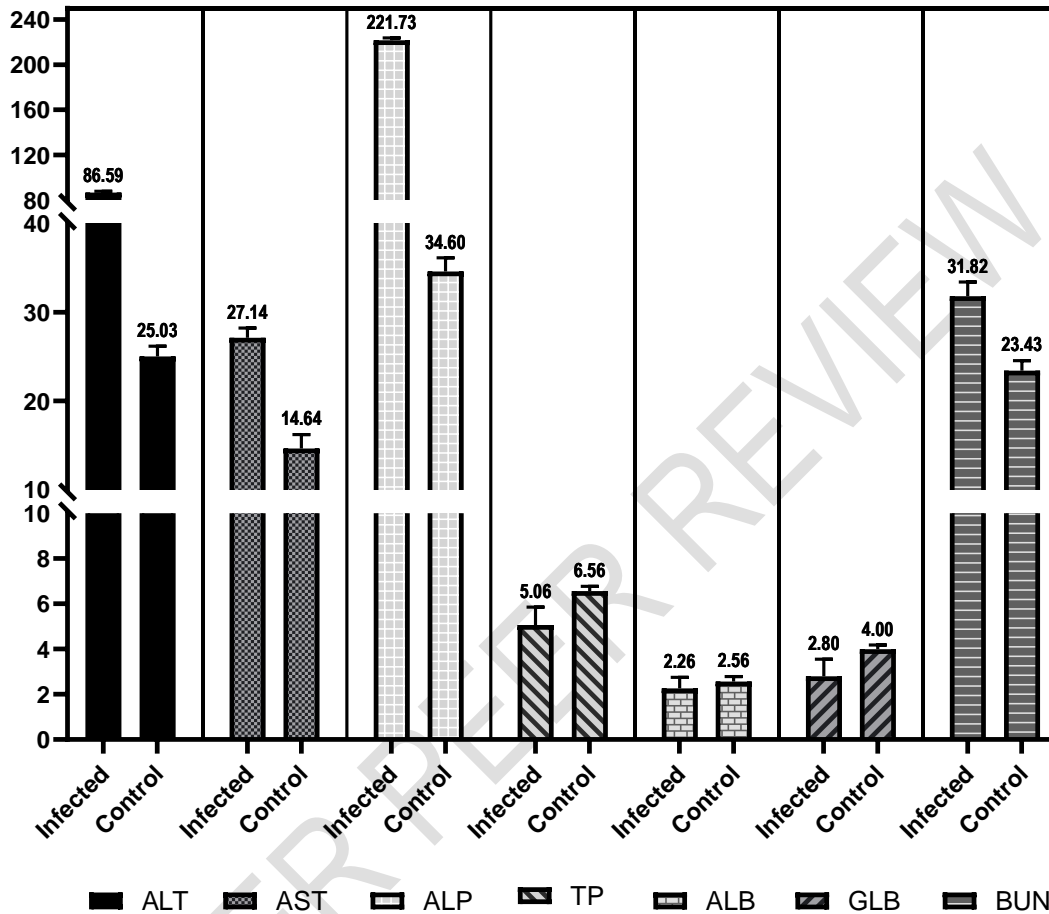


Fig.2 Level of significantly different biochemical parameters in infected vs healthy animals

The current findings of increased ALT in ehrlichiosis cases are consistent with earlier studies [30, 31, 32], while the findings of increased AST in dogs with ehrlichiosis are consistent with the outcomes of many earlier studies [32, 33, 34]. The current findings, which show a rise in ALP in ehrlichiosis instances, are consistent with those of previous studies [34, 35]. According to [36], ALT is an enzyme that is particular to the liver in dogs. It can rise in response to hepatic necrosis or mild reversible damage where hepatic cells get porous but fail to survive. In dogs with ehrlichiosis, elevated AST and ALP values are suggestive of liver disorders resulting in low protein levels [34, 37]. Despite obvious clinical symptoms, liver pathology linked to preclinical *E. canis* disease has been described as a channel migration of lymphocytes, plasma cells, and macrophages that causes a noticeable deformation of the adjacent acinar structure. Different experimental research reported severe steatosis, sinusoidal congestion, mild to moderate peri-vascular and periportal mononuclear cell infiltration, and centri-lobular fatty deterioration [38, 39].

The current investigation revealed that, when compared to the control, the total protein and globulin levels in the infected dogs, at the day of presentation were significantly lower. Our results were in line with the results of numerous earlier researches [32, 33]. A number of factors could be causing the hypoproteinemia in ehrlichiosis, including peripheral loss of protein to edematous inflammatory fluids due to increased vascular permeability [17], blood loss, and decreased protein production from concurrent liver disease, intralobular necrosis from bleeding, anemic hypoxia, or secondary bacterial sepsis [8].

The current study revealed a statistically significant rise in BUN in *Ehrlichia* positive animals, as compared to the control group. The results of numerous earlier studies are consistent with the current findings [34, 35,]. All renal disorders, such as prerenal azotemia, kidney azotemia, and post-renal azotemia cause a rise in BUN [38]. In a research study on Ehrlichiosis, glomerular and tubulo-interstitial alterations displaying mild to moderate lesions [39]. These pathological conditions may have contributed to the higher serum BUN concentration.

4. CONCLUSION

The findings suggest that ehrlichiosis has a significant impact on the blood and biochemical characteristics of infected dogs, with notable alterations in lymphocyte count, a decrease in RBC count, and a decrease in platelet count. An elevated RDW in infected dogs suggests the existence of anisocytosis. A lack of considerable variation in MCV, MCH, and MCHC suggests the presence of normocytic, normochromic anaemia. Whereas, abnormally high levels of ALT, AST, ALP, BUN, and creatinine indicate liver and kidney damage caused by the disease. Therefore, clinicians can utilize typical blood tests and chemical indicators collected while admitting sick animals to anticipate and evaluate the likelihood of ehrlichiosis. The results can be applied to enhance the identification and therapy of canine ehrlichiosis.

ETHICAL APPROVAL

The blood was collected from the diseased dogs and healthy control animals under the ethical standards and guidelines of the Institutional Animal Ethics Committee (IAEC) and due permission was received from the ethical committee of the University via. voucher no. IAEC/23-1/6 dated 25-10-2019.

Disclaimer (Artificial intelligence)

Option 1:

Author(s) hereby declare that NO generative AI technologies such as Large Language Models (ChatGPT, COPILOT, etc) and text-to-image generators have been used during writing or editing of manuscripts.

Option 2:

Author(s) hereby declare that generative AI technologies such as Large Language Models, etc have been used during writing or editing of manuscripts. This explanation will include the name, version, model, and source of the generative AI technology and as well as all input prompts provided to the generative AI technology

Details of the AI usage are given below:

- 1.
- 2.
- 3.

REFERENCES

1. Harrus S, Waner T, Bark H, Jongejan F, Cornelissen AW. Recent advances in determining the pathogenesis of canine monocytic ehrlichiosis. *J Clin Microbiol.* 1999;37(9):2745-9. doi: 10.1128/JCM.37.9.2745-2749.1999.
2. Ettinger SJ, Feldman EC. *Textbook of Veterinary internal medicine, Diseases of dogs and cats.* 6th ed. WB Saunders Company; 2005.
3. Kukreti K, Pandey L, Das M, Rastogi A, Dubey R, Sharma P. Prevalence of canine monocytic ehrlichiosis in canine population across India. *Archives of Razi Institute.* 2018;73(2):87-93.
4. Amyx HL, Huxsoll DL, Zeiler DC, Hildebrandt PK. Therapeutic and prophylactic value of tetracycline in dogs infected with the agent of tropical canine pancytopenia. *J Am Vet Med Assoc.* 1971;159(11):1428-32. PMID: 5170461.
5. Marshet B, Dessie D. A review on canine ehrlichiosis and its zoonotic implications. *Int J Vet Sci & Ani Hus.* 2020;5(3):36-42
6. Nicholson WL, Allen KE, MincQuiston JH. The increasing recognition of rickettsial pathogens in dogs and people. *Trends in Parasitology.* 2010;26:205-212.
7. Mylonakis ME, Harrus S, Breitschwerdt EB. An update on the treatment of canine monocytic ehrlichiosis (*Ehrlichia canis*). *The vet journal.* 2019;246:45-53.
8. Harrus S, Waner T, Bark H. Canine monocytic ehrlichiosis—an update. *Comp Cont Ed Prac Vet.* 1997;19:431–444..
9. Shipov A, Klement E, Reuveni-Tager L, Waner T, Harrus S. Prognostic indicators for canine monocytic ehrlichiosis. *Vet Parasitol.* 2008;153(1- 2):131-138.
10. Jacobson LS, Clark I. The pathophysiology of canine babesiosis: new approaches to an old puzzle. *J S Afr Vet Assoc.* 1994;65(3):134-45.
11. Miyagawa Y, Takemura N, Hirose H. Evaluation of the measurement of serum cystatin C by an enzyme-linked immunosorbent assay for humans as a marker of the glomerular filtration rate in dogs. *J Vet Med Sci.* 2009;71(9):1169-76. doi: 10.1292/jvms.71.1169. PMID: 19801896.
12. Aziz MU, Hussain S, Song B, Ghauri HN, Zeb J, Sparagano OA. Ehrlichiosis in Dogs: A Comprehensive Review about the Pathogen and Its Vectors with Emphasis on South and East Asian Countries. *Vet Sci.* 2022;10(1):21. doi: 10.3390/vetsci10010021. PMID: 36669021; PMCID: PMC9863373.
13. Piso DYT, Barreto MYP, Bonilla MDPS, Andrade ALD. Relationship between ocular abnormalities and hematologic alterations in patients infected naturally by *Ehrlichia canis*. 2021; *Ciência Rural*, 51.
14. Singh J, Singh RS, Singh H, Gupta DK, Randhawa SS. Clinical and haemato-biochemical observations in dogs naturally infected with canine monocytic ehrlichiosis. *Explor Anim Med Res.* 2021 Dec 1;11(2).
15. Weiss DJ. Bone marrow necrosis in dogs: 34 cases (1996–2004). *J Am Vet Med Assoc.* 2005;227(2):263-267.
16. Taylor MA, Coop RL, Wall RL. *Veterinary parasitology, Parasites of dogs and cats.* 3rd ed. Blackwell Publishing, Oxford; 2007.
17. Woody BJ, Hoskins JD. Ehrlichial diseases of dogs. *Veterinary Clinics of North America: Small Animal Practice.* 1991;21(1):75-98.
18. Sukara R, Andrić N, Andrić JF, Mihaljica D, Veinović G, Ranković V et al. Autochthonous infection with *Ehrlichia Canis* and *Hepatozoon Canis* in dogs from Serbia. *Vet Med Sci.* 2023;9(1):111-118. doi: 10.1002/vms3.1061. Epub 2022 Dec 29. PMID: 36580396; PMCID: PMC9857103.

19. Sainz Á, Roura X, Miró G, Estrada-Peña A, Kohn B, Harrus S, Solano-Gallego L. Guideline for veterinary practitioners on canine ehrlichiosis and anaplasmosis in Europe. *Parasites Vectors*. 2015;8:1-20.
20. Hnilica KA. *Small Animal Dermatology- Viral, Rickettsial, and Protozoal Skin Diseases*. 3rd ed. W.B. Saunders, 2011.
21. Varshney JP. Clinical management of recurrent pyrexia in dogs associated with a concurrent infection of *Ehrlichia canis* and *Hepatozoon canis*. *Vet Pract*. 2022;23(1):41-44
22. Moonarmart W, Sungpradit S, Rawangchue T, Suphaphiphat K, Suksusieng S, Jirapattarasate C. Clinical history and hematological findings among canines with monocytic ehrlichiosis. *Southeast Asian J Trop Med Public Health*. 2014;45(1):157-66. PMID: 24964665.
23. Žvorc Z, Rafaj RB, Kuleš J, Mrljak V. Erythrocyte and platelet indices in babesiosis of dogs. *Vet Arhiv*. 2010;80:259-267.
24. Neiger R, Hadley J, Pfeiffer DU. Differentiation of dogs with regenerative and non-regenerative anaemia on the basis of their red cell distribution width and mean corpuscular volume. *Vet Rec*. 2002 Apr 6;150(14):431-4. doi: 10.1136/vr.150.14.431. PMID: 11993971.
25. Martinez C, Mooney CT, Shiel RE, Tang PK, Mooney L, O'Neill EJ. Evaluation of red blood cell distribution width in dogs with various illnesses. *Can Vet J*. 2019 Sep;60(9):964-971. PMID: 31523082; PMCID: PMC6697020.
26. de Souza AM, de Jesus Pereira J, Campos SD, Bacellar DT, de Almeida Torres Filho R, de Barros Macieira D et al. Behavior of red cell distribution width (RDW) in a population of anemic and non-anemic dogs from an ambulatory care unit. *Rev Bras de Ciên Vet*. 2017;24(1).
27. Yadav J, Bihani DK, Chahar A, Kashyap SK, Choudhary. Haematobiochemical and therapeutic evaluation of canine ehrlichiosis. *Vet Pract*. 2017;18(2):237-240.
28. Willard MD, Tvedten H. *Small Animal Clinical Diagnosis by Laboratory Methods- Erythrocyte Disorders*. 4th ed. WB Saunders Company; 2004.
29. Gould DJ, Murphy K, Rudorf H, Crispin SM. Canine monocytic ehrlichiosis presenting as acute blindness 36 months after importation into the UK. *J Small Anim Pract*. 2000;41(6):263-5. doi: 10.1111/j.1748-5827.2000.tb03937.x. PMID: 10879405.
30. Kottadamane MR, Dhaliwal PS, Singla LD, Bansal BK, Uppal SK. Clinical and hematobiochemical response in canine monocytic ehrlichiosis seropositive dogs of Punjab *Vet World*. 2017;10(2):255-261.
31. Agnihotri D, Khurana R, Jain VK, Singh G. Concurrent infection of *Ehrlichia canis* and *Ancylostomosis* in a dog. *Ind Vet J*. 2012;89(11):89-90.
32. Mann S, Uppal SK, Hussain SA, Singla LD. Diagnosis and management of *Ehrlichia canis* associated chronic kidney disease (CKD) in three Labrador dogs. *SKUAST. J Res* 2017;19(1):160-163.
33. Solter PF, Hoffman WE, Chambers MD, Schaeffer DJ, Kakuhlenschmidt MS. Hepatic total 3-alpha-hydroxy bile acids concentration and enzyme activities in prednisone treated dogs. *Am J Vet Res*. 1994;55(8):1086-1092.
34. Premila A. Oxidative stress in paracetamol induced pathogenesis: (I) Renal damage. *Ind J Biochem Biophys*. 2005;42:59-62.
35. de Castro MB, Machado RZ, De Aquino LPCT, Alessi AC, Costa MT. Experimental acute canine monocytic ehrlichiosis: clinicopathological and immunopathological findings. *Vet Parasitol*. 2004;119(1):73-86.
36. Reardon MJ, Pierce KR. Acute experimental canine ehrlichiosis. II. Sequential reaction of the hemic and lymphoreticular system of selectively immunosuppressed dogs. *Vet Pathol*. 1981;18(3):384-95. doi: 10.1177/030098588101800311. PMID: 7257081.

37. Varela F, Font X, Valladares JE, Alberola J. Thrombocytopathia and light-chain proteinuria in a dog naturally infected with Ehrlichia canis. J Vet Int Med. 1997;11(5):309-311.
38. Lorsirigool A, Pumipuntu N. A retrospective study of dogs infected with Ehrlichia canis from 2017-2019 in the Thonburi area of Bangkok province, Thailand. Int J Vet Sci. 2020;9(4):578-580
39. Niwetpathomwat A, Techangamsuwan S, Suvamavibhaja S. A retrospective study of the clinical hematology and biochemistry of canine ehrlichiosis in an animal hospital population in Bangkok, Thailand. J Clin Pathol. 2005;14:217-220.
40. Awooda, Mona F. Alshiekh, Maaly Z. M. Abdalla, El Ayis A. Abubaker, and Wael I. Mursal. 2023. "Serological Investigation of Canine Ehrlichiosis in Khartoum State, Sudan". Asian Journal of Research in Animal and Veterinary Sciences 6 (2):158-66. <https://doi.org/10.9734/ajravs/2023/v6i2242>.
41. Harrus S, Waner T. Diagnosis of canine monocytotropic ehrlichiosis (Ehrlichia canis): an overview. The Veterinary Journal. 2011 Mar 1;187(3):292-6.
42. Harrus S, Waner T. Diagnosis of canine monocytotropic ehrlichiosis (Ehrlichia canis): an overview. The Veterinary Journal. 2011 Mar 1;187(3):292-6.