

Abnormal Coronary-Bronchial Fistula: The Role of Coronary CT Angiography

ABSTRACT :

Coronary-bronchial fistulas (CBFs) are rare vascular anomalies that involve abnormal connections between the coronary arteries and the bronchial tree. These anomalies can be challenging to diagnose due to their atypical presentation and the complexity of distinguishing them from other cardiovascular conditions. This case report illustrates the crucial role of advanced imaging techniques, particularly coronary CT angiography (CTA), in accurately diagnosing a CBF in a patient presenting with acute chest pain and elevated troponins. A 48 years old man with significant smoking history but no other cardiovascular risk factors presented to the emergency department with acute chest pain and shortness of breath. His initial clinical evaluation revealed elevated troponin levels, indicating myocardial injury. Given the patient's presentation and biomarkers, an urgent coronary angiography was performed to assess for possible coronary artery disease. The angiography revealed an unusual vascular structure, raising suspicion of a coronary-bronchial fistula (CBF). To obtain a more precise anatomical understanding, a coronary CT angiography (CTA) was subsequently performed. The CTA provided detailed three-dimensional images, clearly delineating the abnormal fistulous connection between the coronary arteries and the bronchial tree. The high-resolution images allowed for a comprehensive assessment of the fistula's size, course, and its relationship with surrounding structures, confirming the diagnosis of a CBF. Our case highlights the essential role of coronary CTA in diagnosing coronary-bronchial fistulas, particularly in patients presenting with atypical symptoms and inconclusive initial imaging findings. The integration of advanced imaging techniques, such as CTA, into the diagnostic workflow significantly enhances the ability to identify and characterize rare vascular anomalies.

Keywords: Coronary-bronchial fistula, coronary CT angiography, chest pain, troponins, vascular anomalies, diagnostic imaging.

Introduction :

Coronary-bronchial fistulas (CBFs) are rare vascular anomalies that involve abnormal connections between the coronary arteries and the bronchial tree. These anomalies can be challenging to diagnose due to their atypical presentation and the complexity of distinguishing them from other cardiovascular conditions. This case report illustrates the crucial role of advanced imaging techniques, particularly coronary CT angiography (CTA), in accurately diagnosing a CBF in a patient presenting with acute chest pain and elevated troponins.

CASE PRESENTATION:

A middle-aged man 48 years old of age with smoking history and no other significant cardiovascular risk factors presented to the emergency department with acute chest pain and shortness of breath. His initial clinical evaluation revealed elevated troponin levels, indicating myocardial injury. Given the patient's presentation and biomarkers, an urgent coronary angiography was performed to assess for possible coronary artery disease. The angiography revealed an unusual vascular structure, raising suspicion of a coronary-bronchial fistula (CBF).

Initial Clinical Evaluation:

Upon arrival, the patient's vital signs were as follows: blood pressure of 130/85 mmHg, heart rate of 95 beats per minute, respiratory rate of 20 breaths per minute, and oxygen saturation of 98% on room air. Physical examination was unremarkable, with no signs of heart failure, murmurs, or respiratory distress.

Laboratory tests revealed elevated troponin I levels at 2.5 ng/mL (normal <0.04 ng/mL), indicating myocardial injury. Electrocardiogram (ECG) showed non-specific ST-segment changes without clear evidence of acute myocardial infarction.

Initial Imaging:

A chest X-ray was performed, which showed no acute pulmonary pathology. Given the patient's presentation and elevated troponin levels, an urgent coronary angiography was performed to assess for possible coronary artery disease.

Coronary Angiography Findings:

Coronary angiography revealed patent coronary arteries without significant atherosclerotic disease. However, an unusual vascular structure was noted, raising suspicion of an abnormal communication between the coronary arteries and the bronchial tree, suggestive of a coronary-bronchial fistula (CBF). The angiographic images were inconclusive in defining the exact anatomy and extent of the fistula.

Advanced Imaging with Coronary CT Angiography (CTA):

To obtain a precise anatomical understanding, a coronary CT angiography (CTA) was performed. The CTA provided three-dimensional images, clearly delineating the abnormal fistulous connection between the coronary arteries and the bronchial tree. The images allowed a comprehensive assessment of the fistula's size, course, and its relationship with surrounding structures, confirming the diagnosis of a CBF. The fistula (blue arrow) was observed originating from the inferior part of the aortic arch, as seen in the sagittal view, descending to the midsection of the left anterior descending artery (LAD), creating an arterial confluence (red star) near the left atrial appendage Figures (1 to 3).

Management and Follow-Up:

Given the patient's stable condition and lack of severe symptoms, conservative management was chosen with close follow-up. The patient was educated about the nature of the fistula and advised to report any recurrence of symptoms immediately. Further follow-up appointments are scheduled, including future CCTA to monitor the fistula.

DISCUSSION

Coronary-bronchial fistulas (CBFs) are rare vascular anomalies characterized by abnormal communications between the coronary arteries and the bronchial tree. Although often asymptomatic, CBFs can present with a range of clinical symptoms, including chest pain, dyspnea, and recurrent respiratory infections due to abnormal blood flow between the coronary and bronchial circulations. Accurate imaging is crucial for diagnosing and managing CBFs to delineate the anatomy and plan appropriate interventions [1, 2] .

The advent of coronary CT angiography (CTA) has significantly enhanced the detection and characterization of coronary artery anomalies, including CBFs. Coronary CTA is a non-invasive imaging modality that provides high-resolution, three-dimensional images of the coronary arteries and surrounding structures. This technique offers several advantages over conventional invasive coronary angiography, such as visualizing the coronary artery lumen and wall, detecting extraluminal pathology, and assessing the anatomical relationships of the coronary arteries with adjacent structures [3, 4] .

In the present case, coronary CTA was instrumental in identifying the presence of an abnormal CBF. The detailed images obtained allowed for precise localization and characterization of the fistula, which was crucial for determining the appropriate management strategy. The use of coronary CTA in this context aligns with current guidelines and literature, supporting its role as a first-line imaging modality for evaluating suspected coronary anomalies [5, 6] .

Several studies have highlighted the efficacy of coronary CTA in diagnosing coronary artery anomalies. For example, studies have demonstrated that coronary CTA has a high diagnostic accuracy for detecting congenital coronary anomalies, comparable to invasive coronary angiography [7, 8] . Additionally, dual-source coronary CTA has been reported to effectively identify coronary artery anomalies, providing detailed anatomical information essential for clinical decision-making.

While coronary CTA offers numerous benefits, it is essential to consider its limitations. The modality involves exposure to ionizing radiation, which poses a risk, particularly in younger patients or those requiring multiple imaging studies. Additionally, the quality of coronary CTA images can be affected by factors such as patient movement, heart rate, and the presence of calcifications, which may obscure the visualization of coronary arteries [9,10] .

Management of CBFs varies depending on the patient's symptoms, the size and anatomy of the fistula, and the presence of associated cardiac or respiratory conditions. In asymptomatic patients with small, hemodynamically insignificant fistulas, conservative management with regular follow-up may be appropriate. In contrast, symptomatic patients or those with large fistulas may require interventional procedures, such as percutaneous embolization or surgical correction, to prevent complications such as myocardial ischemia, heart failure, or recurrent respiratory infections [10] .

Conclusion : coronary CTA is a valuable tool in the diagnosis and evaluation of coronary-bronchial fistulas. Its ability to provide detailed, non-invasive imaging of the coronary arteries and adjacent structures makes it an essential modality in the management of these rare vascular anomalies. This case underscores the importance of coronary CTA in identifying

and characterizing CBFs, thereby facilitating appropriate clinical management and improving patient outcomes. Further research and advancements in imaging technology will continue to enhance our understanding and management of coronary artery anomalies, including CBFs [1, 6] .

REFERENCES

1. Sundaram B, Kreml R, Patel S. Imaging of coronary artery anomalies. *Radiol Clin North Am.* 2010;48(4):711-727.
2. Fujimoto S, Kondo T, Orihara T, et al. Prevalence of anomalous origin of coronary artery detected by multi-detector computed tomography at one center. *J Cardiol.* 2011;57(1):69-76.
3. De Jonge GJ, van Ooijen PM, Piers LH, et al. Visualization of anomalous coronary arteries on dual-source computed tomography. *Eur Radiol.* 2008;18(12):2425-2432.
4. Narula J, Chandrashekhar Y, Ahmadi A, et al. SCCT 2021 Expert Consensus Document on Coronary Computed Tomographic Angiography: A Report of the Society of Cardiovascular Computed Tomography. *J Cardiovasc Comput Tomogr.* 2021 May-Jun;15(3):192-217. doi: 10.1016/j.jcct.2020.11.001. Epub 2020 Nov 20. PMID: 33303384; PMCID: PMC8713482.
5. Yamanaka O, Hobbs RE. Coronary artery anomalies in 126,595 patients undergoing coronary arteriography. *Cathet Cardiovasc Diagn.* 1990 Sep;21(1):28-40. doi: 10.1002/ccd.1810210110. PMID: 2208265.
6. Pandey NN, Sinha M, Sharma A, Rajagopal R, Bhambri K, Kumar S. Anomalies of coronary artery origin: Evaluation on multidetector CT angiography. *Clin Imaging.* 2019 Sep-Oct;57:87-98. doi: 10.1016/j.clinimag.2019.05.010. Epub 2019 May 23. PMID: 31170598.
7. Malagò R, Pezzato A, Barbiani C, Alfonsi U, Nicolì L, Caliarì G, Pozzi Mucelli R. Coronary artery anatomy and variants. *Pediatr Radiol.* 2011 Dec;41(12):1505-15. doi: 10.1007/s00247-011-2218-9. Epub 2011 Nov 30. PMID: 22127682.
8. Byun SS, Park JH, Kim JH, Sung YM, Kim YK, Kim EY, Park EA. Coronary CT findings of coronary to bronchial arterial communication in chronic pulmonary disease. *Int J Cardiovasc Imaging.* 2015 Jun;31 Suppl 1:69-75. doi: 10.1007/s10554-015-0647-5. Epub 2015 Mar 24. PMID: 25802014.
9. Zenooz NA, Habibi R, Mammen L, Finn JP, Gilkeson RC. Coronary artery fistulas: CT findings. *Radiographics.* 2009 May-Jun;29(3):781-9. doi: 10.1148/rg.293085120. PMID: 19448115.
10. Lim JJ, Jung JI, Lee BY, Lee HG. Prevalence and types of coronary artery fistulas detected with coronary CT angiography. *AJR Am J Roentgenol.* 2014 Sep;203(3):W237-43. doi: 10.2214/AJR.13.11613. PMID: 25148179.

Commented [MF1]: Add Doi at the end of these references

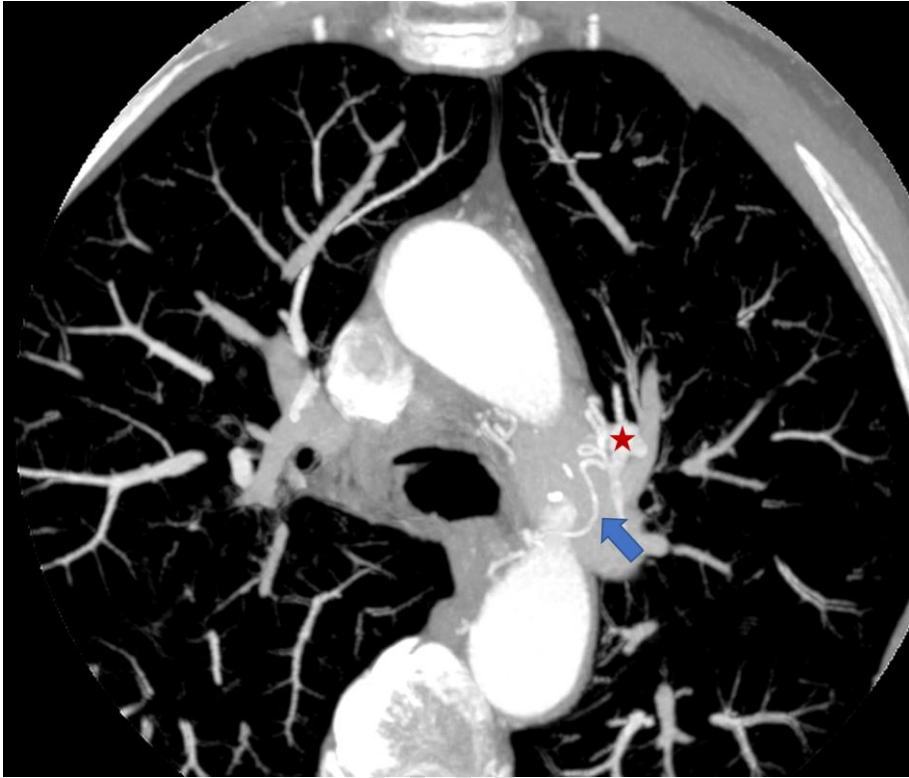


FIGURE 1 : Coronary CT Scan, axial view just under the aortic arch showing the CBF (blue arrow) creating creating an arterial confluence (red star) near the left atrial appendage. MIP 6 millimeters.

Commented [MF2]: delete it

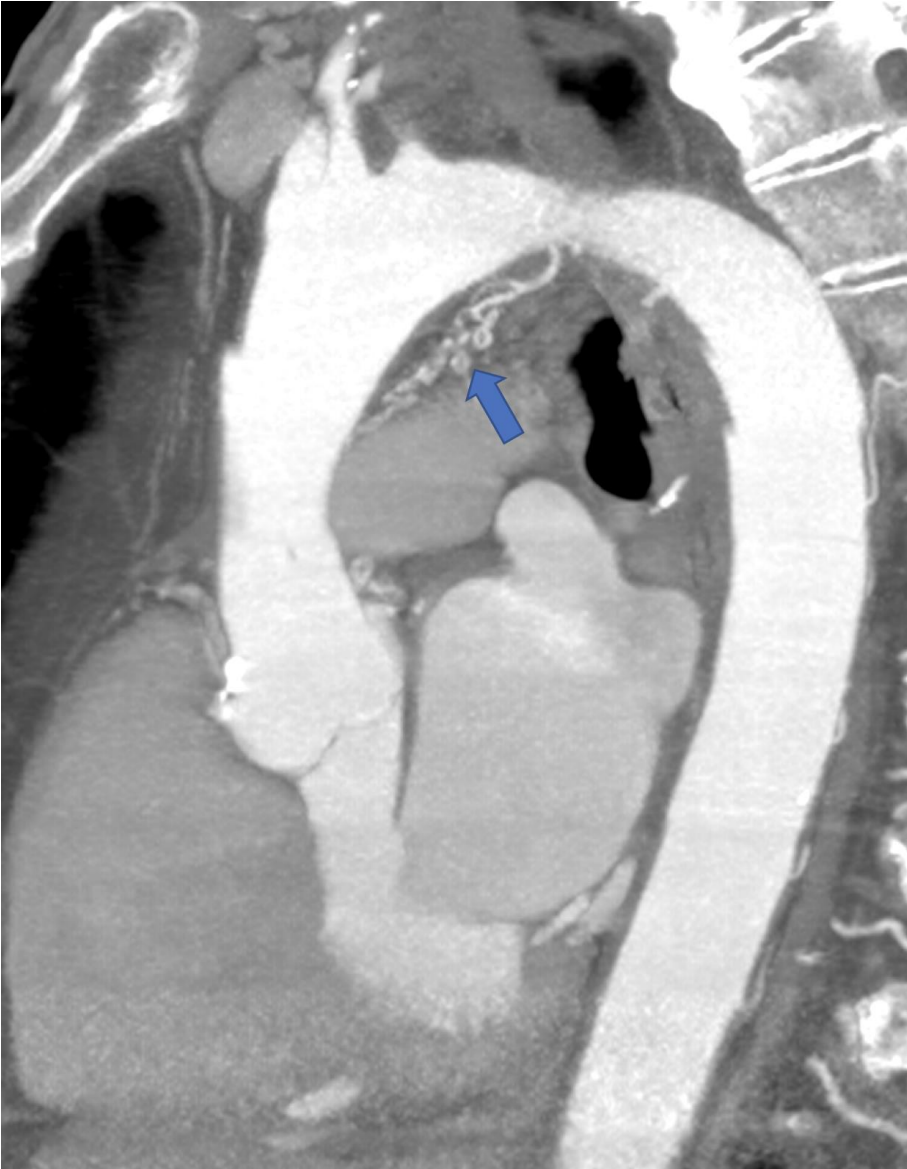

FIGURE 2 : Coronary CT Scan, coronal reconstruction showing the CBF (blue arrow) originating on the lower surface of the aortic arch.

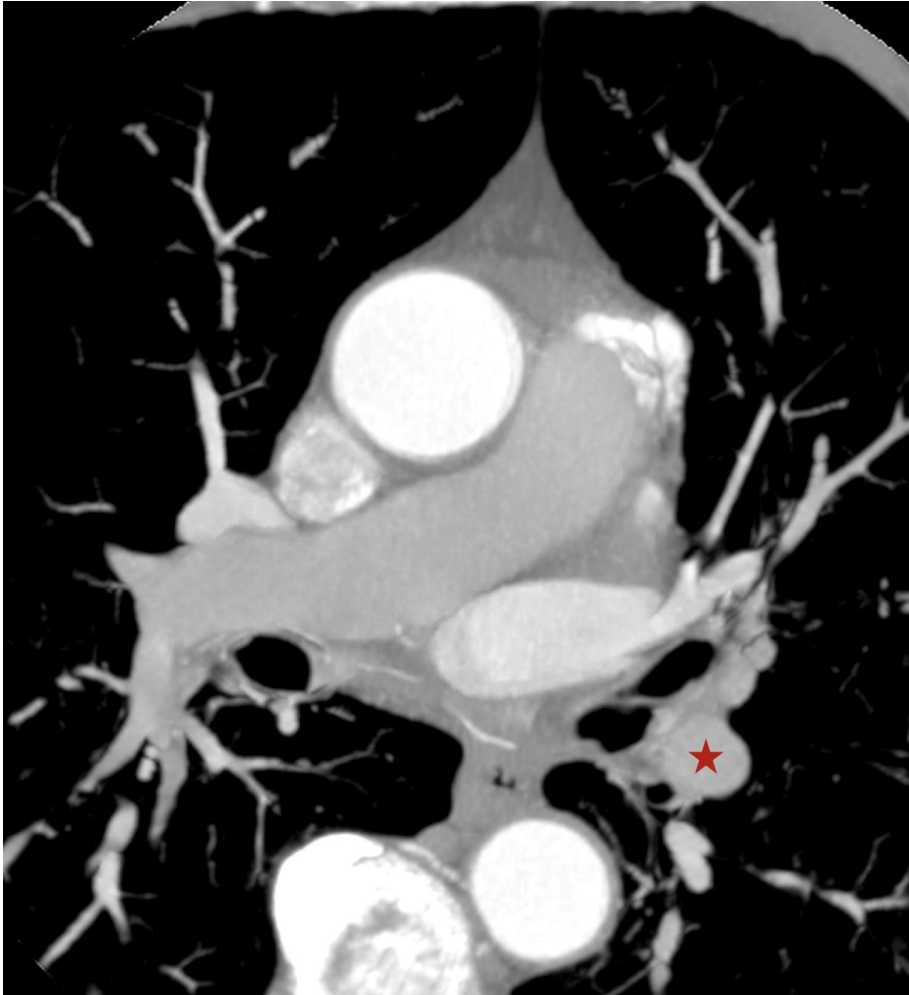


FIGURE 3 : Coronary CT Scan, axial view just under the pulmonary artery branching showing the arterial confluence (red star) created by the CBF near the left atrial appendage. MIP 6 millimeters.