

## Intracolonic Migration of an Abdominal Drain Through an Appendiceal Fistula: A Rare Post-Appendectomy Complication Managed Conservatively

### Abstract

In patients **c. with appendiceal fistula** undergoing conservative management, the main complication is inadequate or incomplete drainage of the fistula, which often leads to the consideration of more aggressive measures. We describe an extremely rare complication with an abdominal drain: intracolonic migration through appendiceal fistula. No such cases have been described in the literature. Our aim is to describe our experience and the therapeutic approach adopted to offer a less invasive treatment alternative, **c. avoiding major surgeries**, with good results.

Keywords: fecal fistula, appendectomy, Vacuum-Assisted Closure, Blumberg sign

### Introduction:

A fecal fistula is a rare complication following an appendectomy. It occurs more frequently in patients with compromised base of the appendix due to advanced inflammatory processes such as an appendiceal mass or gangrenous appendicitis, with an incidence of less than 1%.<sup>1,2</sup>

Therapeutic options may vary depending on the cause of the appendectomy: benign or malignant.<sup>3</sup> Conservative management with drainage and antibiotics has been described with high success rate in the absence of conditions that perpetuate the fistula (not high fistula output (<500 cc/day), absence of tumors, foreign bodies, distal obstruction, or infectious environment).<sup>4,5,6</sup> The optimal drainage ensures epithelialization of the tract, which allows the closure of the fistula<sup>6</sup> and avoid more aggressive reinterventions.<sup>7,8,10,11</sup> **b. The rarity of the complication and the successful non surgical management offers insights for similar situations.**

Other techniques such as VAC (Vacuum-Assisted Closure), fibrin glue injection, or clip placement via colonoscopy have shown satisfactory results for other type of fistulae.<sup>7,9</sup> Also, prevention could be possible through the placement of a cecostomy in patients with severe periappendicitis.

Presentation of a case and a literature search on PubMed with the terms: post-appendectomy fecal fistula.

### Case presentation

A 48-year-old male diabetic patient presented with a 3-day history of right iliac fossa abdominal pain associated with fever. Physical examination revealed a mass in the right iliac fossa with localized pain and a positive Blumberg sign.

Blood tests showed a CRP of 23.65 mg/dL and leukocytosis of  $18.22 \cdot 10^9/L$ . The diagnosis was confirmed by ultrasound, which showed a tubular structure with thickened walls and increased diameter associated with inflammatory changes, without free abdominal fluid, compatible with acute appendicitis. Laparoscopic appendectomy was performed, revealing a gangrenous appendix with an appendiceal inflammatory mass. There were no immediate postoperative incidents, and the patient was discharged on the 2nd day with outpatient antibiotic therapy. A week later, he returned with predominant

right iliac fossa abdominal pain associated with a low-grade fever. CRP was 8.70 mg/dL and leukocytosis was  $16.10 \cdot 10^9/L$ . A CT scan showed multiple postoperative collections. Antibiotic therapy was initiated, and laparoscopic drainage was performed without obtaining fecal material. A drain was left in the right iliac fossa. The patient completed a prolonged antibiotic regimen and was discharged with the drain and follow-up every 2-3 days. A week later, he reported fecal output through the drain without associated symptoms, no CRP elevation, or leukocytosis. Imaging tests showed the drain was well-positioned, without intra-abdominal collections.

## Discussion

Given the appendiceal stump fistula, a conservative approach was decided until closure, but fecal output increased. A CT scan showed the drain in the colon (Figure 1). Since the patient was asymptomatic, tolerating a diet, and had normal transit and lab parameters, a conservative approach was proposed.

The drain was clamped for 72 hours to monitor clinical evolution. Due to adequate tolerance, the drain was cut almost at skin level and sealed with a silk transfixing suture. The patient remained hospitalized under clinical observation, with analytical follow-up and radiological control. In the following days, the patient maintained oral tolerance and intestinal transit. Abdominal X-rays showed progressive advancement of the drain (Figure 2). Finally, he expelled the entire drain via the anus during defecation. No case reports of managing fecal fistulas involving invaginated abdominal drains were found in the literature. e. The patient was informed about the diagnosis and the procedure to evacuate the drainage tube, as well as the potential risks. Furthermore, he was informed about the interest of the management of the case for the scientific community, consenting to its sharing and publication.

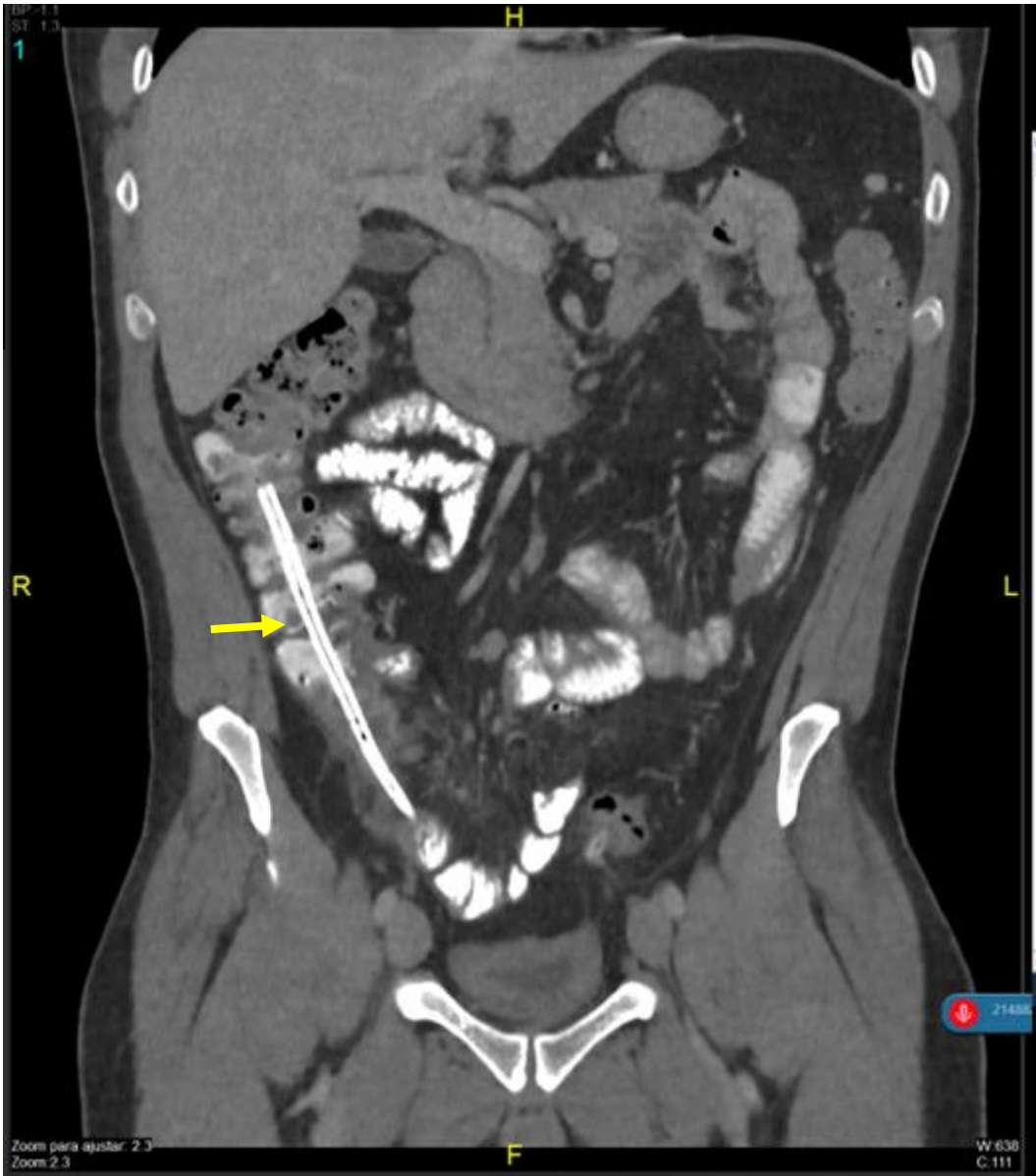
## Conclusion:

Post-appendectomy fecal fistula is a rare condition with significant morbidity. Conservative management has been described, although not involving the migration of a drain tube. In clinically stable patients with intracolonic migration of the drain and adequately collected fistulous output, major surgery can be avoided.

## Consent

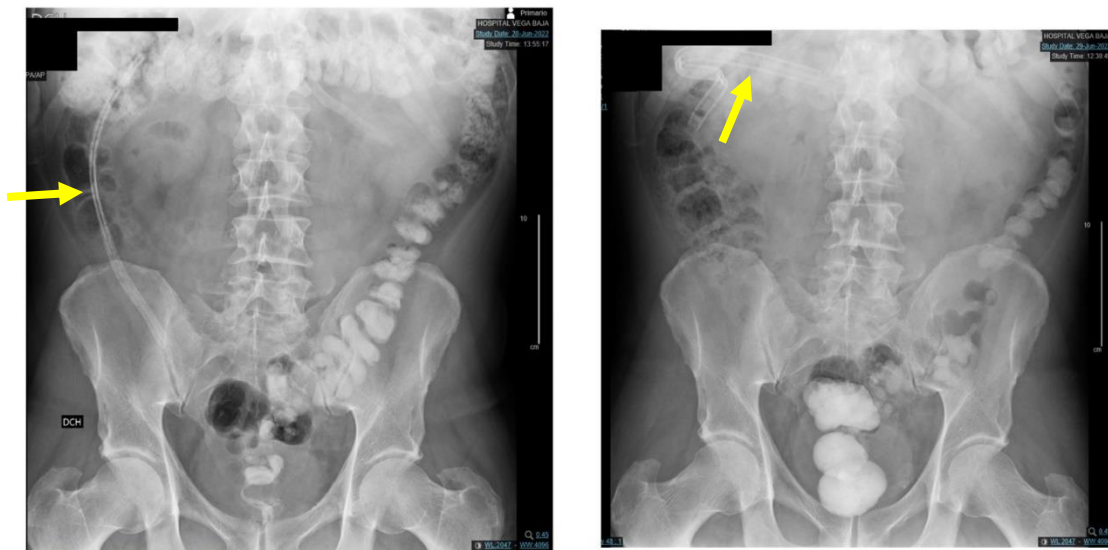
As per international standards or university standards, patient(s) written consent has been collected and preserved by the author(s).

FIGURE 1 CT report 1



UNDEL

FIGURE 2 Xray report 2



Disclaimer (Artificial intelligence)

Option 1:

Author(s) hereby declare that NO generative AI technologies such as Large Language Models (ChatGPT, COPILOT, etc) and text-to-image generators have been used during writing or editing of manuscripts.

Option 2:

Author(s) hereby declare that generative AI technologies such as Large Language Models, etc have been used during writing or editing of manuscripts. This explanation will include list the name, version, model, and source of the generative AI technology and as well as the all input prompts provided to a generative AI technology

Details of the AI usage are given below:

- 1.
- 2.
- 3.

## References

1. Mohamed, A. A., & Mahran, K. M. (2013). Laparoscopic appendectomy in complicated appendicitis: Is it safe?. *Journal of minimal access surgery*, 9(2), 55–58. <https://doi.org/10.4103/0972-9941.110963>
2. Flores-Marín, K., Rodríguez-Parra, A., Trejo-Ávila, M., et al. (2021). Laparoscopic appendectomy in complicated appendicitis with compromised appendix base: a retrospective cohort study. *Cirugía y cirujanos*, 89(5), 651–656. <https://doi.org/10.24875/CIRU.200009051>
3. Nakamoto, H., Yokota, R., Namba, H., Ishikawa, T., Yamada, K., Hosoda, M., & Taguchi, K. (2020). A Benign Appendiceal-Colonic Fistula, Diagnosed and Managed Laparoscopically: A Case Report. *The American journal of case reports*, 21, e925946. <https://doi.org/10.12659/AJCR.925946>
4. Deaver J. B. (1924). Appendiceal fecal fistula. *Annals of surgery*, 80(1), 56–57. <https://doi.org/10.1097/00000658-192407000-00007>
5. Genier, F., Plattner, V., Letessier, E., Armstrong, O., Heloury, Y., & Le Neel, J. C. (1995). Fistules caecales post-appendicectomies. A propos de vingt-deux cas [Post-appendectomy fistulas of the cecum. Apropos of 22 cases]. *Journal de chirurgie*, 132(10), 393–398.
6. Blackbourne LH. *Surgical Recall*, Recall series editor and senior editor. 2012. San Antonio, Texas. Lippincott Williams & Wilkins, a Wolters Kluwer business. 6th edition.
7. Mohamed A. Faecal fistula, the most unfortunate sequelae of appendectomy. Case report. *The Internet Journal of Surgery*. 2011;27(2):1–4. doi: 10.5580/2418.
8. McCrystal, S., Kong, J., Gourlas, P., Morris, B., & Lutton, N. (2019). Appendicorectal fistula with a novel solution: First case report and review of the literature. *Clinical case reports*, 7(10), 1885–1889. <https://doi.org/10.1002/ccr3.2380>
9. Olayode, Adegboyega MBBS; Kizer, Robert MD. Fibrin Glue Treatment of Enterocutaneous Fistula in Crohn's Disease: 1290. *American Journal of Gastroenterology* 107():p S512, October 2012.

10 Shehu, H., and M. Shehu. 2022. "Acquired Rectovaginal Fistula and Faecal Incontinence Following Sexual Assault in a 4-Year-Old Girl". *International Journal of Medical and Pharmaceutical Case Reports* 15 (2):12-15.

<https://doi.org/10.9734/ijmpcr/2022/v15i230153>.

11 Mueller MH, Geis M, Glatzle J, Kasperek M, Meile T, Jehle EC, Kreis ME, Zittel TT. Risk of fecal diversion in complicated perianal Crohn's disease. *Journal of Gastrointestinal Surgery*. 2007 Apr 1;11(4):529-37.

UNDER PEER REVIEW