

Review Article

REDEFINING ENDODONTICS: THE ROLE OF REVASCULARIZATION IN SAVING AND RESTORING TEETH – A COMPREHENSIVE REVIEW

Abstract :

Pulp regeneration may be defined as the replacement of damaged tissue by cells identical to the lost tissue, leading to the complete reestablishment of biological function. Regenerative Endodontic Procedures (REPs) encompass use of biomimetic scaffolds; bioactive molecules that help deliver specific compounds (growth factors) to a targeted site and stem cells. When periapical granulation tissues infiltrate via the open apex of immature permanent teeth with clinically confirmed necrotic pulps or apical periodontitis, they can replace the residual pulp tissue in the apical canals. Cell-homing uses growth factors and other biologic signaling molecules for migration, proliferation, and differentiation, but there is a lack of information on the appropriate growth elements. Cell-homing strategies have been successful in healing necrotic pulp and arresting root formation, but there is a lack of information on the appropriate growth elements.

Keywords: Regenerative Endodontic Procedures, Pulp regeneration, growth factors, apical canals

INTRODUCTION

One of the major endodontic challenges is to restore immature, developing permanent teeth which have been injured or damaged due to infection, trauma or caries or have an anomalous anatomy¹. To curb the effects of pulpal trauma on developing permanent teeth, regenerative endodontic procedures have become quite sought after. The factors mentioned above mostly lead to ischemic pulp injury, and consequently, pulpal necrosis. Furthermore, in a tooth with open apex, the thinner, underdeveloped dentin makes these teeth susceptible to unwanted root fractures². Therefore, regenerative techniques that help maintain pulp vitality are of interest.¹

Regenerative Endodontic Procedures (REPs) encompass use of biomimetic scaffolds; bioactive molecules that help deliver specific compounds (growth factors) to a targeted site and stem cells². In the periapical region of an immature permanent tooth, these regenerative procedures have been possible due to the pulp's intrinsic nature- being a conglomeration of various cell types, including progenitor stem cells, complete with an extracellular matrix and ground substance³. Stem cells are paramount to revascularization and regeneration and two types of stem cells have been recognized- adult and embryonic stem cells, which have been localized in the PDL and in the tooth apex. Adult totipotent stem cells have the capacity to differentiate into various tissue types, depending on their induction³. Pulpal stem cells, owing to their neuroectodermal origin are capable not only of dentin-pulp complex formation, but also nerve tissue regeneration. Successful pulpal revascularization would result in a vital, immature permanent tooth capable of root completion, which would otherwise have to be treated by apexification³.

Ostby had found that pulp vitality was regained when root canal space's sterility was maintained as the periapical tissues made their way in via regrowth through the apical foramen². The regenerated, revascularized pulp formed after stimulation of periapical stem cells with growth factors, will be histologically and functionally similar to damaged pulp tissue, thus maintaining a healthy tooth and making revascularization increasingly superior to conventional apexification².

DEFINITIONS

Pulp regeneration may be defined as the replacement of damaged tissue by cells identical to the lost tissue, leading to the complete reestablishment of biological function.⁵

Revascularization may be defined as the invagination of undifferentiated periodontal cells from the apical region in immature teeth⁶⁻⁷.

HISTORY

The term "revascularization" itself is not new. Ostby¹⁰ first described it in 1961, and Rule and Winter¹¹ observed root growth and the creation of the apical barrier in pediatric pulpal

In 2001 and by Banchs and Trope¹⁴ in 2004 The outcome was a radiographically apparent normal maturation of the whole root. The scope of REPs in necrotic teeth was first analyzed by Nygaard-Ostby in 1961. Iwaya et al in 2001 detailed about the treatment procedure termed revascularization that had the potential for root maturation²⁰. In 2004, Banchs and Trope proposed the protocol for revascularization of immature permanent teeth with apical periodontitis using triple antibiotic paste (TAP)⁴.

PATHOGENESIS OF IMMATURE TEETH

According to Horan and Ashcroft (1997), it is commonly known that younger patients have a better immunological defense system than older patients. Young, immature permanent teeth with wide-open apices also enable pulp blood circulation to effectively defend the canal space via cellular and molecular components of innate and adaptive immune mechanisms¹⁷. Only a histological investigation can clarify whether or not there is still vital pulp present in the canal space of immature permanent teeth with apical periodontitis. Every essential tissue is both innervated and vascularized¹⁷. During wound healing, necrotic tissue is typically replaced by either reparative scar tissue or granulation tissue that grows from the nearby inflamed tissue (Majno & Joiris 2004, Kumar et al. 2015). Dentine walls provide excellent protection for necrotic pulp tissue in the canal area against periapical granulation tissue formation through the apical foramen constriction⁵.

When periapical granulation tissues infiltrate via the open apex of immature permanent teeth with clinically confirmed necrotic pulps or apical periodontitis, they can replace the residual pulp tissue in the apical canals. Differentiating between an apical periodontitis and a growing apical papilla in juvenile permanent teeth with diseased necrotic pulps and periapical radiolucent lesions can occasionally be challenging¹⁷.

AAE's "Clinical Considerations for a Regenerative Procedure" states that teeth with an underdeveloped apex and a necrotic pulp should have RET.. Premature permanent teeth with necrotic pulp at stages 1 (less than 1/2 of root formation with open apex), 2 (1/2 root formation with open apex), and 3 (2/3 of root development with open apex) are recommended for RET due to the short root, thin canal walls, and wide-open apex as

apexification has no potential. This is based on Cvek's classification of root development (Cvek 1992)¹⁶.

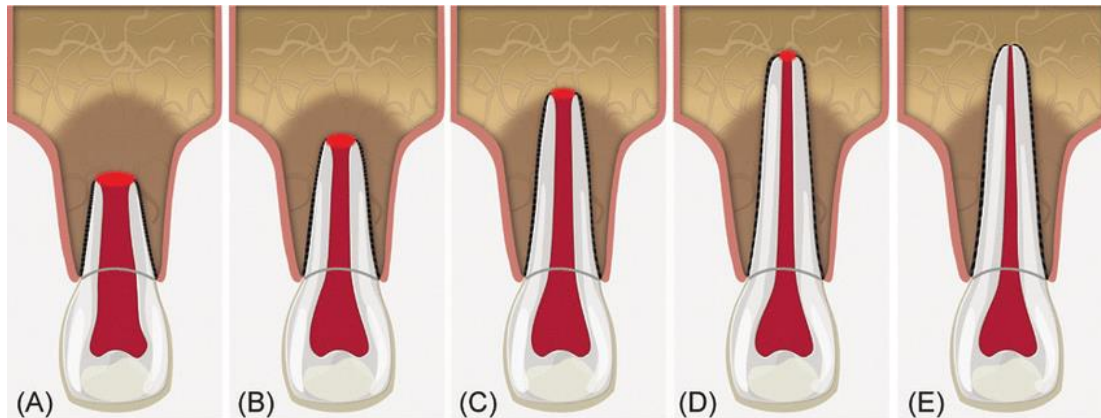


Plate 1 : Schematic of Cvek's stages of root development. (A) Group I, < 1/2 root length; (B) Group II, 1/2 root length; (C) Group III, 2/3 root length; (D) Group IV, wide open apical foramen and nearly completed root length; (E) Group V, closed apical foramen and completed root development. Groups I, II and III show wide and divergent apical opening²⁷

Revascularization appears to be more predictable in the case of apical holes larger than 1 mm in diameter and less likely to happen in apical openings smaller than 0.3 mm²⁵.

It is possible to treat immature permanent teeth at stage 4 (almost finished root formation with an open apex) with either RET or an apical MTA plug¹⁶.

MECHANISM

The mechanism of revascularization is explained by several ideas, multipotent periodontal cells with a high potential for developing into new fibroblasts and cementoblasts are found in the periapical zone of young teeth. Therefore, it has been proposed that apical closure and increased dentinal walls are caused by differentiated cementoblasts and fibroblasts².

Another theory proposes that young, immature teeth may include a large number of leftover multipotent stem cells from pulp tissue, which would seeded onto the dentinal walls and produce odontoblast-like cells for the development of root ends¹⁵.

A potential third scenario entails the infiltration of stem cells from the apical papilla into the root canal. These cells possess a high proliferative capacity and may be transported within the canal in conjunction with periapical tissue bleeding, as suggested by blood induction of the periapical tissues².

The fourth theory could be that Stem cells from the apical papilla or bone marrow may be responsible for the root growth. Mesenchymal stem cells can be transplanted from the bone into the canal lumen by using instruments outside of the root canal to cause bleeding, As the proliferating capacity of these cells is vast¹⁵.

The connectivity of canal space and periodontal tissue to accomplish apical healing with periodontal tissue may be facilitated by the root structure of juvenile teeth, which includes an open apex, a large root canal, and thin radicular dentin walls².

Lastly, it might be because the blood clot itself plays a significant role in regeneration and is a rich supply of growth factors. Among these growth factors are vascular epithelial growth factor (VEGF) and platelet-derived growth factor (PDGF), which can promote the development, maturation, and differentiation of immature and undifferentiated mesenchymal cells into fibroblasts, odontoblasts, cementoblasts, and other cell types in the newly formed tissue matrix¹⁶.

CRITERIA FOR CASE SELECTION

In teeth of cooperative patients with necrotic pulp, open apex, and pulp cavity—none of which require post-core restoration—the American Endodontic Association (AAE) has advised the use of regenerative endodontic treatment. Immature permanent teeth with irreversible pulpitis, necrotic pulp teeth without radiographic evidence of apical periodontitis, or traumatized immature permanent teeth are the best candidates for pulp regeneration, according to Shimizu et al. (2012)²⁰.

According to George et al. (2010), the pulp vitality test result or the existence of radiolucency in the periradicular area should no longer be taken into consideration when making decisions. It is believed that in both situations, there may still be viable pulp tissue or apical papilla cells in the root canal or apical portion of the root²⁰

Based on Cvek's classification system for root development, the subsequent suggestions were put forth⁴:

Because of their short roots, thinned-out canal walls, and wide-open apex, immature permanent teeth with pulp necrosis at stages 1, 2 and 3 may be ideal for RET. RET or an apical MTA plug, along with a dense root canal filling, are recommended for the management of juvenile permanent teeth at stage 4, which is characterized by substantially full root growth and an open apex⁴.

GENERAL HEALTH- One tool for determining a patient's physical health status is the American Society of Anesthesiologists' (ASA) Health Classification System. For patients who are categorized as ASA 1 and ASA 2, REPs may be taken into consideration²¹. Patients with compromised immune systems, those with poorly managed diabetes or long-term hormone medication use, poorly managed hypertension, coronary artery disease, a recent (less than three months) myocardial infarction, or a cerebrovascular accident REPs are not advised²¹.

A) THE PATIENT'S AGE

Young patients between the ages of 9 and 18 are thought to be good candidates for REPs due to their higher potential for stem cell regeneration. When REPs are performed on deciduous teeth, there is a chance that the eruption pattern of permanent teeth may be affected⁴.

B) APICAL DIAMETER SIZE

One of the main concerns in RET has been the apical diameter of immature permanent teeth. Revascularization was found to be unpredictable in transplantation experiments if the tooth's apical foramen measured less than 1 mm (Andreasen et al. 1990)¹⁷.

Regenerative techniques were shown to be successful with an apical diameter as little as 0.5 mm in a clinical investigation. But younger permanent teeth showed more root maturation when their preoperative apical diameter was broader than 1 mm (Estefan et al. 2016)¹⁷

The greatest clinical success rate was found for apical diameters between 0.5 and 1.0 mm (Fang et al. 2018). The reason for this is that the apical area can send osteoblasts, cementoblasts, periodontal ligament cells, and endothelial cells through the apical foramen to generate bone, cementum, periodontal ligament, and blood vessels in the canal space. Human cells typically have a size between 10 and 100 μm . Thus, even with an apical foramen that is less than 0.5 mm in diameter, osteoblasts, cementoblasts, periodontal ligament cells, and endothelial cells can readily access the canal area¹⁷.

PROCEDURE

PRIOR TO THE PROCEDURE

Patients, their parents, or legal guardians should be given comprehensive information regarding the treatment including the procedure and the complications²¹. Before beginning treatment the Informed Consent Form should be signed.²¹

FIRST APPOINTMENT

1. Local anesthesia to be administered, isolation should be done using rubber dam²²
2. Access cavity preparation and working length determination confirming with radiograph with a file positioned at 1mm from apex²².
3. Minimal instrumentation using larger size of files or reamers such as H file circumferentially “brushing” the canal walls without major dentin removal²¹.
4. Using an irrigation device that reduces the chance of irrigants extruding into the periapical space, such as EndoVacTM or a needle with a closed end and side vents, apply a generous amount of gentle irrigation with 20ml of NaOCl. To reduce cytotoxicity to stem cells in the apical tissues, lower doses of NaOCl are recommended [1.5% NaOCl (20 mL/canal, 5 min) and then irrigated with saline or EDTA (20 mL/canal, 5 min), with irrigating needle positioned approximately 1 mm from root end²².
5. Dry the canals using paper points²².
6. Place triple antibiotic paste (TAP) or calcium hydroxide²².

In order to reduce staining risk,

- Seal the pulp chamber with a dentin bonding agent if the triple antibiotic paste is used¹⁹.
 - Combine ciprofloxacin, metronidazole, and minocycline in a 1:1:1 ratio until the final concentration is between 0.1 and 1.0 mg/ml²³.
 - Another viable substitute for minocycline as a root canal disinfectant is double antibiotic paste without minocycline or substitute minocycline for another antibiotic (such as clindamycin, amoxicillin, or cefaclor)²².
7. Deliver via a syringe into the canal system. Make sure the triple antibiotic dose stays below the CEJ (minimize crown staining) if it is utilized²².
 8. Apply a thin layer of 3–4 mm of a temporary restorative material. Recall the patient for one to four weeks²².

SECOND APPOINTMENT

Rescheduled visit (one to four weeks following the first)

Evaluate the initial therapy response. Consider using a different antibiotic or extending the duration of antimicrobial treatment if there are indications of a persistent infection²².

9. Rubber dam isolation, 3% mepivacaine anesthesia without vasoconstrictor²².

10. Irrigate generously and gently using 20ml of 17% EDTA, Utilizing paper points, dry²².

11. Fill the canal with blood up to the cemento-enamel junction by rotating a pre-curved K-file at 2 mm past the apical foramen, causing bleeding into the system through over-instrumentation. Using platelet-rich plasma (PRP), platelet rich fibrin (PRF), or autologous fibrin matrix (AFM) is an alternative to forming a blood clot²².

12. Once 3–4 mm of restorative material can be placed, stop the bleeding.

If necessary, cover the blood clot with a resorbable matrix like CollaPlug™ or CollaTape™ and use white MTA as the capping material²².

13. A thin coating of light cure glass ionomer, measuring 3-5 mm, is gently applied on top of the capping material. MTA and discoloration have been linked. When it comes to teeth where aesthetics are an issue, alternatives to MTA (such bioceramics or tricalcium silicate cement) should be taken into account²².

14. A filled composite should be bonded to the beveled enamel margin of anterior and premolar teeth after 3 mm of a no staining restorative material has been restored. Collatape/Collaplug may be used in these cases and in Molar teeth or teeth with PFM crowns: Take into account using Collatape/Collaplug and restoring with 3 mm of MTA, then RMGI, composite²².

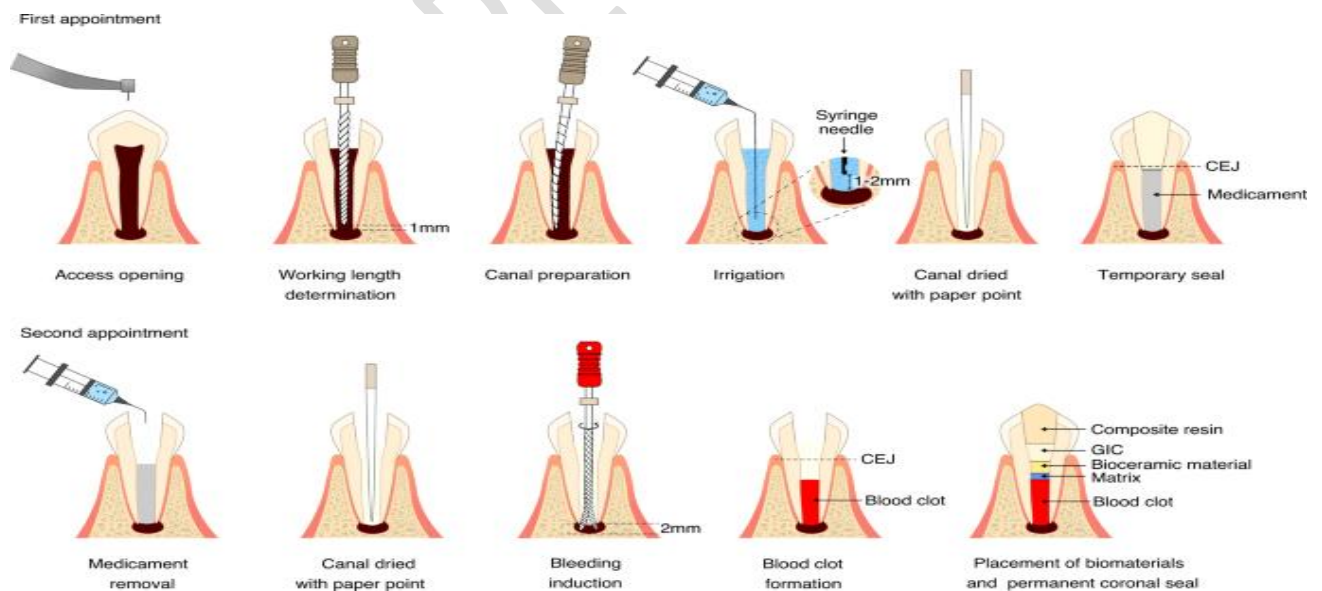


Plate 2. SCHEMATIC REPRESENTATION OF PROCEDURE²¹

FOLLOW UP AND OUTCOMES

Radiographic and clinical examination

Absence of sinus tract, soft tissue edema, or pain (frequently noticed in between the first and second sessions)²².

Apical radiolucency resolution (typically seen 6–12 months following therapy)²³.

OUTCOMES

The success of REPs can be determined by assessing the following treatment outcomes, per clinical considerations for REPs (AAE)⁴

- Removing clinical indications and symptoms and demonstrating evidence of bone healing is the main or most important objective⁴.
- Maintaining root maturation, or growing longer and/or thicker roots in the root canal, is the secondary or ideal objective⁴.
- The restoration of neurogenesis or a favourable vitality test result is the tertiary objective⁴.

According to Chen et al. (2015), the main objectives of treating infection signs and symptoms and promoting bone healing may usually be accomplished, while unsuccessful cases have been linked to inadequate filing and cleaning procedures¹⁷. According to two recent systematic studies (Tong et al. 2017 and Torabinejad et al. 2017), there is a high probability of achieving the primary target of RET, which is 91-44% of periapical healing¹⁷.

RADIOGRAPHIC OUTCOME

Five different ways to respond to REP were outlined by Chen et al²³.

Type 1: the apical aperture closing and the length and thickness of the root wall increasing

Type 2: there is no discernible increase in the thickness and length of the roots, but the apical opening has closed

Type 3: roots that grow thicker and longer, with an open apical aperture;

Type 4: calcification or obliteration of the root canal lumen

Type 5: the hard tissue layer that sits between the applied clot sealing substance (MTA/Biodentine) and the root apices of the teeth²³.

According to several studies (Chen et al. 2012, Alobaid et al. 2014, Kahler et al. 2014, Tong et al. 2017), these observations are not always predictable following RET of juvenile permanent teeth with necrotic pulps¹⁷.

HISTOLOGICAL OUTCOME

Two methods of healing following tissue damage are regeneration and repair. There is debate on the type of tissue that develops following RET. Apical papilla stem cells are able to endure even in the aftermath of apical periodontitis or pulp necrosis. The pulp-dentin complex may regenerate in the disinfected canal space when they move in with the growth ingredients⁴. Nonetheless, the tissue discovered in the canal space following RET appeared to be bone-like, cementum-like, periodontal ligament (PDL)-like, and not pulp-like tissue in the majority of histologic investigations carried out¹⁷.

According to certain research, pulp-like tissue can still exist after RET. However, in those instances, the pulp may have had some pulp tissue remaining in the canal since it was not necrotic prior to the therapy. Thus, it can be inferred from histologic results that RET involves tissue repair rather than genuine regeneration⁴.

ROOT CANAL DISINFECTION

When treating infected root canals with endodontic therapy, the initial step is to disinfect the area using chemicals and instrumentation².

Nevertheless, because of the thin root walls' fragility, it is not advised to mechanically remove microorganisms from immature teeth; instead, irrigant solutions and intracanal medication are the only methods of decontamination that can be used².

INTRACANAL IRRIGANTS

A) SODIUM HYPOCHLORITE

In root canal therapy, sodium hypochlorite is the most often used antiseptic irrigating solution

Research has demonstrated the high effectiveness of sodium hypochlorite in eliminating biofilm produced by five distinct root canal bacterial isolates (Spratt et al., 2001). Sena et al. (2006) found that 5.25% sodium hypochlorite could eradicate single-species biofilm in just thirty seconds¹⁷. The range of suggested concentrations is 0.5% to 5.25%. Sodium hypochlorite's cytotoxicity increases with concentration³. The 2.5% concentration appears to be the most advantageous choice between effectiveness and nontoxicity³.

Additionally, Cunningham demonstrated that raising the 2.5% sodium hypochlorite solution's temperature to 37° C increases its solvent power and makes it equal to the solution's efficiency at 5.25% hypochlorite solution²³. It is recommended to use low concentrations of sodium hypochlorite because high concentrations may be toxic to SCAP and may prevent stem cells from adhering to the dentin surface³.

As per the American Association of Endodontists, a concentration of 1.5–3% of NaOCl represents a reasonable balance between the preparation's antibacterial efficacy and stem-cell protection²³.

B) CHLORHEXIDINE

Regarding chlorhexidine, case studies have employed concentrations of 0.12% and 2%². These materials have adequate antimicrobial qualities, but they are not biocompatible, which reduces their ability to adhere to dentinal walls and support the survival of dental pulp stem cells².

In certain instances, 2% gel chlorhexidine was suggested as a short-term treatment³. Due to the carryover effect, it effectively combats gram+ bacteria and candida. Because of its positively charged molecules, which have the ability to be adsorbed by the dentin walls, chlorhexidine can be released for a minimum of two to twelve weeks, preventing reinfection of the root canal during that time³. Despite this benefit, the dissolving action of chlorhexidine is ineffective³.

If chlorhexidine is used, Basrani et al. advise using sterile saline in between the NaOCl and chlorhexidine rinses to avoid precipitation¹⁹.

C) EDTA

The smear layer can also be removed by using chelating agents like EDTA, citric acid, and MTAD in addition to irrigant solutions⁴.

MTAD, which is made up of 3% thiosulfate, 4.25% citric acid, and 0.5% polysorbate, was recently introduced by Torabinejad et al.². In the meantime, EDTA is the most widely used chelating agent and has the ability to trigger the release of different growth factors that are part of the human dentin matrix. It's unclear if EDTA could harm stem cells, despite the substance seeming to have some potential².

The smear layer can be removed and the irrigation system is made more wettable with EDTA-type chelating. Trevino, who investigated how irrigants affect the survival of apical papilla human stem cells, claims that using EDTA prior to irrigators allowing these cells to survive as long as possible³.

In cases of bacterial infection, 17% EDTA is frequently used to remove the smear layer, open the dentin tubule entrance (allowing a better chance of joining tissue of regeneration), and induce a better penetration of the irrigator (increasing the irrigator's wettability) and of root canal medications¹⁹.

In a prior investigation on the impact of irrigation solutions on growth factor release, Zeng et al. (2016) found that, in comparison to the irrigation group using only 17% EDT, TGF-β1 release was significantly increased by 1.5% NaOCl + 17% EDTA or 2.5% NaOCl + 17% EDTA²⁰.

For the purpose of eliminating the smear layer, 1% phytic acid (IP6) has been suggested as an alternative to the EDTA solution because of its potent chelating action and biocompatibility²⁴

INTRACANAL MEDICAMENTS

A) TRIPLE ANTIBIOTIC PASTE

In order to manage infection inside root canals and simultaneously permit ingrowth of new tissue to maintain root formation, pulp revascularization began to employ antibiotic paste as the gold standard for intracanal treatment²¹.

To create a creamy consistency, 400 mg of metronidazole, 250 mg of ciprofloxacin, and 50 mg of minocycline are combined to create antibiotic paste².

One can introduce the paste with a manual file, syringe, or Lentilo spiral drill. Antibiotic paste, while showing encouraging results, may cause adverse effects such crown discoloration because it contains minocycline².

According to a study by Hoshino et al., the trio of antibiotics completely sterilizes germs while each antibiotic alone is useless against bacteria found in pulp, dentine, and apical lesions³.

The three antibiotics that make up the paste are metronidazole (spectrum of anaerobic bacteria and protozoa), ciprofloxacin (spectrum of gram+ and gram-), and minocycline (spectrum of gram+ and gram-)³

In addition to ciprofloxacin and metronidazole, a number of other antibiotics have also been used, including amoxicillin, cefaclor, cefroxadin, fosfomycin, and rokitamycin. While it has been demonstrated that all of these triple antibiotic combinations stop bacteria from growing,

triple antibiotic pastes that contain minocycline have outperformed other pastes in terms of root wall thickness ¹⁹.

The use of minocycline in TAP may result in tooth discoloration. Other alternatives are to include using cefaclor and clindamycin in place of minocycline or using DAP without minocycline²¹. Bose et al. report that when triple antibiotic paste is used instead of the other two intracanal drugs (calcium hydroxide and formocresol) for bonding and etching, the thickness of the dental canal walls increases by the largest proportion³.



Fig 1-3 : Triple Antibiotic Paste

B) CALCIUM HYDROXIDE

Calcium hydroxide is a strong base with a pH between 12.5 and 12.8. Its ionic dissociation in Ca^{2+} and OH^- encouraged the genesis of hard tissue (apexification, tertiary dentin), and the release of ion OH^- has an antimicrobial effect ³

Owing to its antibacterial qualities, which prevent microbial growth, calcium hydroxide is commonly utilized as an intracanal drug in endodontic procedures and apexification situations². Recently, pulp revascularization has also been explored with calcium hydroxide, and the results demonstrate success both clinically and radiographically².

Studies have shown that using calcium hydroxide to dress root canals can solubilize bioactive molecules, such as growth factors of the human dentin matrix, which would probably encourage mesenchymal pulp cells to differentiate into odontoblast-like cells. It can also protect the epithelial root sheath cells of Hertwig². It also provides the maximum survival of stem cells even at a greater dosage of 1 mg/mL. Antibiotic paste only permits 33% to 56% of cells to survive at the same concentration ²⁶

Chueh et al. found that teeth medicated with calcium hydroxide had a significant rate of increasing calcification of the root canal space, indicating that the natural pattern of root development generated by regenerative endodontic treatment is not followed, In order to allow dentinal wall thickening, $\text{Ca}(\text{OH})_2$ paste application should be restricted to the coronal half of the root canal.¹⁹

TISSUE ENGINEERING

BLOOD CLOT/ SCAFFOLDS

Ostby was the first to employ the use of a blood clot to regenerate dental pulp tissues, which led to the formation of fibrous, granulation, or cementum-like tissues into the root canals. Using blood clots, Myers and Fountain were able to successfully create 0.1–1.0 mm of soft connective tissues inside the root canal in 1974. The blood clot consists of fibrin matrix that traps cells important for tissue regeneration.²

Additionally, it offers a good channel for periapical region cells, such as fibroblasts and macrophages, to migrate into the root canal and promote the formation of new tissue. The blood clot can promote tissue regeneration by playing a significant role in cell differentiation due to its rich supply of growth factors¹.

A dense, growth factor-rich cellular dentin matrix completely encloses the root canal space. A few of these include growth hormone, IGF-1 and -2, BMP-2, -4 and -6, and TGF- β -1, 2. These growth factors are essential for controlling the inflammatory response, tissue regeneration and repair, and odontoblast differentiation when they are liberated from the dentin matrix⁴.

PRF and PRP

Whitman introduced platelet-rich plasma (PRP) to the dental community in 1997. PRP may have the ability to draw stem cells from the periapical tissues around it¹⁶. PRP plus dental pulp cells have been shown to promote critical tissue regeneration in the root canals of puppy teeth. PRP can generate new tissue in the root canal more quickly in a clinical setting.

PRP is plasma derived from autologous blood consists of higher concentrations of growth factors due to its higher platelet concentrations²³. Second generation platelet concentrate from PRF is an autologous fibrin mesh that is not thrombinized and acts as a reservoir for the gradual release of growth factors²³. Purified red blood cells (PRF)—basically just pure centrifuged blood—naturally undergo polymerization, whereas platelets require binding to bovine thrombin and calcium chloride to initiate the last phases of coagulation. Growth factors that support stem cell proliferation for healing induction and tissue regeneration have been linked to the clinical and radiographic success of revascularization/revitalization treatments using PRF and PRP.¹⁹

PRP and PRF were used as a scaffold rather than a blood clot by Shivashankar et al. 2012, Keswani & Pandey 2013, Mishra et al. 2013, Narang et al. 2015, Ray et al. 2016, Bakhtiar et al. 2017, because PRP and PRF are rich in growth factors, which may aid promote regeneration of pulp–dentine complex¹⁷.

The use of antibiotic-containing nanofibrous scaffolds for regenerative endodontics was assessed by Bottino et al. in a recent study. They concluded that these scaffolds hold promise for improving current regenerative strategies by acting as a matrix for the growth and differentiation of new tissue in the root canal and as a drug delivery system to disinfect necrotic immature permanent teeth through a controlled release of low antibiotic doses¹⁹.

CORONAL SEALING

In order to stop additional reinfection, coronary access must be sealed³. The current clinical protocols require covering the blood clot with a piece of CollaPlug (Zimmer Dental Inc., Warsaw, IN). This acts as an interior matrix into which roughly 3 mm of white MTA (Dentsply, Tulsa, OK) is placed⁴. The MTA is then covered with a 2-4 mm layer of glass

ionomer, which is followed by a composite resin restoration. MTA is well-liked for its antibacterial and biocompatibility qualities. Biodentine can be used instead of MTA⁴

These days, a number of bioceramic cement varieties, including BioAggregate and Biodentine, are accessible for use in endodontics and are not known to cause discoloration¹⁹.

Compared to MTA, Peng et al. showed that utilizing GIC with a REP procedure increased the risk of periapical tissue infection²³. Using MTA's white variant, or Biodentine, is advised to reduce the possibility of crown discoloration after application²³.

ADVANTAGES

- (1) Achieving continuous root growth (root lengthening) and root strengthening as a result of hard tissue/new dentin deposition reinforcing the lateral dentinal walls¹⁵.
- (2) The possibility of root fracture during lateral condensation is eliminated because, in contrast to calcium hydroxide-induced apexification, obturation of the canal is not necessary¹⁶.
- (3) From the standpoint of tissue engineering, the benefit of pulp regeneration in mature teeth is the restoration of the root canal's neurovascular system, which gives the tooth an immune system to fight against resistance from bacteria¹⁵.
- (4) Restoring tooth vitality.

LIMITATIONS

- (1) Because of the length of the treatment and the number of clinical appointments required, patient compliance may be a challenge⁴.
- (2) Grey/white crown discoloration in TAP and MTA linked to minocycline¹⁷.
- (3) Histologic proof that following RET; there was repair rather than real regeneration⁴.
- (4) Following RET, some of the cases showed evidence of root fractures¹⁶.
- (5) Internal ankylosis may be brought on by cementum, PDL, and bone ingrowth into the canal space¹⁵.
- (6) Following revascularization, reports of intra-canal calcification have been made¹⁶.
- (7) Revascularization is not an appropriate course of treatment if post and core are the last restorative measures chosen since post placement cannot breach the critical tissue in the apical two thirds of the canal¹⁵.
- (8) According to the revascularization technique, a blood clot's production produces a matrix that ensnares cells with the ability to proliferate new tissue. But the concentration and nature of cells trapped in the fibrin clot is unpredictable. Platelet concentrates can be used to get around this restriction. For revascularization, platelet-rich plasma is the perfect scaffold¹⁶.

FAILURE AND COMPLICATIONS

The main causes of unsuccessful instances are either insufficient disinfection (Yadav et al. 2015, Zizka et al. 2016) or insufficient biofilm removal, which may be the result of inadequate instrumentation (Lin et al. 2014). Failures were also linked to root canal system reinfection (Alobaid et al., 2014), which may have resulted from restorations that failed and allowed coronal leakage. According to Martin et al. (2013), Shimizu et al. (2013), Saoud et al. (2016), root fractures happened in certain situations. It's possible that there is disagreement regarding the osseous tissue found in the root canal system during the restoration process (Andreasen & Bakland 2012)¹⁷. According to Song et al. (2017), a recent study, the prevalence of intracanal calcification related with revascularization was approximately 62.1%. This poses the question of how to handle immature root canal calcification¹⁹.

In teeth treated with revascularization instances, RAIC falls into one of two categories: canal obliteration (CO) or calcific barrier (CB)¹⁹. While the precise physiopathological cause of RAIC is still unknown, some experts speculate that ectopic bone development and cementogenesis within the root canals may be the cause. ProRoot MTA and Biodentine are two examples of bioactive compounds that can stimulate MSC proliferation and encourage mineralization in the canal space¹⁷.

FUTURE PRESPECTIVE AND CONCLUSION

Cell-based and cell-homing approaches are used for pulp tissue regeneration, with cell-based therapy involving the expansion and isolation of stem cells from allogeneic or host sources. Cell-homing uses growth factors and other biologic signaling molecules for migration, proliferation, and differentiation, but there is a lack of information on the appropriate growth elements. Cell-homing strategies have been successful in healing necrotic pulp and arresting root formation, but there is a lack of information on the appropriate growth elements. Pulp revascularization is a promising treatment for young teeth, suggesting an alternative to apexification in endodontic cases of irreversible pulpitis and pulp necrosis. This procedure encourages dentin wall thickness and apical closure, preventing tooth weakness. However, its long-term negative effects are not well understood. Long-term clinical research could help understand the composition and mechanical characteristics of mineralization in inner dentinal walls. Post-rehabilitations are crucial for extending immature tooth longevity and improving future prognosis in revascularized teeth

REFERENCES

1. Pulp Revascularization: A Literature Review
Pollyana Rodrigues de Souza Araújo, Luciano Barreto Silva, Alexandrino Pereira dos Santo Sampaio, open dentistry journal ,2017
2. Pulp revascularization: an alternative treatment to the apexification of immature teeth
maria tereza pedrosa albuquerque, juliana yuri nagata,adriana de jesus soares, alexandre augusto zaia , odontol , 2014
3. Review Article- Pulp Revascularization of Immature Permanent Teeth: A Review Of the Literature and a Proposal of a New Clinical Protocol
Mélanie Namour and Stephanie Theys, scientific world journal, 2014

4. Regenerative Endodontic: A Paradigm Shift in Clinical Endodontics manoj kumar pulyodan , sunil paramel mohan , dhanya valsan , namitha divakar , shabna moyin , shamsheer thayyil J Pharm Bioallied Sci 2020
5. Repair and regeneration in endodontics. Lin LM, Rosenberg PA., Int Endod J. 2011
6. Vital pulp therapy-current progress of dental pulp regeneration and revascularization. Zhang W, Yelick PC, Int J Dent., 2010
7. Recommendations for using regenerative endodontic procedures in permanent immature traumatized teeth. Garcia-Godoy F, Murray PE Dent Traumatol. 2012
8. Regenerative endodontics: a review of current status and a call for action. Murray PE, Garcia-Godoy F, Hargreaves KM. J Endod. 2007
9. Regenerative endodontics. In: Hargreaves KM, Law AS Hargreaves KM, Cohen S, editors. Cohen's pathways of the pulp. 10th ed. St. Louis, MO: Mosby Elsevier; 2011.
10. The role of blood clot in endodontic therapy: An experimental histologic study. Acta Odontol Scand. 1961
11. Root growth and apical repair subsequent to pulpal necrosis in children. Rule DC, Winter GB Br Dent J. 1966
12. Induced apical closure of immature pulpless teeth in monkeys Ham JW, Patterson WW, Mitchell DF.. Oral Surg Oral Med Oral Pathol. 1972/
13. Revascularization of a tooth with apical periodontitis and a sinus tract Iwaya S, Ikawa M, Dent Traumatol, 2001
14. Revascularization of immature permanent teeth with apical periodontitis: New treatment protocol Banchs F, Trope M J Endod. 2004
15. Pulp revascularization - An evolving concept: A review Rohit Pannu, International Journal of Applied Dental Sciences 2017
16. Pulp Revascularization: A Review ,Patil Anand N, Karkare Swati R ,Damade Yogesh, Puri Juhi, Patil Saylee , International Journal of Medical Science and Dental Research 2020
17. Regenerative endodontics: a comprehensive review S. G. Kim , M. Malek , A. Sigurdsson , L. M. Lin & B. Kahler, Int Endod J 2018
18. Disinfection of immature teeth with a triple antibiotic paste. Windley W, Teixeira F, Levin L, Sigurdsson A, Trope M Journal of Endodontics. 2005
19. Review of current concepts of revascularization/revitalization Tugba Bezgin, Hayriye S€onmez, , Dent Traumatol, 2015

20. A review of regenerative endodontics
gözde kotan betül aycaç alim , dental and medical journal,2020

21Expert consensus on regenerative endodontic procedures review article
Xi Wei , Maobin Yang, Lin Yue, Dingming Huang, Xuedong Zhou, Xiaoyan Wang, Qi Zhang,
Lihong Qiu, Zhengwei Huang, International Journal of Oral Science ,2022

22. AAE Clinical Considerations for a Regenerative Procedure. Revised 5/18/2021

23. Review Regenerative Endodontics as the Future Treatment of Immature Permanent Teeth
Justyna Zbanska , Katarzyna Herman , Piotr Kuropka ,Maciej Dobrzy, journal of Appl. Sci.
2021

24. Phytic acid: an alternative root canal chelating agent. Nassar M, Hiraishi N, Tamura Y,
Otsuki M, Aoki K, Tagami J Endod. 2015

25 Pulp revascularization of necrotic bilateral bicuspid using a modified novel technique to
eliminate potential coronal discoloration: a case report, K. Reynolds, J. D. Johnson, and N.
Cohenca, International Endodontic Journal, 2009

26. “Direct effect of intracanal medicaments on survival of stem cells of the apical papilla,”
Ruparel, F. Teixeira, R. Ferraz, Diogenes Journal of Endodontics, 2012

27. Management of permanent teeth with necrotic pulps and open apices according to the
stage of root development Journal of Clinical and Experimental Dentistry 2017.