

Amebic pleurisy secondary to a liver abscess: A case report

Abstract

We report a case of pleural amoebiasis, diagnosed on the basis of radioclinical findings and positive amoebic serology. Amebic pleuropulmonary disease is the most frequent extra-intestinal expression of amoebiasis after liver disease. A 71-year-old male of rural origin, with no recent tuberculosis contagion, who presented purulent pleurisy with a dysenteric syndrome. The patient was treated by antibiotic and pleural decortication under U-VATS. Serological testing and radiological examination will be more useful in the early detection of cases of Entamoeba histolytica infection. The medical treatment based on a combination of a tissue amoebicide (Metronidazole, etc.) and a contact amoebicide (Hydroxyquinoline, etc.). Surgery may be considered when purulent drainage does not show improvement in the patient's condition

Keywords : pleural amoebiasis, parasitosis, Entamoeba histolytica, pleurisy, dysenteric syndrome, iatrogenic pneumothorax, serology, amoebicide

Introduction :

Amoebiasis is an infection caused by the parasite Entamoeba histolytica with or without clinical manifestations. Currently, it is estimated that 40–50 million people suffer from amoebiasis in developing countries and about 40,000 people died from amoebiasis(1),(12,13,14) Amebic pleuropulmonary disease is the most frequent extra-intestinal expression of amoebiasis after liver disease (2). We report a case of pleural amoebiasis, diagnosed on the basis of radioclinical findings and positive amoebic serology.

Case presentation :

A 71-year-old male of rural origin, smoker with 4 smokes and 40 years' abstinence, with no recent tuberculosis contagion, who presented with a dysenteric syndrome 2 months prior to admission consisting of bloody mucopurulent diarrhoea and abdominal pain . The evolution was marked 2 weeks after this episode, by the appearance of a right chest pain with a side stitch, dyspnoea, with feverish sensations, and a weight loss of 5kg. The chest

X-ray showed a right pleural opacity (fig1) suggestive of pleurisy. The patient was admitted to hospital for 5 days with purulent right pleurisy, where he underwent several pleural evacuations and was put on injectable dual antibiotic therapy with metronidazole and ceftriaxone. When the clinical and radiological signs did not regress, he was transferred to the Pneumology Department for purulent right pleurisy complicated by iatrogenic pneumothorax. Clinical examination revealed a right mixed effusion syndrome. The chest X-ray showed a hydroaeric image occupying the entire right hemithorax (fig 2). Pleural puncture yielded thick purulent fluid, which tested negative for amoebae and common germs. A thoracic and abdominal CT scan confirmed the presence of a watery effusion in the right pleural cavity, associated with two collections in the liver and above the liver (fig 3). Flexible bronchoscopy revealed no abnormalities. Amebic serology was positive by indirect haemagglutination (HAI). Parasitological examination of the stools was negative, as was coproculture. The blood count showed a hyperleukocytosis with a predominance of neutrophils, and the CRP was elevated. The patient was started on Combined antibiotic therapy (Amoxicillin clavulanic acid 3g/d, Ciprofloxacin 1g/day and Metronidazole 1.5g/day for 15 days) with chest drainage. When drainage failed (fig 4), the patient underwent pleural decortication under U-VATS. The surgical exploration revealed a right lung totally adherent to the wall with an upwardly retracted diaphragm, all surrounded by pachypleuritis. The clinical, radiological and biological evolution was good (fig 5). Overall, this was a case of hepatic and pleural amebiasis complicated by iatrogenic pneumothorax.

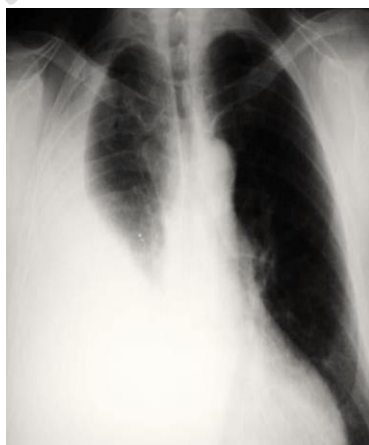

Figure 1: Chest X-ray showing a pleural opacity

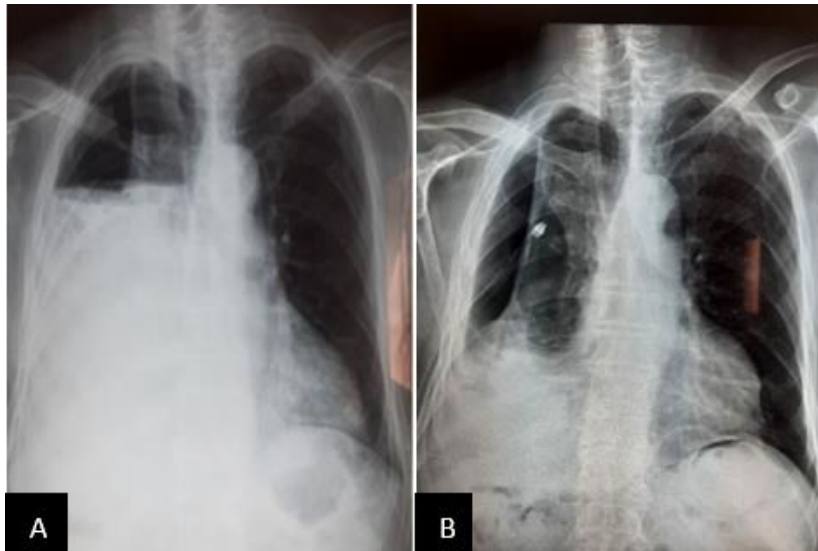


Figure 2 : Chest X-ray showing a hydroaeric image occupying the whole of the right hemithorax (A: Pyopneumothorax before chest drainage; B: after medical chest drainage).

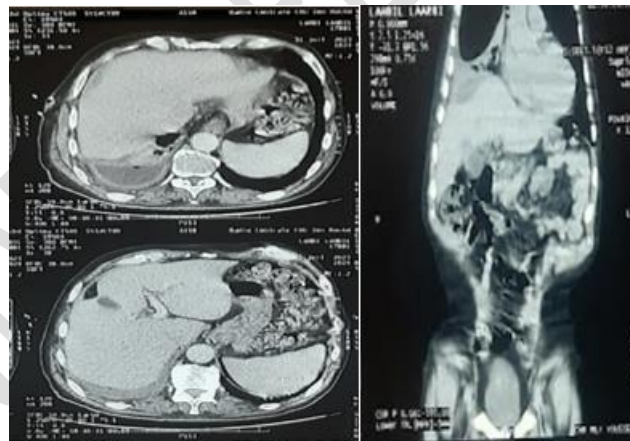


Figure 3: Abdominal scan showing two collections in the liver and above the liver

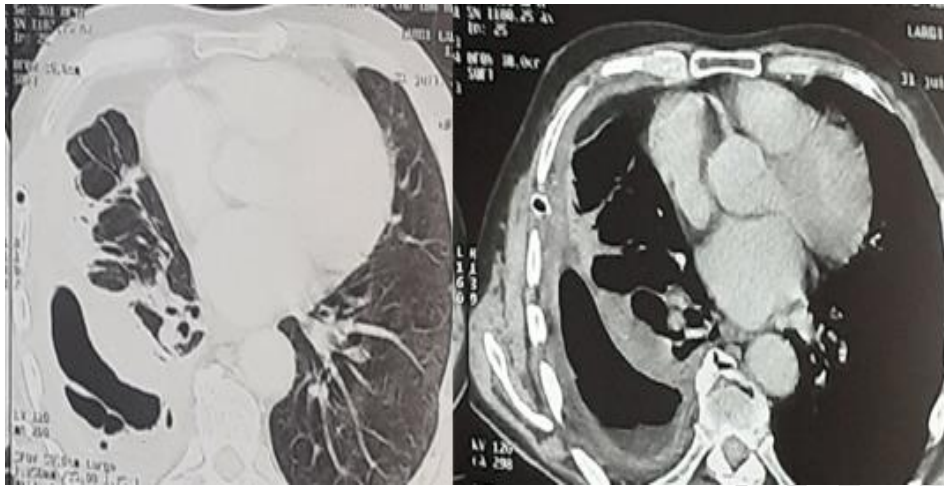


Figure 4: Chest CT scan after unsuccessful medical thoracic drainage showing an encysted pyopneumothorax.

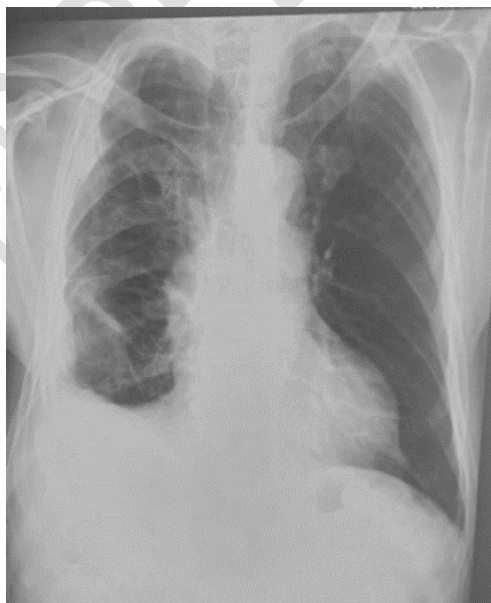


Figure 5: Chest X-ray after surgical treatment

Discussion :

Amoebiasis is a cosmopolitan parasitosis, the second most common parasitic infection in the world after malaria [2]. It is particularly prevalent in countries where hygiene conditions are poor. The pleuropulmonary form is the most common after colonic and hepatic involvement. It complicates 5 to 35% of liver abscesses, which explains the predominance of right thoracic sites. Purely pulmonary amoebiasis remains rare, even in endemic areas [3, 4]. Contamination is mainly transphrenic by contiguity through the diaphragm via the lymphatic system, but also vascular, either from a liver abscess via the subhepatic veins, or by migration of amoebae into the inferior vena cava from the colon via the inferior haemorrhoidal vein [5]. Inhalation of *Entamoeba histolytica* (*E. histolytica*) cysts or trophozoites is a more hypothetical form of contamination [6]. The pulmonary clinical forms of amoebiasis can be extremely varied: non-abscessed or abscessed pneumonia, pleurisy, tracheobronchial fistula, pulmonary embolism (due to thrombus of the suprahepatic veins compressed by an abscess) [5]. Amebic pleurisy, as described in our case, most often occurs on the right, resulting in an acute septic state with impairment of general condition. Amebic pleurisy may be complicated by pyothorax or pyopneumothorax. More rarely, pyothorax may occur on the left, complicating an abscess in the left lobe of the liver. **Massive pleural empyemas can be associated with a mediastinal shift and tension hydrothorax. In severe cases, sepsis, shock, respiratory failure and death may result [7].** Radiologically, an effusion from the large pleural cavity or encysted pleurisy may be seen. Pleural puncture yields a chocolate-coloured or purulent fluid, but trophozoites are rarely found. In our case, purulent pleurisy was found. Pleural fluid is routinely cultured, as bacterial superinfection is common. Serological tests are of immense diagnostic value. At least 2 of the following serological techniques must be combined: agglutination, indirect haemagglutination, ELISA and indirect immunofluorescence. Serology should be repeated at 10 days if the initial result is negative [8]. Conversely, amoebic serology should be requested in the case of purulent pleurisy that does not resolve despite treatment [9]. PCR testing for *E. histolytica* DNA in puncture fluid and sputum can be a sensitive and specific method [6,10]. Treatment of amoebiasis is primarily medical, based on a combination of a tissue amoebicide (Metronidazole, etc.) and a contact amoebicide (Hydroxyquinoline, etc.) [5]. Surgical treatment is reserved for drainage of suppurated cavities and treatment of sequelae (chronic abscesses, pachypleuritis, pleurobronchial fistulas, etc.) [11]. Respiratory physiotherapy is essential and may need to be continued for several months. **The high mortality**

of amoebiasis is caused by socioeconomic factors, age, malnutrition, late diagnosis, and inadequate treatment [1]. . Individual and collective prevention is essential, based on compliance with hygiene measures and the fight against faecal peril [8].

Conclusion :

Considering the prevalence of amoebiasis in developing countries, pleuropulmonary amoebiasis should be suspected in any respiratory pathology of infectious origin involving the right lung base. Serological tests, due to their high specificity, represent a valuable means of diagnosis and monitoring. Early therapeutic management generally leads to a favorable outcome without significant sequelae.

Consent

As per international standards or university standards, patient(s) written consent has been collected and preserved by the author(s).

Disclaimer (Artificial intelligence)

Option 1:

Author(s) hereby declare that NO generative AI technologies such as Large Language Models (ChatGPT, COPILOT, etc) and text-to-image generators have been used during writing or editing of manuscripts.

Option 2:

Author(s) hereby declare that generative AI technologies such as Large Language Models, etc have been used during writing or editing of manuscripts. This explanation will include list the name, version, model, and source of the generative AI technology and as well as the all input prompts provided to a generative AI technology

Details of the AI usage are given below:

- 1.
- 2.
- 3.

References

- 1 Putri Mega Juwita and Resti Yudhawati. Secondary pleuropulmonary amoebiasis due to liver abscess rupture: A complication case report in low resource setting . *Int J Surg Case Rep.* 2021 ; 85 : 106231.
- 2 Samuel L Stanley Jr: Amoebiasis. *Lancet.* 2003 Mar 22;361(9362):1025-34
- 3 Ayadi H, Rekik K, Ayoub K: Bilateral excavated nodular pneumonia: the amoeba responsible? *Rev Pneumol Clin* 2001; 57:434-7.
- 4 Koffi N, Ngom A, Kouasi B, Aka-Danguy E: Pleuropulmonary amoebiasis. Contribution to the study in endemic areas. *Medicine and the Armed Forces* 1997; 25:473-7.
- 5 Mbaye PS, Koffi N, Camara P, Burgel PR, Hovette P, Klotz F: Pleuropulmonary manifestations of amoebiasis. *Rev Pneumol Clin* 1998; 54:346-52.
- 6 Shamsuzzaman SM, Hashiguchi Y :Thoracic amebiasis. *Clin Chest Med* 2002; 23:479-92.
- 7 Chitra Lal, J T Huggins, SA. Sahn, Parasitic Diseases of the Pleura, *Am J Med Sci.* Mai 2013;345(5):385-9.
- 8 P.-L. Massoué; isolated pleural amoebiasis. *Rev Mal Respir* 2004; 21:587-90
- 9 Teramoto K, Yamashita N, Kuwabara M, Hanawa T, Matsui T, Matsubara Y: An amebic lung abscess: report of a case. *Surg Today* 2001; 31:820-2.
- 10 Vreden SG, Visser LG, Verweij JJ, Blotkamp J, Stuijver PC, Aguirre A, Polderman AM: Outbreak of amebiasis in a family in the Netherlands. *Clin Infect Dis* 2000; 31:1101-4.
- 11 Dubut F, Benhamou D, Kouziaeff N, Muir JF: Entamoeba histolytica respiratory infection. *Rev Mal Respir* 2000; 17:878-80.
12. Jaabouti G, Cherrat A, Bencchakroun S, Mahraoui C, Hafidi NE. Hemoptysis Revealing a Pulmonary Arteriovenous Fistula: A Case Report. *Asian J. Med. Health.* [Internet]. 2023 Jun. 23 [cited 2024 Jun. 2];21(9):73-9. Available from: <https://journalajmah.com/index.php/AJMAH/article/view/859>
13. Elbashir SAH, Abakar AD, Nour BYM. Detection of Pulmonary Tuberculosis by Gene Xpert Method among HIV Patient in ART Center, Gadarif State, Sudan. *Int. J. Trop. Dis. Health.* [Internet]. 2023 Feb. 13 [cited 2024 Jun. 2];44(3):1-8. Available from: <https://journalijtdh.com/index.php/IJTDH/article/view/1390>

14. Juwita PM, Yudhawati R. Secondary pleuropulmonary amoebiasis due to liver abscess rupture: A complication case report in low resource setting. *International Journal of Surgery Case Reports*. 2021 Aug 1;85:106231.

UNDER PEER REVIEW