

UNUSUAL LOCATION OF **SYNOVIALSARCOMA** OF THE ABDOMINAL WALL: ABOUT A CASE AND REVIEW OF THE LITERATURE.

Comment [DM1]: Spelling mistake

ABSTRACT

Comment [DM2]: Spelling mistake

Abdominal **synoviosarcoma** is a rare and aggressive tumor that presents diagnostic and treatment challenges, as well as a difficult to predict prognosis. In this work we present the case of a 38-year-old patient who underwent surgery due to a cystic tumor of the left anterior abdominal wall. Medical imaging, particularly abdominal CT, revealed tissue heterogeneity which leads to compression of the rectus abdominis muscle as well as the left external oblique muscle. A large single-piece surgical resection of the tumor was performed on the patient. A biphasic synoviosarcoma of the abdominal wall was confirmed by pathological examination.

Comment [DM3]: Spelling mistake

Adjuvant chemotherapy was administered to the patient and after approximately 2 years he developed a recurrence of his disease which required appropriate management. It is important to discuss synoviosarcoma of the abdominal wall because of its rarity and the nonspecificity of its clinical symptoms. Its precise cause remains unknown; However, some studies suggest that particular genetic mutations may contribute to the development of this tumor. Its therapy is mainly based on surgery with adjuvant chemotherapy and/or radiotherapy which can improve the prognosis.

KEYWORDS: Synoviosarcoma; Abdominal wall ; Surgery ; Chemotherapy; Radiotherapy.

INTRODUCTION

Synoviosarcoma was first described in 1893 and is a primary malignant mesenchymal tumor that has the same histological characteristics of synovial tissue. It represents 2.5 to 10.5% of all primary soft tissue cancers [1,2].

Synoviosarcoma is considered to originate from the synovium due to its essentially paraarticular location of this neoplasm and the histological similarities with the synovial tissue have led to synoviosarcoma being considered to originate from the synovium [3]. In reality, it does not come from synovial tissue but is composed of undifferentiated mesenchymal cells.

Location in the abdomen remains very rare. Synoviosarcoma of the abdominal wall is a rare and aggressive tumor that is distinguished by rapid growth, local invasion, high risk of recurrence and metastasis.

Functional symptoms, clinical examination and radiological investigations are of little help in the diagnosis.

However, recent advances in imaging, structural studies and immunohistochemistry techniques provide a new perspective on these tumors and open the way to better prognostic and therapeutic management.

Treatment is mainly surgical combined with chemotherapy and sometimes even radiotherapy.

Initial treatment is fundamental because it determines the patient's quality of life and overall survival. Therapeutic planning must be taken within a multidisciplinary team.

In this work, we report the case of a patient followed for synoviosarcoma of the abdominal wall while trying to clarify the diagnostic and therapeutic difficulties posed by this pathology.

Case présentation :

This is a 38-year-old patient with no previous history.

For 1 year, the patient had had a progressive increase in the volume of the abdomen, with a feeling of heaviness, accompanied by poorly systematized abdominal pain with unquantified weight loss and deterioration in general condition.

Abdominal examination finds a hard mass, measuring 10 cm, mobile in relation to the superficial plane and fixed in relation to the deep plane.

An abdominal ultrasound performed revealed the presence of a mass in the left anterolateral abdominal wall of cystic consistency, initially suggesting a hydatid cyst.

Hydatid serology came back positive with threshold 1/80 in addition to a high CRP of 50 g/l

Abdominopelvic CT (figure 1) which found a parietal mass of the anterolateral abdominal wall, multipartitioned cyst with well-defined contours, measuring approximately 70x85x96 mm, it caused compression on the left external oblique muscle; and internally, it represses the internal oblique and transverse muscles. Below, it comes into contact with the left iliac crest without lysis or condensation opposite. No secondary locations.

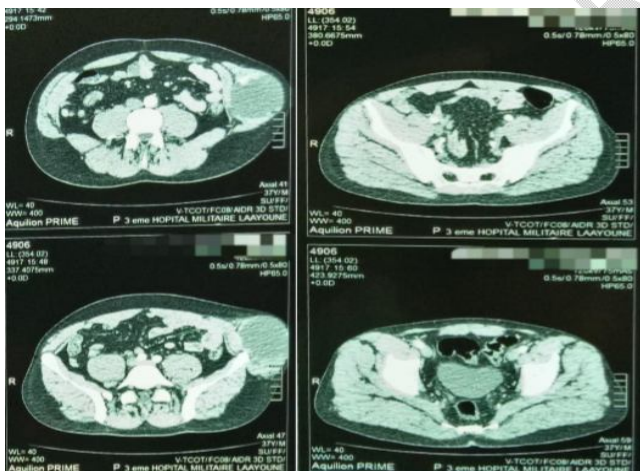


Figure 1: Axial CT section showing the mass

Given the notion of rural origin, the positive serology, and the cystic appearance on the imaging, we made the diagnosis of hydatid cyst of the abdominal wall.

Given the young age of the patient, the size of the mass and the absence of distant localization, primary surgery was indicated.

The patient benefited from a one-piece resection, removing a margin of healthy tissue in all directions (on the rectus abdominis muscle and the oblique muscles but was limited downwards by the periosteum of the iliac crest). (Figure 2)

We reinforced with a 30 x 20 cm bifacial plate fixed by 4 cardinal points and after checking hemostasis, we drain the residual cavity with a redon drain.

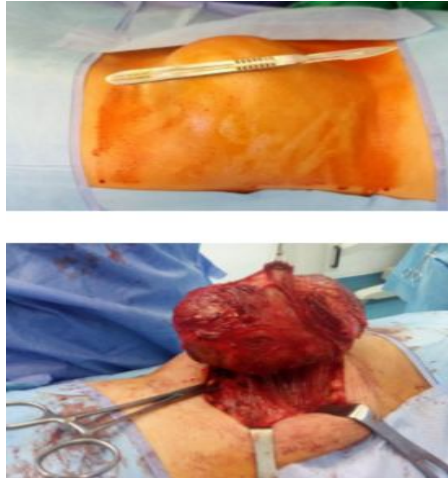


Figure 2: Image showing the intraoperative appearance of the tumor

The immediate post-operative consequences were simple, marked by resumption of transit on the 1st day, allowing feeding with discharge on the 5th day.

Pathological study: Histological appearance and immunohistochemical profile in favor of a biphasic synovial sarcoma, measuring 10x9x5 cm. Histological grade according to FNCLCC: II (tumor differentiation: 3; mitotic index: 2; tumor necrosis: 0)

File discussed in multidisciplinary consultation meeting and given grade 2 with the very high risk of recurrence, chemotherapy based on doxorubicin was adapted at a rate of 2 sessions per month, for 6 months.

The patient was followed closely with a progressive worsening of his general condition occurring during the first year after surgery with signs of respiratory discomfort related to moderate pleurisy which responded poorly to drainage and whose Pleural biopsy confirmed pleural recurrence of synovial sarcoma.

This pleurisy was complicated by a ruptured left lung abscess requiring surgical repair which was unfortunately complicated by the occurrence of septic shock with the death of the patient.

DISCUSSION

Synovial sarcoma is a rare primary malignant mesenchymal tumor, which ranks 4th among soft tissue sarcomas and represents 2.5 – 10.5% of all primary tissue cancers with an incidence of around 2.75/100,000/year [1].

Synovial sarcoma occurs mainly in the extremities near the large joints, legs, arms and knees, with a percentage of 85% to 95%.

Primary abdominal wall synovial sarcoma has been mentioned as a rare case in several reports; Only 47 cases of synovial sarcoma of the anterior abdominal wall have been reported in the English literature and only one of these cases concerned an adolescent [13,14], which shows the interest of our observation.

Comment [DM4]: Typing mistake.

Synovial sarcoma can occur at any age but is most common in young adults. the age of onset varies between 15 and 40 years [1]. A slight male predominance (M/F sex ratio: 1.2) has been described by certain authors [4].

In our case, the patient's age at the time of diagnosis was 38 years, and he is male.

The clinical symptoms (especially the signs of compression) depend on the site and the size of the tumor. Metastases occur in the first 2 to 5 years, they are present in 16-25% of cases, particularly in the lungs, and less frequently in the lymph nodes and bones. For our patient the recurrence was early at a year and a half probably due to the damage to the periosteum.

CT scanning is more sensitive than abdominal ultrasound because it can detect calcifications as well as necrosis and hemorrhagic areas. The most common CT appearance of abdominal wall synovial sarcoma is a heterogeneous soft tissue mass with attenuation equal to or slightly less than that of muscle.

An advantage over CT is the importance of healthy and tumor tissue contrast, thus the possibility of obtaining multi-planar images with much higher resolution than CT construction images.

Histological study after a biopsy or surgical resection represents the only way to confirm the diagnosis of synovial sarcoma [5].

The treatment of choice is extensive local excision with a negative surgical margin (wide margins of normal tissue) to minimize the chance of recurrence. followed by adjuvant radiotherapy (external radiotherapy/brachytherapy) and/or chemotherapy (doxorubicin).

Local recurrence is observed in 30 to 50% of cases and is linked to inadequate margins and aggressive histopathology [6]. Singer et al reported an overall survival of 67% with negative microscopic margins, compared to 49% for positive margins [7].

Studies have shown limited survival benefit for high-risk patients following adjuvant chemotherapy [8,9].

Radiotherapy significantly reduces the risk of local recurrence, particularly for high-grade sarcomas. However, it should not be administered after inadequate surgical intervention [10,11,12,13].

The 5-year survival rate is 36% to 76% for intermediate to high grade synovial sarcoma. Positive surgical margins, invasiveness, metastasis, poor differentiation, and high histologic grades are indicative of an advanced prognosis in synovial sarcoma. Size <5 cm, location at the distal end, age <15 years, monophasic synovial sarcoma, and SYT-SSX2 gene fusion have better prognostic results. [14]

CONCLUSION

Synovial sarcoma of the abdominal wall is rarely observed in practice. The exact cause of synovial sarcoma of the abdominal wall is not clearly defined.

Clinical symptoms are not reliable in making the diagnosis of a synovial sarcoma of the abdominal wall because it can be confused with a benign condition, which delays treatment.

The diagnosis is based on an imaging assessment, mainly composed of CT and abdominal MRI, and confirmation is based on histology.

Treatment is based on extensive surgical excision with healthy margins to avoid recurrence. In some cases, chemotherapy or radiotherapy may be used before or after surgery to reduce the size of the

Comment [DM5]: Spelling mistake

tumor or limit its spread. In locally advanced synovial sarcomas, it is recommended to consider neoadjuvant chemotherapy before surgery.

Abdominal wall synovial sarcoma is often associated with a poor prognosis due to its aggressiveness and propensity for local recurrence and metastases, often the latter occurring within 2 to 5 years following initial treatment.

REFERENCES

- [1] Murphey MD, Gibson MS, Jennings BT, Crespo-Rodríguez AM, Fanburg-Smith J, Gajewski DA (2006) Imaging of synovial sarcoma with radiologic-pathologic correlation. *Radiographics* 26(5): 1543–1565.
- [2] Professor Mustapha Mahfoud. Bone cancer and malignant tumors of the limbs, 2009
- [3] RUSSEL W, COHEN J, ENZINGER et AL.: A Clinical and pathological staging system for soft tissue sarcomas, *cancer*; 1977; 40; 1562-1570.
- [4] Deshmukh R, Mankin HJ, Singer S. Synovial sarcoma: the importance of size and location for survival. *Clin Orthop Relat Res* 2004;419:155–161.
- [5] Surgical Clinic C, Mohamed V University, Rabat, Morocco. et al. "INTRA-ABDOMINAL SYNOVIALSARCOMA ABOUT A CASE AND REVIEW OF THE LITERATURE", *Int. J. Adv. Res.*, vol. 9, no. 08, p. 89–95, août 2021, doi: 10.21474/IJAR01/13234.
- [6] Stojadinovic A, Hoos A, Karpoff HM, et al. (2001) Soft tissue sarcomas of the abdominal wall; analysis of disease patterns and treatment. *Arch Surg* 136:70–7.
- [7] Singer S, Corson JM, Demetri GD, et al. (1995) Prognostic factors predictive for survival of truncal and retroperitoneal soft tissue sarcoma. *Ann Surg* 221:185–195.
- [8] ANTOGNONI P; CERIZZAL; VAVASSORI V, ET AL. : Postoperative radiation therapy for adult soft tissue sarcomas: a retrospective study. *Ann Oncol*;1992; 3; 103-106.
- [9] GHERLINZONIF, PICCIP, DE CRISTOFARO R et AL.: Late result of a randomized trial for the treatment of soft tissue sarcomas (STS) of the extremities in adult patients (abstract). *ProcASCO*, 1993, 12.
- [10] Mibles, G. KAMTOR, H. Laharie, P. Lagarde: Adjuvant radiotherapy for soft tissue sarcomas of the limbs-cancer/Radiotherapy 9 (2005).
- [11] ANTOGNONI P; CERIZZAL; VAVASSORI V, ET AL. : Postoperative radiation therapy for adult soft tissue sarcomas: a retrospective study. *Ann Oncol*;1992; 3; 103-106. 95
- [12] ASHBY A; AGO CT; HARMER CL. : Hypo fractionated radiotherapy for sarcomas. *Int J Radiat Oncol Bio Phys*, 1986. 12.13-17.
- [13] GHERLINZONIF, PICCIP, DE CRISTOFARO R et AL.: Late result of a randomized trial for the treatment of soft tissue sarcomas (STS) of the extremities in adult patients (abstract). *ProcASCO*, 1993, 12.
- [14] SM Khaladkar and AM Waghmode, "Synovial Sarcoma of Anterior Abdominal Wall," *Indian J. Med. Paediatr. Oncol.*, vol. 41, no. 02, p. 269-272, March 2020, doi: 10.4103/ijmpo.ijmpo_143_18

UNDER PEER REVIEW

