

## **Case report**

# **Extra-Gastrointestinal Stromal Tumors (EGISTs) : A case report and review of literature**

### **Abstract**

Gastrointestinal stromal tumor (GIST) represent less than 1% of all gastro intestinal stromal tumors (GISTS) and are main in the stomach and small intestine. Mesenteric GIST is rarely reported as they constitute 5 to 10% of GIST. It originates from the intestinal cells of Cajal. GISTS that develops outside the gastrointestinal tract and have no connection with the intestinal wall or serosal surface of the gastrointestinal tubular organs.

An extra-intestinal gastrointestinal stromal tumors (EGITS) they have similar morphological and immune-histological characteristics as GISTS. Surgical resection is the main stay of treatment. Post-operative use to imatinib, delay the recurrence and improves to survival rate.

We report a rare case of mesenteric extra-gastrointestinal stromal tumor (EGITS) in a 50 years old female and discuss the course of clinical presentation, diagnosis and management.

### **Key words**

Gastrointestinal stromal tumor, Mesenteric GIST, Surgical resection, imatinib

### **Introduction**

"Gastrointestinal stromal tumors (GISTs) are mesenchymal tumors of the gastrointestinal tract that arise from the interstitial cells of Cajal. The term GIST was coined by Mazur and Clark in 1983. The annual incidence of GISTs is approximately 15 cases per million people, and they are mostly seen in patients older than 50 years, with a male-to-female ratio of approximately 1:1. Complete surgical resection offers a better chance of survival. Imatinib, a tyrosine kinase inhibitor, plays a significant role postoperatively and is associated with a good prognosis". [1,3,4,11,12,13]

"Extra-gastrointestinal stromal tumors (EGISTs) are extremely rare, accounting for only 5% of all GISTs and less than 0.05% of all gastrointestinal tumors. Both GISTs and EGISTs share the same molecular biology, histology, and immunohistochemical behaviour. Immunohistochemical tests for CD117 (C-kit protein) and CD34 are essential for diagnosis. Recommended imaging studies include CT, MRI, and PET scans. The standard treatment for localized, resectable, and non-metastatic GISTs and EGISTs is surgery. Recognizing the rarity of EGIST cases is crucial. Several primary sites of EGISTs have been reported, including the mesentery, omentum, peritoneum, pancreas, and retroperitoneum. A total of 114 cases of mesenteric GISTs have been documented in the literature". [2,4,6]

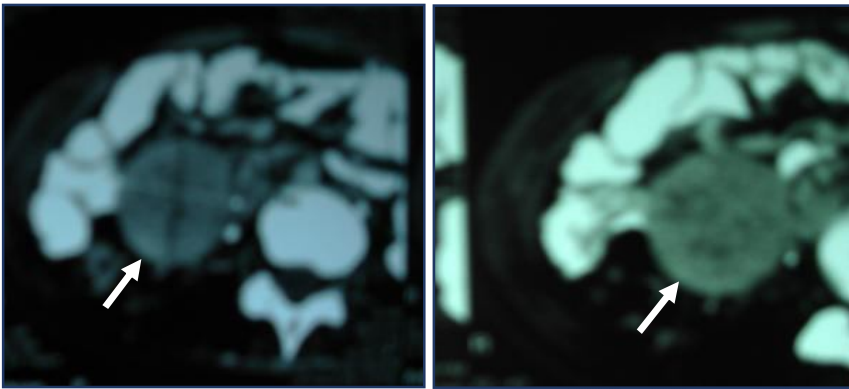
### **Case Report**

We present the case of a 50-year-old female admitted to our centre on 20/10/2018 with complaints of an abdominal lump and pain. On clinical examination, all vital parameters were within normal limits. Abdominal examination revealed a well-defined, tender, right-sided abdominal mass that was freely mobile. Blood tests, including a full blood count, urea and electrolyte levels, and liver function tests, were normal. An abdominal ultrasonography reported a 4x3 cm mass with a solid

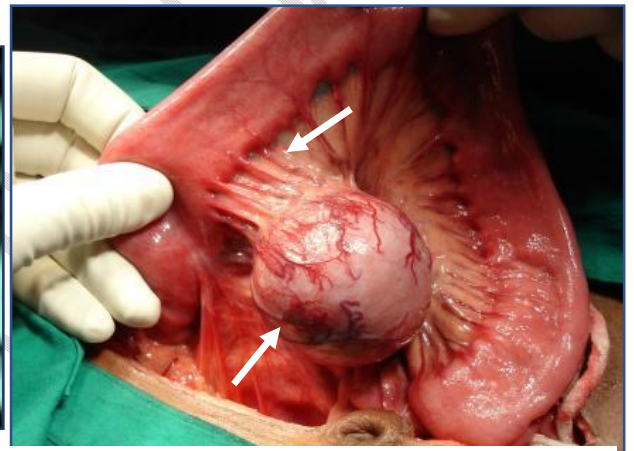
appearance and well-defined wall. CT scan confirmed a large, well-defined 4x3 cm mass with heterogeneous densities and areas of necrosis, diagnosed as a mesenteric mass.

A surgical approach was decided upon, involving an open laparotomy through a midline incision. Intraoperatively, the tumor was found to be arising from the small bowel mesentery and was closely related to small bowel loops. The tumor was free, spherical in shape, 4x3 cm in size, with smooth margins and no adhesions to surrounding structures. The tumor was localized, so complete surgical resection with anastomosis of the small bowel was performed.

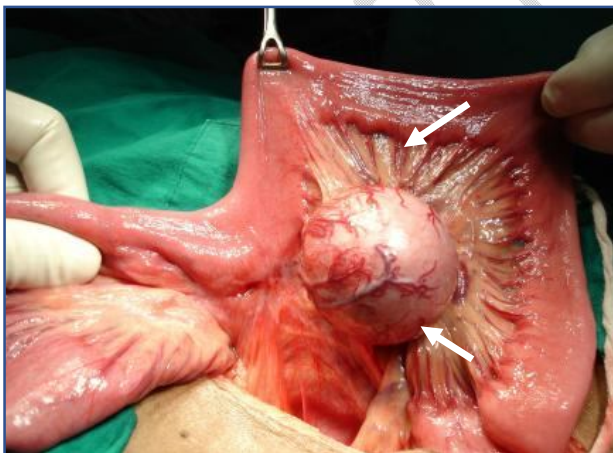
Pathological examination of the specimen revealed a 4x3 cm spherical mass with smooth margins. Histopathologically, the tumor showed spindle cells with a low mitotic rate, and the CD117 antigen test was positive for GIST. The patient was referred to a cancer centre, and Post-operative use of imatinib delays recurrence and improves survival rate. After a follow-up period of 5 years postoperatively, the patient is healthy with no recurrence of the disease. [ Fig 1-8]



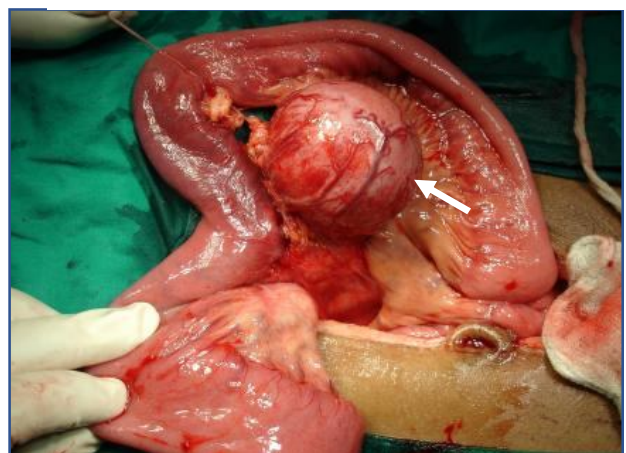**Fig-1** CT abdomen showing a large, solid heterogeneous well defined mass of size 4x3 cm



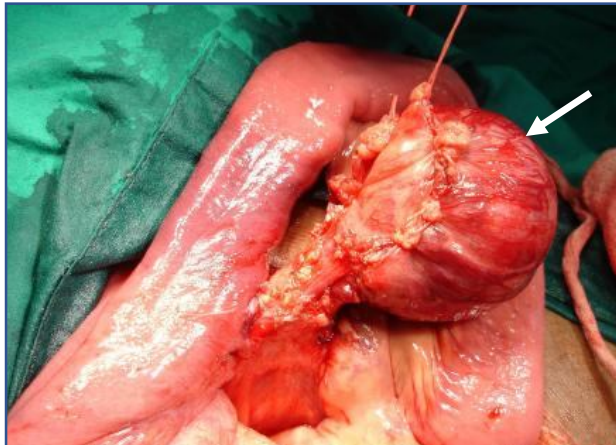
**Fig-2**Intraoperative photograph showing mesenteric GIST



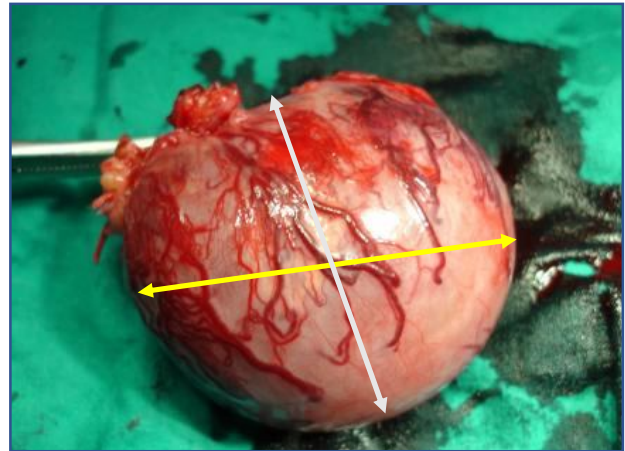
**Fig-3**Intraoperative photograph showing mesenteric GIST of size 4x3 cm



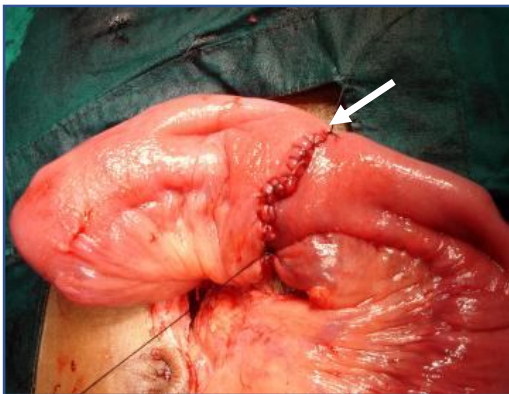
**Fig-4**Intraoperative photograph showing mesenteric GIST with surgical resection



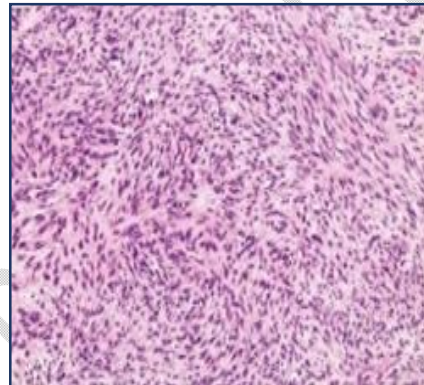
**Fig-5**Intraoperative photograph showing mesenteric GIST with surgical resection



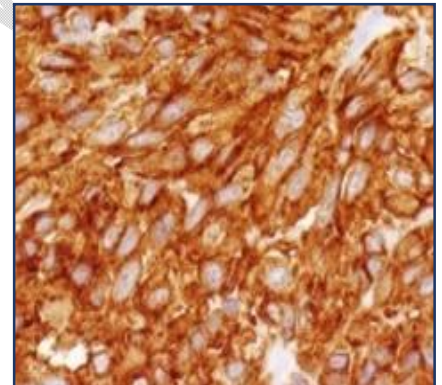
**Fig-6**Gross specimen of Mesenteric GIST of size 4x3 cm Spherical mass with regular margins



**Fig7 -** Intraoperative photographs showing ilio-ileal anastomosis



**Fig 8-** Spindle cell GIST with low mitosis



**Fig 9-** Spindle cell GIST positive for CD 117 antigen test

### Discussion and Review of Literature

“Extra-gastrointestinal GISTs (EGISTs) are GISTs that have no connection with the intestinal wall or the serosal surface of gastrointestinal tubular organs. These tumors are extremely rare, accounting for only 5% of all GISTs”. [1,2]

“Miettinen et al were the first to describe EGISTs in 1995, they reported a series of omental and mesenteric stromal tumor positive for CD 117. EGISTs similar to GISTs originate from intestinal cells of Cajal (ICC). ICC are pacemaker cells that control the peristalsis in the gastrointestinal tract. EGIST mostly occur intra abdominally and in the retroperitoneum”. [4,6,7]

“ Clinically, symptoms vary depending on the location of the EGIST. Patients may be asymptomatic and incidentally diagnosed during routine examination for other medical conditions or may have typical symptoms such as abdominal pain, abdominal mass or distension feng etal reported the above symptoms. Diagnosis is through tissue histopathology with immunohistochemical standing CD 117 positive test. Feng et al examined the clinicopathological features and prognosis of

mesenteric GISTS in 114 mesenteric GIST. Histopathological EGIST, express markers such a CD 34, C-kit, CD 117, DOG -1 and PKC-0". [4,6,8]

"Treatment for EGIST depends a staging. For localized tumors, the standard treatment involves complete surgical excision of the tumor along with negative margins. For locality advanced, inoperable or metastasis disease, standard treatment is imatinib, a tyrosine kinage inhibitor". [6,9]

"Mesenteric GISTS have poorer outcomes compared to classical GISTS. Mesenteric GISTS had poor outcomes with fewer survival compare to gastric GISTS. Feng et al noted that tumor size, mitotic activity index, histological type and prognosis of mesenteric GISTS was worse than that of gastric GIST. The study also noted most mesenteric GISTS exceeding 10 cm in diameter, 5/50 HPF in the mitotic index, were high risk with poorer prognosis". [6,7]

"In high risk category patient is recommended follow up with serial CT scan in addition to surgery and targeted therapy approximately 10 years from imatinib therapy. Sunitinib and ponatinib are other option for resistance or partial response to imatinib". [4,10]

### **Conclusion**

Mesenteric GIST (EGIST) is a rare condition. It presents as an abdominal mass and can be mistaken for mesenteric tumors or growths. Large mass more the 5 cm, incomplete resection margins and central necrosis are all poor indices for survival and result in high recurrence.

Ethical Approval:

As per international standards or university standards written ethical approval has been collected and preserved by the author(s).

Consent

As per international standards or university standards, patient(s) written consent has been collected and preserved by the author(s).

### **Disclaimer (Artificial intelligence)**

Option 1:

Author(s) hereby declare that NO generative AI technologies such as Large Language Models (ChatGPT, COPILOT, etc) and text-to-image generators have been used during writing or editing of manuscripts.

Option 2:

Author(s) hereby declare that generative AI technologies such as Large Language Models, etc have been used during writing or editing of manuscripts. This explanation will include the name, version, model, and source of the generative AI technology and as well as all input prompts provided to the generative AI technology

Details of the AI usage are given below:

- 1.
- 2.
- 3.

## References

1. Gregorio Arellano-Gutiérrez, Edwin Leopoldo Maldonado-García, Primary extra-gastrointestinal stromal tumor (EGIST) of the mesentery: Case report and review of literature, *Annals of Medicine and Surgery*, <https://doi.org/10.1016/j.amsu.2020.11.020>.
2. Ramani AS, Huske G, Noronha FP. A Rare Case of Mesenteric Gastrointestinal Stromal Tumor Presenting as Acute Abdomen. *Niger J Surg*. 2017 Jan-Jun;23(1):71-72. doi: 10.4103/1117-6806.199960. PMID: 28584517; PMCID: PMC5441222.
3. R., Rajalakshmi & V., Rajakumar. (2022). A case of mesenteric gastro intestinal stromal tumors: a diagnostic dilemma. *International Surgery Journal*. 9. 2076. 10.18203/2349-2902.isj20223176.
4. A.K Das<sup>1</sup> , Tarjina Begum<sup>2</sup> , Bedanta Barman<sup>3</sup> , Prajna Anirvan<sup>3</sup>, Mesenteric GIST: A case report, *The Journal of Medical Research* 2018; 4(1): 4-6, Research (medicinearticle.com)
5. Abidoye O, Johnson A (March 12, 2022) Extremely Aggressive Mesenteric Extragastrintestinal Stromal Tumor: A Case Report and Literature Review. *Cureus* 14(3): e23108. doi:10.7759/cureus.23108
6. Feng, F, Feng, B, Liu, S, Liu, Z, Xu, G, Guo, M, Lian, X, Fan, D, & Zhang, H. Clinicopathological features and prognosis of mesenteric gastrointestinal stromal tumor: evaluation of a pooled case series. *Oncotarget* 2017 Jul 11;8(28):46514-46522
7. Gupta, N., Mittal, S., Lal, N. et al. A rare case of primary mesenteric gastrointestinal stromal tumor with metastasis to the cervix uteri. *World J Surg Onc* 5, 137 (2007). <https://doi.org/10.1186/1477-7819-5-137>
8. Tiwari, A. , Choudhary, A. , Khawal, H. , Chaudhary, P. and Arora, M. (2013) Primary Extra-Gastrointestinal Stromal Tumor (GIST) arising from mesentery of small bowel and presenting as abdominal mass: A rare entity. *Open Journal of Gastroenterology*, 3, 267-271. doi: 10.4236/ojgas.2013.35045.
9. Gaillard F, Niknejad M, Knipe H, et al. Gastrointestinal stromal tumor. Reference article, *Radiopaedia.org* (Accessed on 30 May 2024) <https://doi.org/10.53347/rID-6758>
10. Engin, G., Asoglu, O., Kapran, Y. et al. A gastrointestinal stromal tumor with mesenteric and retroperitoneal invasion. *World J Surg Onc* 5, 121 (2007). <https://doi.org/10.1186/1477-7819-5-121>

11. Abood, H. B. A., Albalawi, A. N. D., AlEnazi, H. O., Almuhanha, M. M., Busaad, N. O., Jarad, R. G. A., Alkhamis, M. S., Alsharif, S. M., Alahdal, M. A. S., Alqahtani, D. A. S., Alhakamy, A. R. and Alraqibah, S. A. (2021) "Overview on Gastrointestinal Stromal Tumor; A Review", *Journal of Pharmaceutical Research International*, 33(56B), pp. 29–36. doi: 10.9734/jpri/2021/v33i56B33925.
12. Bhadani, P. P., A. Singh, G. K. Gupta, and K. Parasar. 2022. "An Unusual Appearance of Cystic Gastro Intestinal Stromal Tumor of Small Intestine - A Case Report and Brief Review of Literature". *Journal of Advances in Medicine and Medical Research* 34 (20):282-88. <https://doi.org/10.9734/jammr/2022/v34i2031496>.
13. Caterino, S., Lorenzon, L., Petrucciani, N., Iannicelli, E., Piloizzi, E., Romiti, A., ... & Ziparo, V. (2011). Gastrointestinal stromal tumors: correlation between symptoms at presentation, tumor location and prognostic factors in 47 consecutive patients. *World journal of surgical oncology*, 9, 1-10.

UNDER PEER REVIEW