

EFFICACY OF ASCORBIC ACID ON FRONTAL CORTEX DAMAGE INDUCED BY ALCHOLIC EXTRACT OF *DATURA STRAMONIUM* LEAF IN ADULT MALE WISTAR RATS.

ABSTRACTS

Context

Datura stramonium (DS) is a medicinal plant widely distributed across the globe, including in Nigeria and West Africa. Pharmacological, physiological, and histological studies have demonstrated the neurotoxicity of the plant in animals and humans at high doses. Ascorbic acid is a potent reducing agent and scavenger of free radicals in biological systems.

Aim

This study was undertaken to advance our knowledge of *Datura stramonium* leaf's toxicology and investigate ascorbic acid's efficacy on the frontal cortex damage induced by the alcoholic extract of *Datura stramonium* leaf in adult male Wistar rats.

Settings and Design

Thirty (30) adult male Wistar rats weighing about 120 ± 20 g were divided into six groups (A-F) of five animals each for oral administration over 14 days.

Materials and Methods

- **Group A (Control):** Received only rat feeds and water.
- **Group B:** Received 200 mg/kg alcoholic extract of *Datura stramonium*.
- **Group C:** Received 400 mg/kg alcoholic extract of *Datura stramonium*.
- **Group D:** Received 200 mg/kg body weight alcoholic extract of *Datura stramonium* and 200 mg/kg body weight of Vitamin C.
- **Group E:** Received 400 mg/kg body weight alcoholic extract of *Datura stramonium* and 200 mg/kg body weight of Vitamin C.
- **Group F:** Received 200 mg/kg body weight of Vitamin C. The experimental animals were euthanized, and sections of the frontal cortex of the brain were harvested for histological procedures. The experimental animal weights were obtained.

Statistical Analysis

The data was subjected to a one-way analysis of variance (ANOVA).

Results

Histological observations indicated that the administration of the alcoholic extract of DS leaf in Group C showed degeneration of neurons in the frontal cortex. Groups that received ascorbic acid along with

DS leaf in smaller doses showed no significant changes and had normal neuronal cells and stroma. Changes observed in body weight were not statistically significant at p-value <0.05.

Conclusion

This study suggests that ascorbic acid effectively reduces the neurotoxicity potential of Datura stramonium on the frontal cortex. The DS leaf extract may have neurodegenerative effects at high doses, and precautions should be taken when consuming It, as it may adversely affect and damage neurons in the frontal cortex.

Keywords: *Datura stramonium, Vitamin C, Neurodegeneration, Frontal cortex neuron.*

UNDER PEER REVIEW

1. INTRODUCTION

Medicinal plants are an important source of therapeutic compounds used in treatment of many diseases since ancient times (Singh *et al.*, 2022). Medicinal plants are often used as raw materials for extraction of active ingredients which are used in the synthesis of different drugs and they have demonstrated several pharmacological activities such as anti-inflammation, anti-cancer, anti-allergic, and antimicrobial infection (Sharma *et al.*, 2021; Shakya, 2016).

Medicinal plants such as the leaves, roots, bark, fruit, seeds, and flowers are generally sources of various phytochemicals, some of which are usually responsible for their biological activities and can be structurally optimized and processed into new drugs (Ugboko *et al.*, 2020). It has been reported that the antioxidant properties of phytochemicals may reduce the oxidative stress in the biological system. Phytochemicals reduced risk of numerous human diseases including cardiovascular disease, hepato-renal diseases, diabetes, cancers, and neurodegenerative disease (Shakya, 2016).

Despite their vital role in modern medicine, medicinal plants have served as the primary source of curative drugs since ancient times. Numerous scientific reports published over the past three decades suggest that medicinal plants could serve as a promising alternative to ineffective antibiotics in combating infectious diseases (Abdallah *et al.*, 2023). They are essential resource for human well-being and among them *Datura Stramonium* is one of highly important plant and Its medicinal significance is mainly because of higher amounts of tropane alkaloids and traditionally used throughout the world (Batool *et al.*, 2020).

Datura stramonium is commonly known as Devils Snare, belongs to the Solanaceae (night shade) family. It is also known by the common name Jimson weed. Other common names for *D. stramonium* include thorn apple and moon-flower, it is popularly called GEGEMU OR EWE KAN by the Yoruba

tribe of Nigeria. It is believed the plant has been an exemplary source of folklore medicinal herb known for its mental stimulation and curative properties (Choudhary et al., 2021). Recently, it has been used as narcotic and local anesthetic drug in many societies and in some nations young people use the leaves by smoking for hallucination purpose. Addiction by the youths who are more prone to dangers of smoking and drug abuse use this plant. *Datura Stramonium* plant should only be used therapeutically under the care of knowledgeable health care professionals. The adverse effects can be extremely severe and detrimental. Therefore, even in light of its many beneficial effects, the risk-benefit ratio should always be taken into consideration before the usage (Firdaus et al., 2020).

Datura Stramonium is an important medicinal plant. Traditionally, it has an important medicinal value throughout the world. The leaves and seeds are used in different treatment recipes and in ayurvedic medicine they are used in curing various human ailments which include ulcers, wounds, swellings, fever, asthma and tooth ache (Mohanlall and Ally 2020 ; Sharma *et al.*, 2021).

Internally, it is a CNS depressant, antispasmodic for respiratory tract, and is used in rheumatism, gout, headache, cough and asthma; digestive, anthelmintic, hypnotic, relieves headache due to excessive blood or yellow bile, and is useful in rabid dog bite. Hindu physicians describe it useful in fever, skin diseases, boils, itch, worms, and insanity and findings showed *Datura stramonium* oil as immunotherapeutic agent and can be used for colon cancer treatment (Akbar and Akbar 2020; Chandan et al., 2020).

Datura contains different types of phytochemical including saponins, tannins, steroids, flavonoids, phenols and glycoside. It contains a variety of tropane alkaloids such as atropine, hyoscyamine, and scopolamine, which have been reported to induce oxidative stress in different systems and tissues.

1.1 DISTRIBUTION AND HABITAT

D. stramonium is a shrub, a wild-growing plant of the Solanaceae family, distributed all over the world including Nigeria in West Africa (Mohanlall, 2020) . It is found in all four deserts of the American southwest, species of the plant can be found throughout the world, except in the cooler or Arctic regions. The plant lives in sandy flats, plains, arroyos up to 2,500 feet above sea level. Being of tropical origin, *D. stramonium* is a cosmopolitan weed of the warmer regions of North, Central and South America, Europe, Asia and Africa. It is essentially a temperate plant but is found growing in areas of cultivations, on rank soil, where refuse is deposited in all parts of the world .




Fig 1 *Datura stramonium* Source; Monaco nature encyclopedia

1.2 MORPHOLOGY AND ANATOMY

Datura species are herbaceous, leafy annuals and short-lived perennials which can reach up to 2m in height. *Datura stramonium* is about 60-120cm, branched and pubescent plant (Sanni *et al.*, 2014). The thorn apple is a large and course herb, branching and somewhat freely, giving a bushy look to the plant. On a rich soil it may attain a height of even 6 feet. The plant is smooth, except for a slight downiness on the younger parts, which are covered with short, curved hairs, which fall of as growth proceed. The root is long, thick, fibrous and white. The stem is stout, erect, leafy, smooth and pale-yellow green. The leaves are alternate, 10-20cm long and 5-18cm broad, they are ovate in outline but pinnately lobed. These lobes are somewhat shallow and pointed at their tips. The leaves are large and angular, uneven at the base, with a wavy and coarsely- toothed margin, and have a strong branching veins very plainly developed. The upper surface is dark and grayish-green generally smooth, the under surface paler, and when dry, minutely wrinkled (Sanni *et al.*, 2014).

The flowers are erect, trumpet- shaped, 5-20cm long and 4-12cm broad at the mouth, colors varies from white to yellow, pink and pale purple (Sanni *et al.*, 2014).

The flowers are succeeded by large, egg shaped seed capsules of a green color, about the size of a large walnut and covered with numerous sharp spines.

Each flower is replaced by a hard a hard fruit that is dry and spiny. The fruit is spiny capsule 4-10cm long and 2-6cm broad, is spheroid-ovoid in shape. These fruits are initially green, but become brown with maturity; they divide into four segments to release the seeds (Sanni *et al.*, 2014).

The large seeds are dull, irregular, and dark colored; their surface may be pitted or slightly reticulated.

1.3 PHYTOCHEMICAL CONSTITUENT OF *DATURA STRAMONIUM*

Datura stramonium contains sixty-four different types of tropane alkaloid. The major tropane alkaloids hyoscyamine and scopolamine and several minor tropane have been identified in *Datura* species. The primary biologically active substances in *D. stramonium* are the alkaloids atropine and scopolamine. The aqueous and the ethanolic extract of the stem bark of *Datura stramonium* contain many phytoconstituents such as alkaloids, saponins, tannin, steroids, flavonoids, phenols, steroidal glycosides, amino acids, carbohydrates and terpenoids (Srivastava and Srivastava 2020; Batool et al., 2020).

1.4 PHARMACOLOGICAL ACTIONS

Datura is known to exhibit analgesic, antioxidant, anticancer, and antimicrobial properties.

Anti-inflammatory and Analgesic Activities

The phytochemicals present in *Datura* species are well-known for their anti-inflammatory and analgesic properties due to their ability to suppress the production of chemical mediators responsible for the stimulation of nociceptors and induction of pain or inflammation (Sharma *et al.*, 2021).

Antioxidant Activities

The antioxidant activity of *Datura* extracts can also be attributed to the presence of phytochemical compounds, which acts as potent free radical scavengers and help prevent cellular damage. Analysis of *Datura* plant extracts for antioxidant characteristics revealed its ability to cure various health disorders, including cancers, since antioxidants are known to inhibit cell damage, the general pathway for cancers, aging and several other disease (Sharma *et al.*, 2021).

Antimicrobial Activities

The antimicrobial activity against pathogenic microbes was evaluated using aqueous and ethanolic extracts of different parts of *D. stramonium* and the results revealed that the ethanolic extracts showed better antimicrobial activity than the aqueous extracts. Moreover, the leaf extract were found to be more effective than stem and root.

Anti-Asthmatic Activities

D. stramonium contains a variety of alkaloids including atropine and scopolamine, having an anticholinergic and broncho dilating activity. Atropine and scopolamine act on the muscarinic receptors by blocking them (particularly the M2 receptors) on airway smooth muscle and submucosal gland cells, which dilate bronchial smooth muscle and ease asthmatic attacks (Srivastava and Srivastava 2020).

Anticancer Activities

D. stramonium was reported to have anticancer effect against human epidermal carcinoma of the nasopharynx at a therapeutic dose of 0.05 to 0.1g. However, precaution should be taken while using *Datura* as an anticancer agent since adverse anticholinergic effects may occur (Srivastava and Srivastava 2020).

1.5 TOXICITY OF DATURA STRAMONIUM

All parts of *Datura* plants contain dangerous levels of tropane alkaloids, atropine, hyoscyamine and scopolamine which are classified as deliriant, or anticholinergics. There is a high risk of fatal overdose for unformed users. However, a variety of tropane alkaloids are neurotoxic, and their frequent recreational abuse may lead to delirium and even death (Choudhary et al., 2021).

The presence of anticholinergic alkaloids such as tropane render the *Datura* specie toxic to the central nervous system and the symptoms of toxicity include, fever, dry skin, dry mouth, headache, hallucination, convulsions, rapid and weak pulse, acute confusion, tachycardia, coma and death. Moreover, due to its toxicity, *Datura Stramonium* should not be used in case of glaucoma, pyloric stenosis, paralytic ileus, enlarged prostate and acute pulmonary edema. In facts, all the parts of the plant have severe anticholinergic effects due to suppression of central and peripheral cholinergic neurotransmission, ultimately leading to death. Intoxication with *Datura* extract leads to adverse impact on the central nervous system, disorientation, memory loss, inability to process information , impaired vision due to mydriasis, hyperpyrexia, and respiratory and cardiovascular system. (Sharma *et al.*, 2021).

Datura is said to be used by vendors of native liquor, for the purpose of increasing its intoxicating power, the liquor being poured into a vessel which has been first filled with a smoke of the burning seeds. Many of the cases of DS intoxication reported in 1960s and 1970s occurred in hospitals and often featured quite severe symptoms. These cases may have involved people ingesting large amounts of the alkaloids without virtually little knowledge of the potential effect and doses. Oral and systemic administration may lead to severe anticholinergic symptoms which include dizziness, hallucination, loss of consciousness, nausea, hypertension, agitation, aggressiveness, photophobia, blurred vision and possibly coma which may last for several hours or days depending on the quantity consumed (Mukhtar *et al.*, 2019).

1.6 USES OF DATURA STRAMONIUM

Traditional Use

The world Health Organization (WHO) estimates that four billion people, about 80% of the world population presently use herbal medicine for some aspect of primary health care. Plants produce

many secondary metabolites which serve as important source of many pharmaceutical drugs (Srivastava and Srivastava 2020).

In Ayurvedic medicine, *Datura stramonium* is described as a useful remedy for various human ailments including ulcers, wounds, inflammation, rheumatism and gout, sciatica, bruises, and swellings, fever, asthma, bronchitis and toothache.

Holzman (2021) used extracts from *Datura* and morphine to induce twilight sleep treatment for women experiencing difficult childbirth. The combination of scopolamine and morphine was used for years as an effective pain reliever and sleep inducer.

Medicinal Use

Datura has been used since ancient times as an extremely treatment for asthma symptoms. The active anti-asthmatic agent is atropine, which causes paralysis of the pulmonary branches of the lungs, eliminating the spasms that cause asthma attacks. Leaves of *datura* are used in herbal medicine especially in case of Ayurveda for asthma and bone-setting. Roasted leaves is applied over the area of relieve pain. Leaves of *Datura* are used in antispasmodic, hypnotic & narcotic (Shekhar et al., 2017).

Atropine and scopolamine are muscarinic antagonists are the major phytoconstituents of *Datura* which has Parkinson's disease (PD) related medicinal potency which includes treatment of motor sickness and bradycardia. However, the exact mechanisms of anti-PD effects of its phytoconstituents remain underexplored (Lawal et al., 2023).

2.0 VITAMIN C (ASCORBIC ACID)

Vitamin C is a naturally occurring organic compound with antioxidant properties, found in both plants and animals. its function is as a redox buffer which can reduce, and thereby neutralize, reactive oxygen species. It is a cofactor for enzymes involved in regulating photosynthesis, hormone biosynthesis, and regenerating other antioxidants which also regulates cell division and growth, it's

involved in signal transduction, and has roles in several physiological processes, such as immune stimulation, synthesis of collagen, hormones, neurotransmitters, and iron absorption, and also has roles in detoxifying the body of heavy metals. It is also an antioxidant that helps protect against infection and iron absorption.

The main function and use of vitamin C is its antioxidant activity against reactive oxygen species, which are implicated in many diseases of free radical pathology, including biomolecular-, cellular- and tissue damage-related diseases, as well as cancer and ageing. Ascorbic acid and its metabolites, including the ascorbate anion and oxalate, have metal binding capacity and bind iron, copper and other metals. The biological roles of ascorbate as a vitamin are affected by metal complexation, in particular following binding with iron and copper. Ascorbate forms a complex with Fe^{3+} followed by reduction to Fe^{2+} , which may potentiate free radical production (Kontoghiorghes, 2020).

Vitamin C also plays an important role in abiotic stress tolerance, and considerable interest has been on it due to its ability to induce a protective effect on plants under stress. It has been supported that vitamin C induced increase in the resistance of plants on heavy metal stress (Pehlivan, 2014).

2.1 REDOX METABOLISM AND ANTIOXIDANT PROPERTIES OF VITAMIN C

Oxidative stress occurs due to the imbalance between the production of reactive oxygen species (ROS) and the availability of antioxidants or radical scavengers. The excess ROS produced can either oxidize biomolecules or can structurally modify proteins and genes so as to trigger signaling cascades that can lead to the onset and progression of inflammatory diseases. ROS-induced activation of transcription factors and pro-inflammatory genes lead to the onset of inflammation. Inflammation causes immune cells to secrete various cytokines and chemokines in order to recruit

various other immune cells to the site of oxidative stress/infection. Reflexively, an enhanced ROS generation by immune cells at the site of inflammation causes oxidative stress and tissue injury (Chatterjee, 2016).

Oxidation process is a chemical reaction that produces free radicals, leading to chain reactions that damage cells. (Pehlivan, 2017). Vitamin C is a powerful antioxidant having the ability to donate a hydrogen atom and form a relatively stable ascorbyl-free radical and its suggested to decrease oxidative damage and lowering risk of certain chronic disease. Vitamin C (L-ascorbic acid or ascorbate) is a biomolecule that participates in many biochemical processes. It has a variety of functions in the body that we might venture to say make it a very important antioxidant nature and pro-oxidant (Akbari, 2016).

Antioxidant compounds at a low concentration delays or prevent oxidation of a substance and act through several chemical mechanism: hydrogen atom transfer (HAT), single electron trans(SET), and the ability to chelate transition metals (Santos-Sánchez, 2019).

2.1.2 ROLE OF VITAMIN C (ASCORBIC ACID) IN LIPID PEROXIDATION

The chemical and biological properties of L-ascorbic acid suggest that it can act as an antioxidant in vivo. Vitamin C is a primary antioxidant in that it directly neutralizes radical species. It is not very active with prevalent cellular oxidants such as hydrogen peroxide and probably reacts with hydrogen peroxide breakdown products. Vitamin C has the ability to protect against lipid peroxidation by acting as a scavenger of ROS and by one-electron reduction of lipid hydroperoxyl radicals via the Vitamin E redox cycle (Pehlivan, 2017).

2.2.3 ASCORBIC ACID IN HUMAN DISEASE

As an electron donor, vitamin C could be involved in several disease processes. Vitamin C is present in almost all foods of plant origin. The mineral vitamin C requirements for humans is defined as 40-

60 mg/day to combat dietary deficiency. However, Vitamin C status decreases with both age and smoking, and is associated with chronic diseases such as rheumatoid arthritis and cancer. Vitamin C are consumed by preventing free radical induced damage of DNA, which is thought to be an initiating step in cancer formation. Vitamin C supplements, which are able to prevent the formation and/ or promote the repair of pre-mutagenic oxidative DNA lesions, are suggested to be of use in cancer prevention.

2.2.4 THE BRAIN

The human brain is the most complex and fascinating organ of the human body (Forstmann et al., 2015). It is the center of the nervous system in all vertebrate and most invertebrate animals, controls thought, memory, emotions and every process that regulates our body. The adult brain constitute about one-fifth of body weight and weighs about 1400g in males and 1200g in females. It consist of six major parts; Cerebrum, Diencephalon, Mid brain, Pons, Medulla oblongata and the Cerebellum (Singh, 2020). The cerebrum is the largest part of the brain, consist of two large hemispheres connected by a mass of white matter called Corpus Callosum. It occupied the anterior and middle cranial fossae and the supratentorial region of the posterior cranial fossae (Singh, 2020). The cerebral cortex is the surface of grey matter covering the cerebral hemisphere and is divided into four major lobes (frontal, parietal, temporal and occipital). The frontal lobe is responsible for responses relating to memory, emotions, reasoning, judgement, planning and verbal communication. This lobe is very vital to the health as a result, any structural alteration should be avoided (Singh, 2020).

The brain performs various functions which include; receives information from, and control the activities of trunk and limbs mainly through its connections with spinal cord, receives the information, and controls the activities of head and neck sutures through cranial nerves. It is also responsible for ones personality, thoughts and aspirations (Singh, 2020).

The brain consist of two main cells, neurons and glial cells. Neurons are the primary functional cells of the brain and are responsible for processing and transmitting information while the glial cells surround the neurons, their function is to maintain and nourish them.

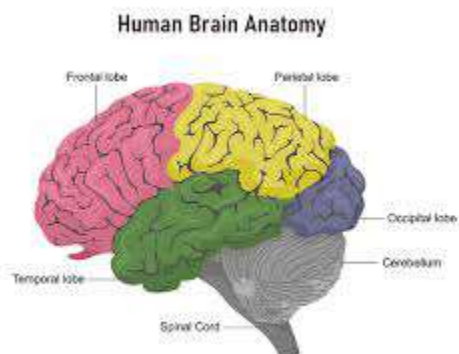


Fig 2 Structure of the brain. Source: John Hopkins medicine

The brain is metabolically one of the most active organs in the body and much more susceptible to free radical attack and oxidative stress. Oxidative stress has been involved in pathogenesis and progression of many neurological disorders. Oxidative stress occurs often as a result of imbalance between the intrinsic antioxidants and free radical production in favor of the latter, leading to disruption of mitochondrial function and contributing to neuronal degeneration characterized by progressive loss of neuron cells, compromised motor or cognitive functions, and accumulation of abnormally aggregated proteins leading to neurodegenerative diseases (Kowalczyk, 2021; Cenini et al., 2019).

The human body is equipped with a variety of antioxidants that serve to counterbalance the effect of oxidative stress, example is Vitamin C. It is a water-soluble micronutrient required for multiple biological functions. Vitamin C is one of the potent reducing agents and scavengers of free radicals in biological systems, working as a scavenger of oxidizing free radicals and harmful oxygen-derived species such as hydroxyl radical, hydrogen peroxide and singlet oxygen. It is an antioxidant that helps protect against infection and iron absorption. Vitamin C is a dibasic acid with an enediol group built into a five membered heterocyclic lactone ring (Pehlivan, 2017).

In recent years, research has been conducted to investigate the effects of *Datura stramonium* on the frontal cortex. The intake of large dose, *Datura stramonium* has effects on the central nervous system and produces symptoms like confusion, hallucination and amnesia.

A study conducted by (Ekanem *et al.*, 2016) investigated the histological patterns of neurodegeneration of frontal cortex neurons in *Datura stramonium* treated wistar rats. This study is to show the efficacy of ascorbic acid on frontal cortex damage induced by the ethanolic extract of DS leaf in wistar rat.

This study will further investigate the morphological and histological effect of *Datura stramonium* leaf on the frontal cortex of adult male wistar rat.

3.0: MATERIALS AND METHODOLOGY

3.1: Materials

The following materials were utilized in the experiment:

- *Datura stramonium*
- Vitamin C
- 30 Wistar rats
- Widen cages

- Water plates
- Feeding plates
- Standard rat feed and water
- Weighing scale
- Oral cannula
- Syringes and needles
- Dissecting gloves
- Dissecting sets and slab
- Measuring cylinder
- Fixatives
- Hematoxylin and eosin
- Xylene and paraffin wax
- Glass slides and cover slips
- Graded alcohol
- DPX mountant
- Cotton wool
- Staining jars
- Tissue cassettes and molds
- Heater
- Microscope

3.1.2: Site of Study

The study was conducted in the animal house of the Anatomy Department at the Faculty of Basic Medical Sciences, Ladoke Akintola University of Technology, Ogbomosho, Oyo State.

3.2 Methodology

3.2.1 Preparation of Ethanolic Extract of *Datura stramonium* Leaf

Fresh *Datura stramonium* leaves were collected from Pectorial Guest House, Oke Anu, Ogbomosho, Oyo State, Nigeria. The leaves were identified at the Department of Pure and Applied Biology, Ladoke Akintola University of Technology, Ogbomosho, with the voucher numbers LH0731 and LH0588. The leaves were air-dried for two weeks, then pounded into powder form using a mortar and pestle. The powder was measured with a metal-sensitive weighing balance and soaked in distilled water for three days. The mixture was sieved using a muslin cloth, and the filtrate was collected and processed at the Department of Food Science and Technology, LAUTECH, where the dried sample was obtained (Gad-Elkareem et al., 2019).

3.2.2 Acclimatization of the Experimental Animals

Thirty male Wistar rats, with an average body weight of 120 grams, were obtained from the Department of Anatomy animal house at LAUTECH. The rats were acclimatized for two weeks and weighed weekly during this period and throughout the three-week experimental period. The animals

were well-handled and maintained at a constant room temperature of 25°C. They were provided with standard rat feed and water *ad libitum*.

3.2.3 Animal Sacrifice and Collection of Organs

The experimental animals were sacrificed via cervical dislocation. The skulls were thoroughly dissected, and the brains were identified and harvested. Blood samples were also collected for further studies. The brains were then processed for tissue analysis.

3.3 Experimental Design

The rats were randomly divided into six groups: A, B, C, D, E, and F (n=5 rats each).

- **Group A:** The control group was administered standard rat feed *ad libitum*.
- **Group B:** Administered 200 mg/kg body weight of *Datura stramonium* extract orally every day for 14 days.
- **Group C:** Administered 400 mg/kg body weight of *Datura stramonium* extract orally every day for 14 days.
- **Group D:** Received 200 mg/kg of *Datura stramonium* extract and 200 mg/kg body weight of vitamin C orally daily for 14 days.
- **Group E:** Received 400 mg/kg of *Datura stramonium* extract and 200 mg/kg body weight of vitamin C orally daily for 14 days.
- **Group F:** Received 200 mg/kg body weight of vitamin C orally daily for 14 days.

At the end of the second week, the animals were sacrificed by cervical dislocation, and their brains were immediately removed.

The LD50 of ethanolic extract of *Datura stramonium* leaf was reported to be 3185.25 mg/kg in rats (Al-snafi, 2017).

The LD50 of Vitamin C was reported to be 11900 mg/kg in rats (Ghaleb et al., 2019; Animoku et al., 2019).

3.3.1 Histological Procedures

3.3.2 Tissue Processing

Thin slices were taken from each brain and placed in a tissue cassette, which was then placed in tissue baskets. An automated tissue processor was used to carry out the stages involved in tissue processing, including fixation, dehydration, clearing, infiltration, embedding, sectioning, floating, drying, staining, and mounting (Nayak, 2017).

3.3.3 FIXATION

The brain was fixed in formal calcium, which is obtained by 40% formaldehyde (100 ml), calcium chloride (10g), and Distilled water (900 ml) (Bhat & Hussein, 2021). This was used to preserve the natural tissue structure and maintain the cell structure from degradation.

3.3.4 Dehydration

After fixation, the tissues were removed and rinsed in running water before being subjected to dehydration. This involves removing water from the fixed tissue, which is removed from the tissues through the dehydration method through ethanol (Gartner, 2020).

3.3.5 Clearing

The tissue is now water-free, but wax infiltration cannot occur because wax and ethanol are immiscible. Therefore, an intermediate solvent fully miscible with ethanol and paraffin wax is used. The solvent used for these intermediate stages is usually xylene (O'Dowd et al., 2023). The tissue was placed in two changes of xylene for 1 hour each (MD, 2019); the ethanol was gradually replaced with xylene, and when the tissue was embedded, the xylene was replaced by the molten paraffin wax (Gunasegaran, 2016).

3.3.6 Infiltration

This involves transferring tissues into a bath of molten paraffin in one of the chambers of the automatic embedding machine twice for 1 hour each (MD, 2019), where they solidify to a constituent that allows sections to be consistently cut. Tissue is used for this process.

3.3.7 Embedding

In staining, the process of embedding is done using paraffin wax to enhance easier extraction of cellular structures. In complex cellular tissues, plastic resin wax or a combination of fixatives produces good morphology (Alturkistani et al., 2016). The specimen is thoroughly infiltrated with wax and formed into a block, which can be clamped into a microtome for section cutting. This step uses an "embedding center," where a mold is fixed with molten wax, and the specimen is placed. The specimen is very carefully oriented in the mold because its placement will determine "the planes of the section" (Dey, 2018).

3.3.8 SECTIONING AND FLOATING

Sectioning refers to the preparation of "ribbon" like microtomes of tissue to mount on a microscope slide for examination (Knoblauch et al., 2021). Tissue is embedded with optimal cutting temperature (OCT) or paraffin before being sectioned. This is achieved by using a machine called a microtome to cut the tissue into the desired planes (longitudinal, transverse, sagittal) and desired thickness (Winsor & Sluys, 2018). When the section has fully expanded and flattened on the surface

of the warm water, it is picked up with a well-labeled slide and transferred into an incubator (45-50) for at least 1 hour for the slide to dry completely.

3.3.9 STAINING

Staining highlights the essential features of the tissue and enhances the tissue contrast. Crexyl violet is an effective and reliable stain used for light microscopy sections. It is used to stain the neurons of the brain and spinal cord and demonstrate the Nissl substance in the neurons and cell nuclei (Gurina and Simms, 2020).

3.4.0 MOUNTING

A dropper is used to apply one or two drops of DPX mountant to the center of the glass slide. To remove any air bubbles, the tissue part is gently placed onto the mountant drop and gently pressed onto the slide. The slide is then covered with a coverslip and tagged with the specimen name (Singh-Bains et al., 2021).

3.4.1 STATISTICAL ANALYSIS

Graph pad prism Software (Version 5.0) was used to analyze the data obtained from the study. The statistical analysis for the respective weights of the animals was done using one-way analysis of variance (ANOVA) using a graph pad prism.

4.0 RESULT

4.1 BODY WEIGHT

Table 1 Shows the result of the body weight of experimental animals across all groups. Animals in Group A, the control group, showed an increase in body weight at the end of the experiment. Group B, which received 200mg/kg of *Datura Stramonium* leaf extract, showed an increase in body weight at the end of the experiment. Group C, which received 400mg/kg of *Datura Stramonium* leaf extract, showed an increase in body weight at the end of the experiment. Group D, which received 200mg/kg of *Datura Stramonium* leaf extract with 100mg/kg of Vitamin C, showed an increase in body weight at the end of the experiment. Group E, which received 400mg/kg of *Datura Stramonium* leaf extract and Vitamin C, showed an increase in body weight at the end of the experiment, respectively. Group F, which received 100mg/kg of Vitamin C, showed an increase in body weight at the end of the experiment.

Figure 3 shows an increase in the final body weight of Group A, B, C, D, E and

Table 2: Shows the result of the p-value data obtained from comparison of Group A body weight to other Groups. The level of significance is $P < 0.05$. All values less than 0.05 are statistically significant (*)

TABLE 3 and FIGURE 3 Show the result of the initial versus final weight of experimental animals across all groups. All animals showed increased body weight at the end of the experiment. FIGURE 3: Showed the result of the comparison of the initial and final weight of

the experimental animals in group D and F. Group D showed an increase in body weight after receiving 200mg/kg of *Datura Stramonium* leaf extract and 100mg/kg of Vitamin C. Animals in group F showed an increase in body weight.

FIGURE 4: Showed the result of the comparison of the initial and final weight of the experimental animals in groups E and F. Group E showed an increase in body weight after receiving 400mg/kg of *Datura Stramonium* leaf extract and 100mg/kg of Vitamin C. Animals in group F also increase in body weight.

TABLE 4 Shows the weight of the organ (brain) of the experimental animal in each group

Table 1 Shows data analysis results of body weight changes of experimental animals. Data are presented as the (Mean \pm S.E.M).

GROUPS	INITIAL WEIGHTS (g)	WEIGHT AFTER WEEK 1(g)	FINAL WEIGHTS(g)
A	100.4 \pm 5.767	107.6 \pm 7.646	123.6 \pm 8.750
B	93.60 \pm 5.144	116.6 \pm 6.377	129.8 \pm 7.664
C	91.40 \pm 4.226	115.8 \pm 6.799	121.8 \pm 9.040
D	96.20 \pm 6.793	127.0 \pm 7.000	152.5 \pm 4.500
E	99.00 \pm 4.690	123.0 \pm 3.440	141.8 \pm 2.839

F	95.40 ± 4.567	106.5 ± 9.921	129.5 ± 10.690
---	---------------	---------------	----------------

Level of significance is $P < 0.05$. All values less than 0.05 are statistically significance (*) While all values greater than 0.05 are not statistically significance. All values are expressed in Mean ± S.E.M.

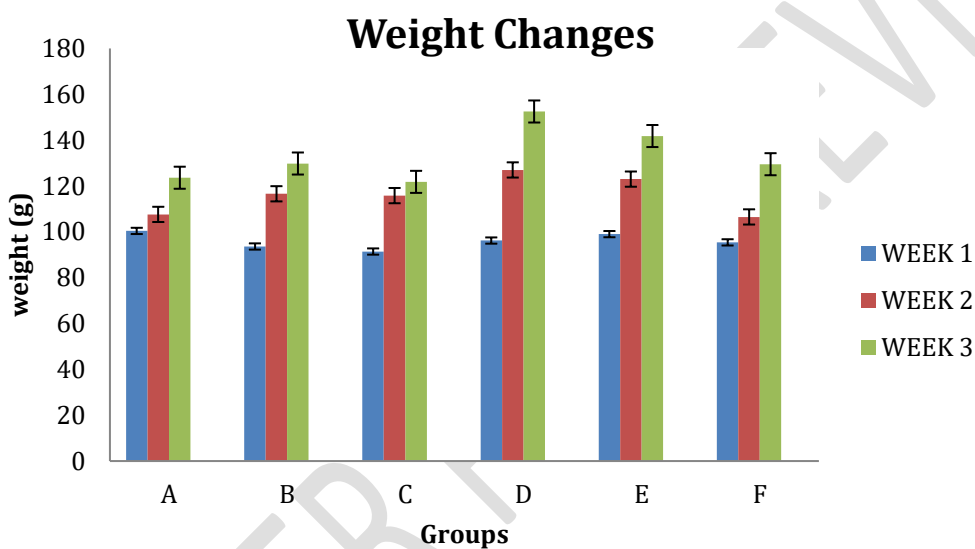


Fig 3 Bar chart showing analysis of Mean ± S.E.M of body weight of Groups A, B, C, D, E, and F across Week 1 to Week 3. Values are represented in Mean ± S.E.M

Table 2 shows the p-value data obtained from comparing the body weights of the groups.

GROUPS	P-Value
A vs B	0.8351
A vs C	0.9438
A vs D	0.4520
A vs E	0.4906

A vs F	0.9959
--------	--------

Significance P: ≤ 0.05 . Values greater than 0.05 are considered insignificant, while values less than 0.05 are considered significant. So, all the values obtained for the p-value are insignificant.

Table 3 Shows the initial and final weights of the experimental animals. Values are expressed in Mean \pm S.E.M.

GROUPS	INITIAL WEIGHT	FINAL WEIGHT
A	100.4 \pm 5.767	123.6 \pm 8.750
B	93.60 \pm 5.144	129.8 \pm 7.664
C	91.40 \pm 4.226	121.8 \pm 9.040
D	96.20 \pm 6.793	152.5 \pm 4.500
E	99.00 \pm 4.690	141.8 \pm 2.839
F	95.40 \pm 4.567	129.5 \pm 10.690

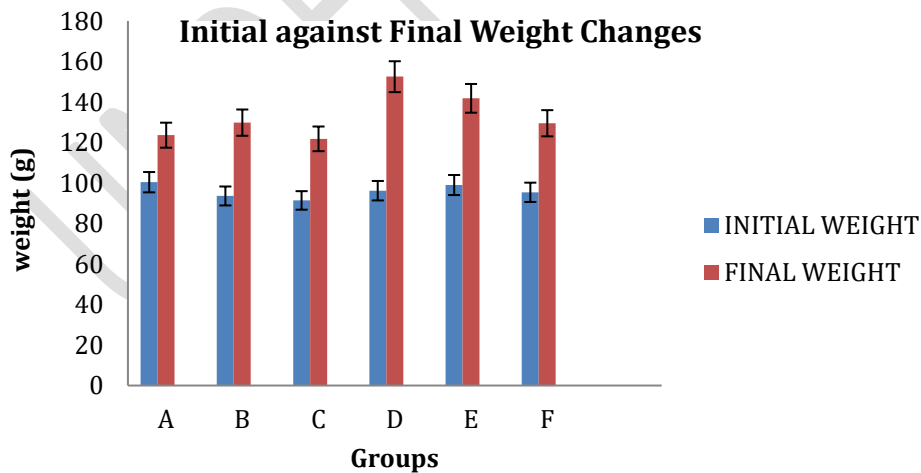


Fig 4 shows bar charts representing data analysis results of experimental animals' initial and final body weight.

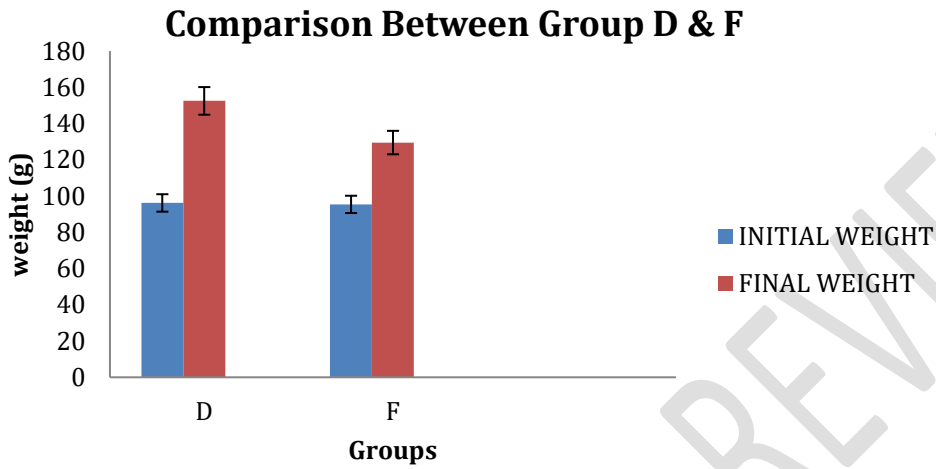


Fig 5 Bar chart showing a comparison of group D against F

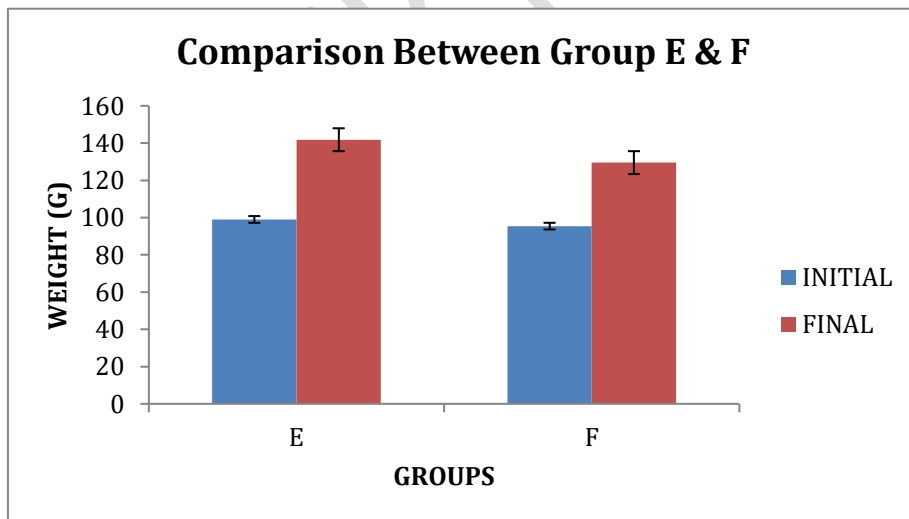


Fig 6 Bar chart showing a comparison of group E against F

ORGAN WEIGHT (THE BRAIN)

Table 4 reveals the mean organ weight of the animals in each group.

Data are presented as mean \pm standard error of the mean (Mean \pm SEM)

GROUPS	WEIGHT (g)
A	1.340 \pm 0.05099
B	1.340 \pm 0.04000
C	1.200 \pm 0.04082
D	1.500 \pm 0.2000
E	1.500 \pm 0.1155
F	1.450 \pm 0.1756

Significance P: \leq 0.05. Values greater than 0.05 are considered insignificant, while values less than 0.05 are considered significant in the body weight of the experimental animal.

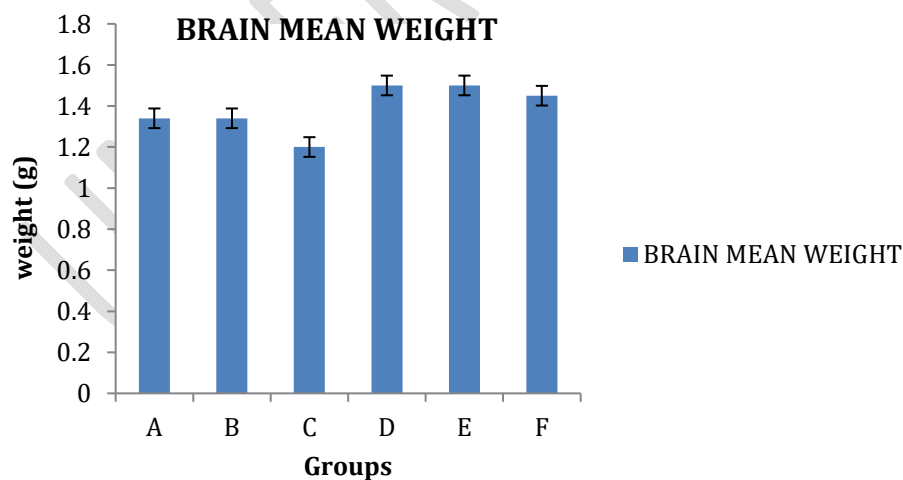


Fig 7 Bar chart showing Mean \pm S.E.M of brain weight

GROUPS	Relative Weight Index
A	1.100 ± 0.06607
B	1.045 ± 0.05755
C	1.004 ± 0.08666
D	0.9806 ± 0.1022
E	1.044 ± 0.1099
F	1.131 ± 0.1293

Table 5 shows the relative weight index of the organ (brain) of the experimental animal in each group. Data are presented as mean ± standard error of the mean (mean ± SEM).

Significance P: ≤ 0.05. Values greater than 0.05 are considered insignificant, while values less than 0.05 are considered significant in the relative weight index of the experimental animal.

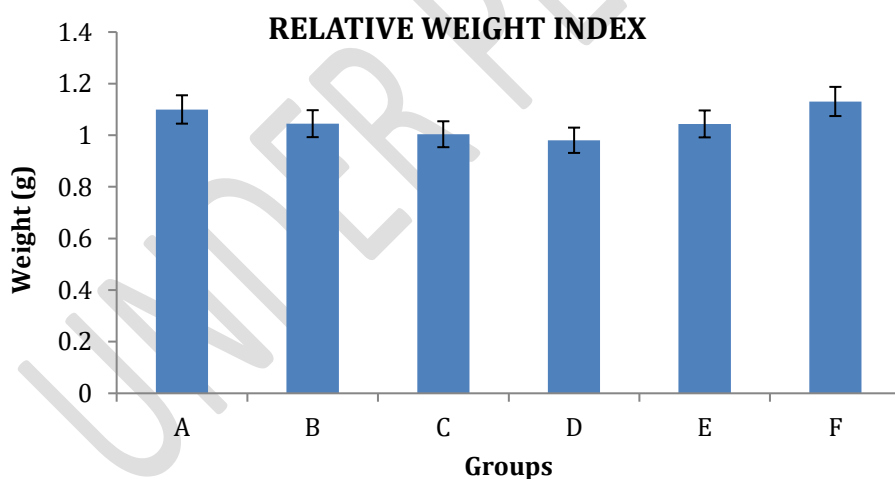


Fig 8 Bar chart showing Relative Weight Index. Values represented in Mean ± S.E.M

Table 6 shows the p-value data obtained from the relative weight index.

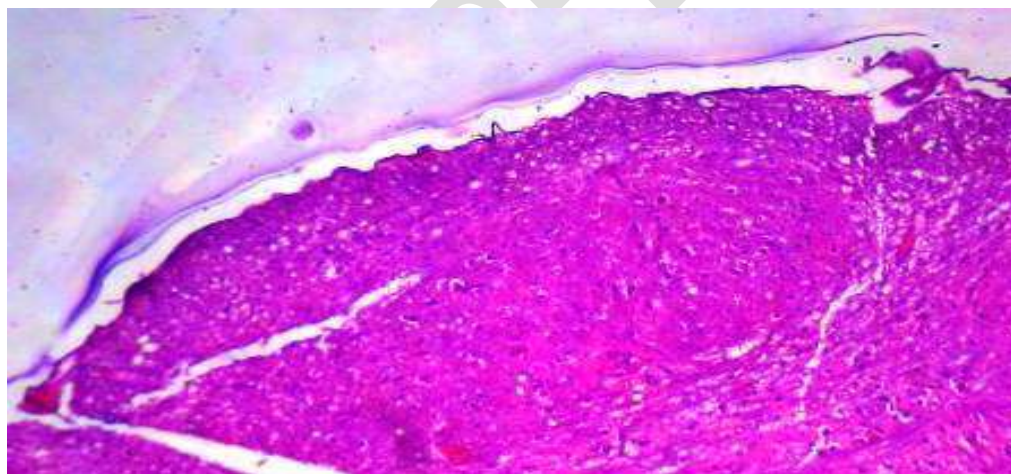
GROUPS	P-Value
A vs B	0.5473
A vs C	0.4021
A vs D	0.3780
A vs E	0.6617
A vs F	0.8260

Significance P: ≤ 0.05 . Values greater than 0.05 are considered insignificant, while values less than 0.05 are considered significant. So, all the values obtained for the p-value are insignificant.

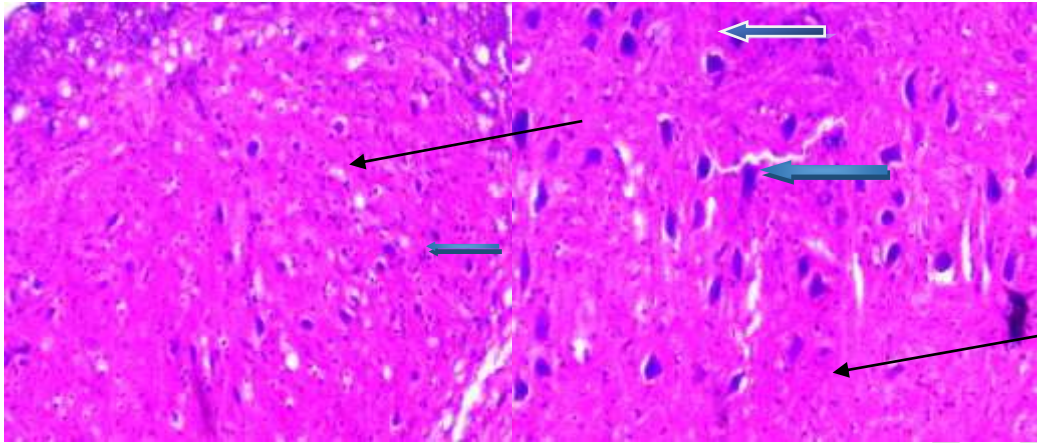
4.2 Histological Findings

PHOTOMICROGRAPH (Hematoxylin and Eosin)

GROUP A



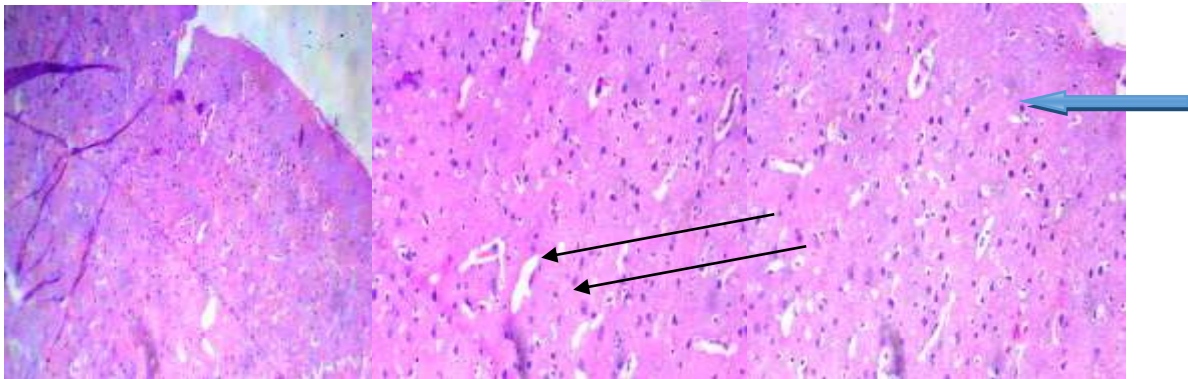
X100



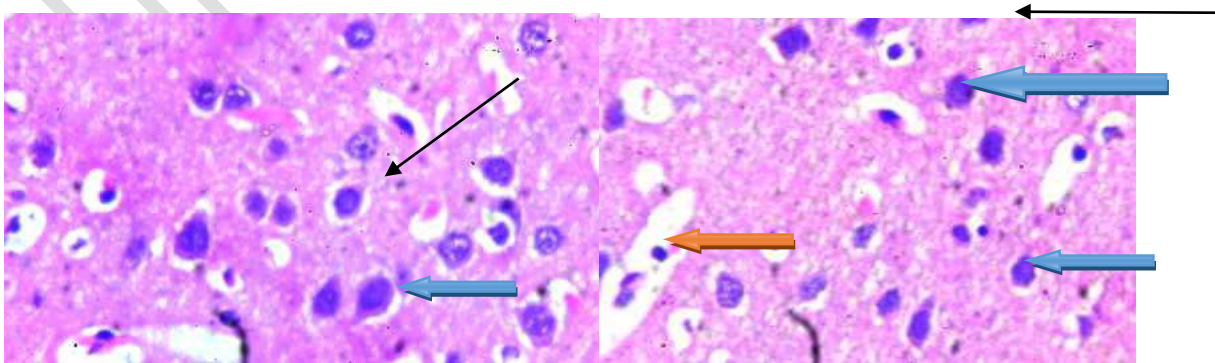
X400

Plate 1& 2: Photomicrograph of a brain section demonstrated by Hematoxylin and Eosin at low magnification and high magnification (X100 and X400) showing the Frontal cortex with normal neuronal cells (blue arrow), the capillaries seen are normal (red arrow), and the stroma also appear normal as well (slender arrow).

GROUP B



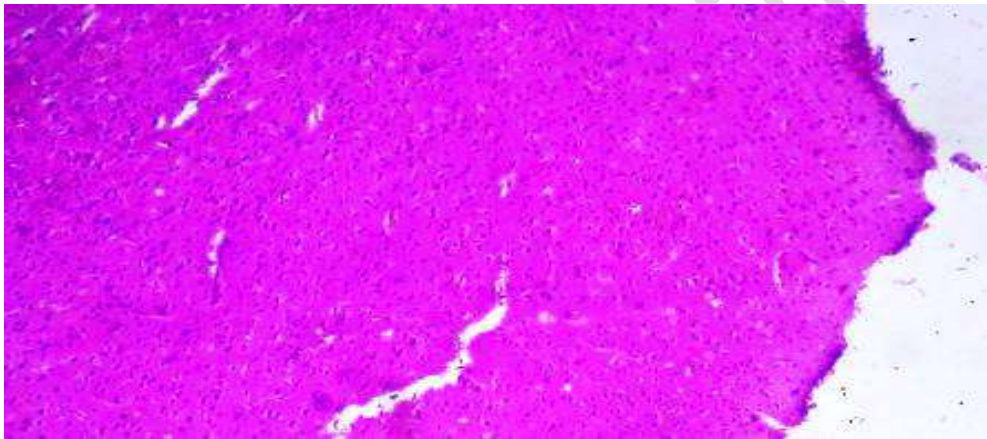
X100



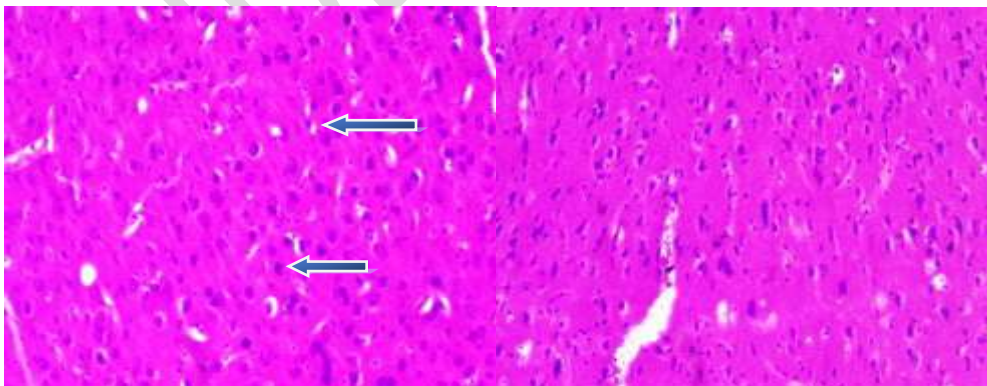
X400

Plate 3&4: Photomicrograph of a brain section demonstrated by Hematoxylin and Eosin at low and high magnification (X100 and X400) showing the Frontal cortex with normal neuronal cells (blue arrow), the capillaries seen are normal (red arrow), and the stroma also appear normal as well (slender arrow).


GROUP C

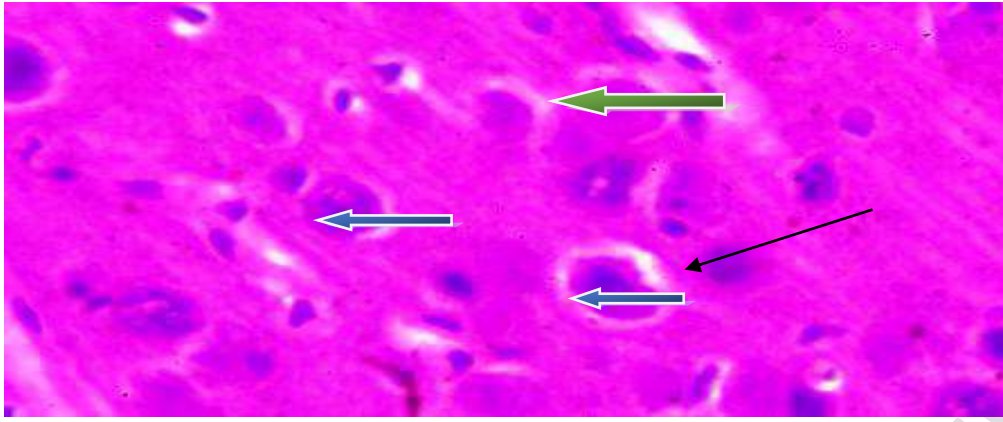


X40



X100

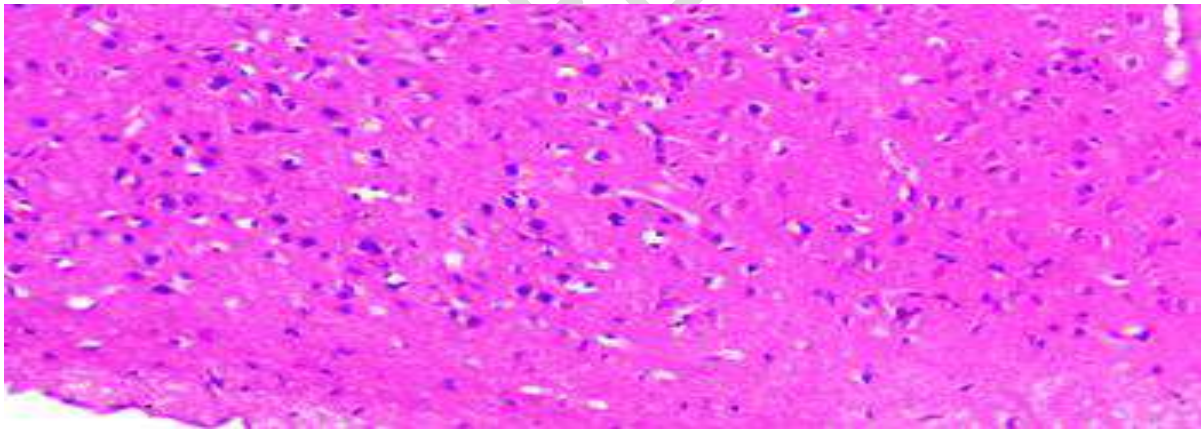




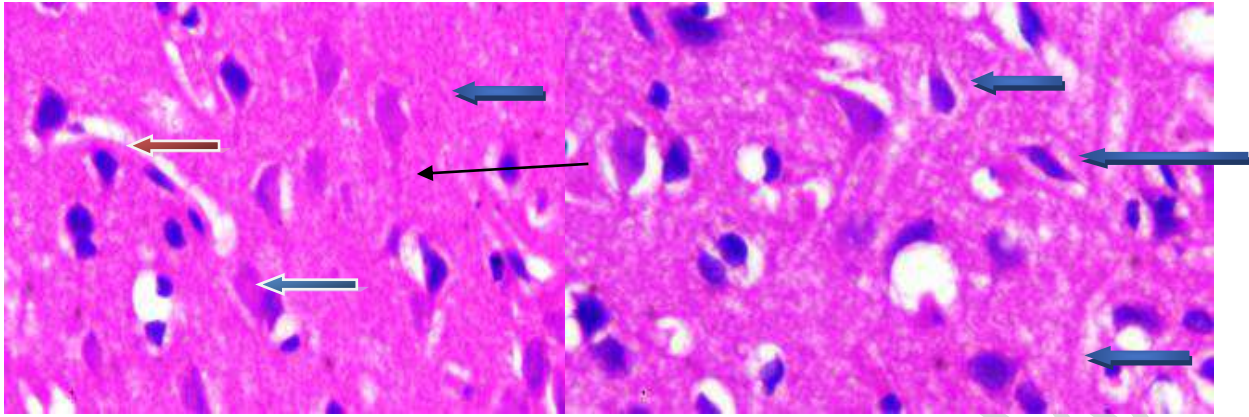
X400

Plate 5, 6 and 7: Photomicrograph of a brain section demonstrated by Hematoxylin and Eosin at low and high magnification (X40, X100, and X400) showing the Frontal cortex with some normal neuronal cells (blue arrow) and degenerated neurons with cytochromatolysis (green arrow) and the stroma also appear normal (slender arrow).

GROUP D



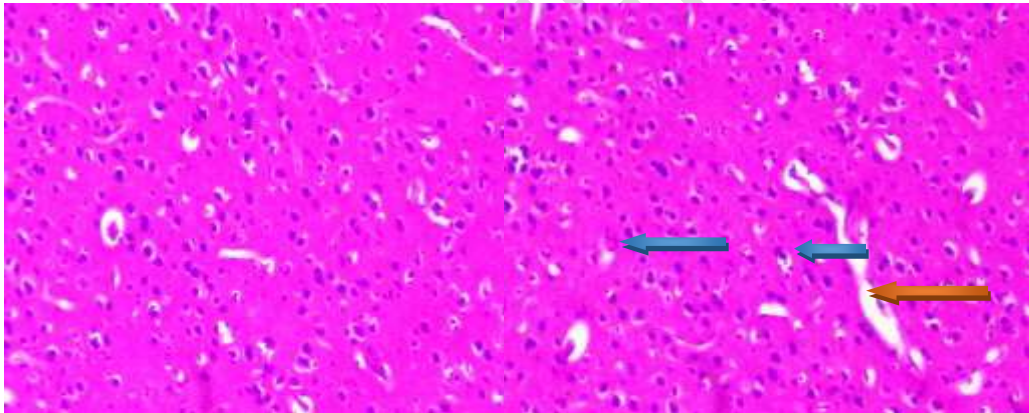
X100



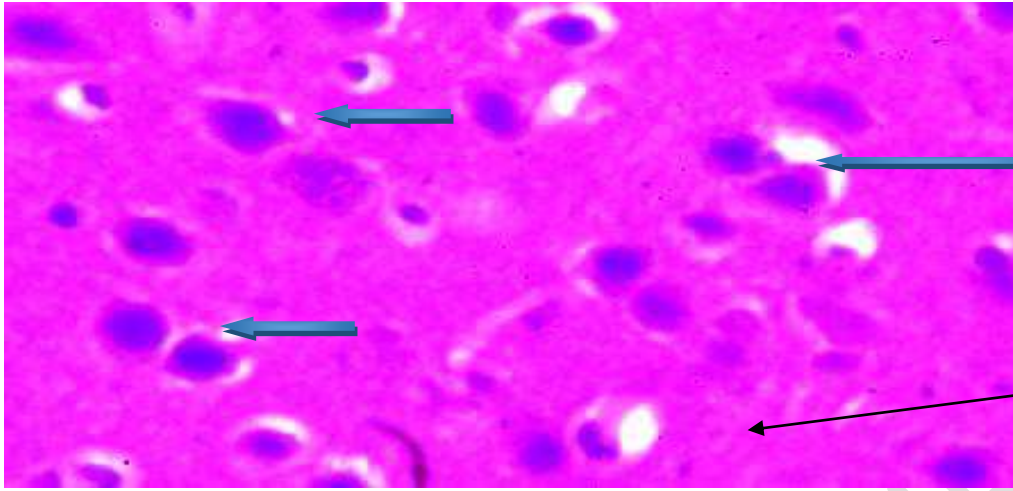
X400

Plate 8&9: Photomicrograph of a brain section demonstrated by Hematoxylin and Eosin at low and high magnification (X100 and X400) showing the Frontal cortex with normal neuronal cells (blue arrow), the capillaries (red arrow) seen are normal, and the stroma also appear normal as well (slender arrow).

GROUP E



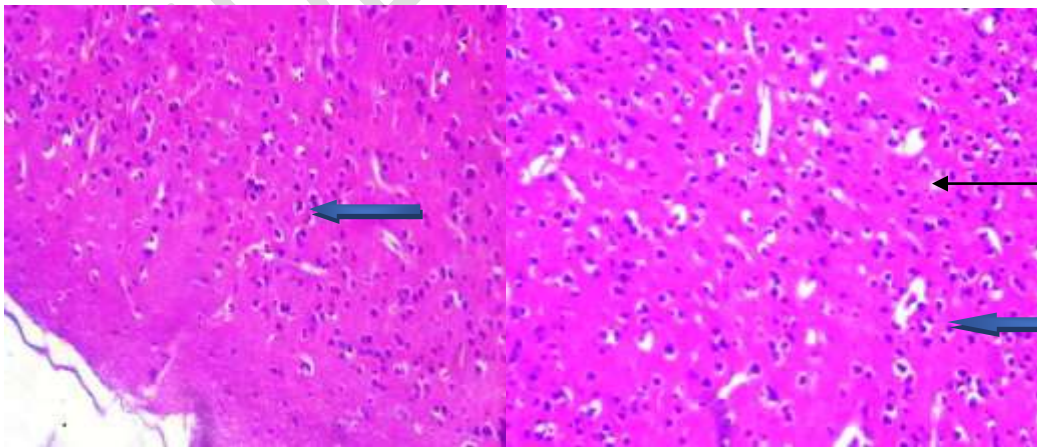
X100



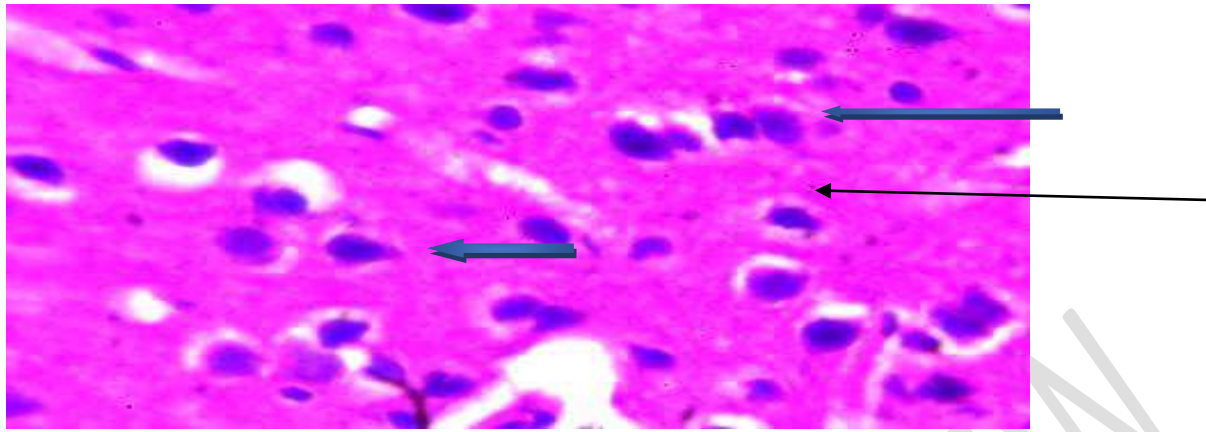
X400

Plate 10&11: Photomicrograph of a brain section demonstrated by Hematoxylin and Eosin at low and high magnification (X100 and X400) showing the Frontal cortex with normal neuronal cells (blue arrow), the capillaries seen are normal (red arrow), and the stroma also appear normal as well (slender arrow).

GROUP F



X100



X400

Plate 12&13: Photomicrograph of a brain section demonstrated by Hematoxylin and Eosin at low and high magnification (X100 and X400) showing the Frontal cortex with normal neuronal cells (blue arrow), the capillaries seen are normal (red arrow), and the stroma also appear normal as well (slender arrow).

5.0 Discussion

Datura stramonium is a widespread annual plant from the Solanaceae family. Consumption of any part of the plant may result in severe anticholinergic reactions that may lead to toxicity and occasionally cause diagnostic difficulties. The major alkaloids hyoscyamine, scopolamine, and several minor tropane alkaloids have been identified in *Datura* species (Kadam et al., 2018).

The brain is metabolically one of the most active organs in the body and much more susceptible to free radicals and oxidative stress. Oxidative stress has been involved in pathogens and the progression of many neurological disorders. The frontal lobe is responsible for responses relating to memory, emotions, reasoning, judgment, planning, and verbal communication. This lobe is vital to health, so any structural alteration should be avoided (Crossman and Neary, 2018; Yu et al., 2020).

In their study, (Ekanem et al. 2016) found that the administration of *Datura stramonium* leaf extract at a specific concentration induced neurotoxicity in the cerebral cortex, as observed in electron photomicrographs. The statistical analysis shows that all groups of experimental animals gained weight compared to their initial weight.

Experimental animals in groups B and C were administered orally 200mg/kg (low dose) and 400mg/kg (high dose) body weight respectively of ethanoic extract of *Datura stramonium* leaf, which revealed an increase in final mean weight, showing no statistical significance ($p < 0.05$), when compared with initial results. This is in support of findings by (Animoku et al., 2019).

Co-administration of 200mg/kg (low dose) body weight of ethanoic extract of *Datura stramonium* leaf and 200mg/ml of vitamin C and Co-administration of 400mg/kg (high dose) body weight of ethanoic extract of *Datura stramonium* leaf and 200mg/ml of vitamin C to Groups D and E respectively shows an increase in their final mean weight but shows no statistical significance ($P < 0.05$).

Administration of 200mg/ml of Vitamin C to the experimental animals of group F shows an increase in the final mean weight but shows no statistical significance ($p < 0.05$).

Analysis of the relative weight index shows an increase in the relative weight of organs in all groups compared to the control group.

The histological analysis from the study shows that the frontal cortex in all groups (A, B, D, E, and F) had normal neuronal cells and stroma. Group A did not show any significant changes in the histology of the neurons of the frontal cortex. There were no definite patterns of neuro-degeneration recorded in the FC neurons of Group B compared to the control (Group A). This could imply that lower dosage may not produce a clear pattern of neurodegeneration in the frontal cortex; this is in support of (Ekanem et al., 2016).

On the other hand, Group C was found to induce neurotoxicity in the frontal cortex, as observed in photomicrographs (Plate 5, 6, and 7), which showed evidence of neurodegeneration compared to other groups. Group D, E, and F, which received ascorbic acid, did not show any significant changes in the histology of the frontal cortex neurons.

6.0

Recommendation

Precaution should be taken when consuming *Datura stramonium* leaf because it may adversely damage the neurons in the frontal cortex. Further studies should be done to investigate the behavioral, biochemical, and neurochemical alterations in the neurons of the frontal cortex challenged with varying doses of *Datura stramonium* leaf extract.

7.0 Conclusion

Administration of the ethanolic extract of *Datura stramonium* leaf at excessive dosages induced significant histological alterations in the neurons of the frontal cortex in Wistar rats, including neuronal cell death and axonal atrophy.

CONSENT

It is not applicable

ETHICAL

APPROVAL

Animal Ethics Committee approval has been collected and preserved by the author(s).

REFERENCE

- Abdallah, E. M., Alhatlani, B. Y., de Paula Menezes, R., & Martins, C. H. G. (2023). Back to Nature: Medicinal plants as promising sources for antibacterial drugs in the post-antibiotic era. *Plants*, 12(17), 3077; <https://doi.org/10.3390/plants12173077>
- Akbar, S., & Akbar, S. (2020). *Datura stramonium* L.(Solanaceae). *Handbook of 200 Medicinal Plants: A Comprehensive Review of Their Traditional Medical Uses and Scientific Justifications*, 857-868. https://doi.org/10.1007/978-3-030-16807-0_90
- Akbari, Abolfazl. (2016). An overview of the Characteristics and function of Vitamin c in various tissues: relying on its antioxidant function. *Zahedan Journal of research in Medical Sciences (tabib-e-shargh)*, 18(11), 0-0. sid. <https://sid.ir/paper/692543/en>
- Al-Snafi, A. E. (2017). Medical importance of *Datura fastuosa* (syn: *Datura metel*) and *Datura stramonium*-A review. *IOSR Journal of Pharmacy*, 7(2), 43-58.
- Alturkistani, H. A., Tashkandi, F. M., & Mohammedsaleh, Z. M. (2016). Histological stains: a literature review and case study. *Global journal of health science*, 8(3), 72.
- Animoku Abdulrazaq, A., Suleiman, M. O., Iliyasu Musa, O., Bolaji, M. S., Ademola, Y. U., Omachonu, O. A., ... & Simpa, M. J. (2019). Histomorphological Studies of the Cerebellum in Mercury Exposed Rats and the Role of Ascorbic Acid (Vitamin C). *Evaluation*, 4th.
- Batool, A., Batool, Z., Qureshi, R., & Raja, N. I. (2020). Phytochemicals, pharmacological properties and biotechnological aspects of a highly medicinal plant: *Datura stramonium*. *Plant Sci*, 8(2), 29-40. doi: 10.11648/j.jps.20200802.12
- Bhat, A. H., & Hussein, S. (2021). Fixation and different types of fixatives: Their role and functions: A review. *Int. J. Clin. Diagn. Pathol*, 4, 113-119.
- Cenini, G., Lloret, A., & Cascella, R. (2019). Oxidative stress in neurodegenerative diseases: from a mitochondrial point of view. *Oxidative medicine and cellular longevity*, 2019. <https://doi.org/10.1155/2019/2105607>
- Chandan, G., Kumar, C., Verma, M. K., Satti, N. K., Saini, A. K., & Saini, R. V. (2020). *Datura stramonium* essential oil composition and it's immunostimulatory potential against colon cancer cells. 3 *Biotech*, 10, 1-14. <https://doi.org/10.1007/s13205-020-02438-4>

- Chatterjee, S. (2016). Oxidative stress, inflammation, and disease. In *Oxidative stress and biomaterials* (pp. 35-58). Academic Press. <https://doi.org/10.1016/B978-0-12-803269-5.00002-4>
- Choudhary, M., Sharma, I., Agrawal, D. C., Dhar, M. K., & Kaul, S. (2021). Neurotoxic potential of alkaloids from thorn apple (*Datura stramonium* L.): A commonly used Indian folk medicinal herb. *Medicinal Herbs and Fungi: Neurotoxicity vs. Neuroprotection*, 391-420. DOI https://doi.org/10.1007/978-981-33-4141-8_16
- Crossman, A. R., & Neary, D. (2018). *Neuroanatomy E-book: an illustrated colour text*. Elsevier Health Sciences.
- Dey, P. (2018). *Basic and advanced laboratory techniques in histopathology and cytology*. Springer Singapore.
- Ekanem, P. E., Ekanem, R., & Gaim, K. (2016). Histological patterns of neurodegeneration of frontal cortex neurons in *Datura stramonium* treated Wistar rats. *Journal of Behavioral and Brain Science*, 6(2), 85-92. DOI: [10.4236/jbbs.2016.62009](https://doi.org/10.4236/jbbs.2016.62009)
- Firdaus, N., Viquar, U., & Kazmi, M. H. (2020). Potential and pharmacological actions of *Datura* safed (*Datura metel* L.): as a deadly poison and as a drug: an overview. *International Journal of Pharmaceutical Sciences and Research*, 11(7), 3123-3137. Doi: 10.13040/IJPSR.0975-8232.11(7).3123-37
- Forstmann, B. U., Keuken, M. C., & Alkemade, A. (2015). An introduction to human brain anatomy. *An introduction to model-based cognitive neuroscience*, 71-89. ISBN : 978-1-4939-2235-2
- Gad-Elkareem, M. A., Abdelgadir, E. H., Badawy, O. M., & Kadri, A. (2019). Potential antidiabetic effect of ethanolic and aqueous-ethanolic extracts of *Ricinus communis* leaves on streptozotocin-induced diabetes in rats. *PeerJ*, 7, e6441.
- Gartner, L. P. (2020). *Textbook of Histology E-Book: Textbook of Histology E-Book*. Elsevier Health Sciences.
- Ghaleb, S. S., Elroby, F. A., Mahmoud, H. S., Ahmad, M. A., Sharaf, R. M., & Sharkawi, S. M. (2019). Pro-oxidant effect of vitamin c with chronic monosodium glutamate organ toxicity in albino rats. *International Journal of Medical Toxicology & Legal Medicine*, 22(3and4), 165-171.
- Gunasegaran, J. P. (2016). *Textbook of Histology and A Practical guide-E-Book*. Elsevier Health Sciences.
- Gurina, T. S., & Simms, L. (2020). Histology, staining.
- Holzman, R. S. (2021). The history of sedation. *Pediatric Sedation Outside of the Operating Room: A Multispecialty International Collaboration*, 3-19.
- Kadam, S. D., Chavhan, S. A., Shinde, S. A., & Sapkal, P. N. (2018). Pharmacognostic review on *Datura*. *Research Journal of Pharmacology and Pharmacodynamics*, 10(4), 171-178.
- Kaushik, B., Sharma, J., Kumar, P., & Shourie, A. (2021). Phytochemical properties and pharmacological role of plants: secondary metabolites. *Biosciences Biotechnology Research Asia*, 18(1), 23. <http://dx.doi.org/10.13005/bbra/2894>
- Knoblauch, S. E., Adissu, H. A., McKerlie, C., & Cardiff, R. D. (2021). Male reproductive system. *Pathology of Genetically Engineered and Other Mutant Mice*, 431-461.

- Kontoghiorghes, G. J., Kolnagou, A., Kontoghiorghe, C. N., Mourouzidis, L., Timoshnikov, V. A., & Polyakov, N. E. (2020). Trying to solve the puzzle of the interaction of ascorbic acid and iron: Redox, chelation and therapeutic implications. *Medicines*, 7(8), 45. <https://doi.org/10.3390/medicines7080045>
- Kowalczyk, P., Sulejczak, D., Kleczkowska, P., Bukowska-Oško, I., Kucia, M., Popiel, M., ... & Kaczyńska, K. (2021). Mitochondrial oxidative stress—a causative factor and therapeutic target in many diseases. *International journal of molecular sciences*, 22(24), 13384. <https://doi.org/10.3390/ijms222413384>
- Lawal, B. A., Ayipo, Y. O., Adekunle, A. O., Amali, M. O., Badeggi, U. M., Alananzeh, W. A., & Mordi, M. N. (2023). Phytoconstituents of *Datura metel* extract improved motor coordination in haloperidol-induced cataleptic mice: Dual-target molecular docking and behavioural studies. *Journal of Ethnopharmacology*, 300, 115753. <https://doi.org/10.1016/j.jep.2022.115753>
- MD, A. L. K. (2019). *Histology and cell biology: An introduction to pathology*. Elsevier Canada.
- Mohanlall, V., & Ally, F. (2020). An overview of tropane alkaloids from *Datura stramonium* L. *Journal of Pharmacognosy and Phytochemistry; Vol. 9, Issue 3*. <https://hdl.handle.net/10321/3427>
- Mukhtar, Y., Tukur, S., & Bashir, R. A. (2019). An Overview on *Datura stramonium* L. (Jimson weed): A Notable Psychoactive Drug Plant. *American Journal of Natural Sciences*, 2(1), 1 - 9. <https://doi.org/10.47672/ajns.423>
- Nayak, R. (2017). *Histopathology techniques and its management*. JP Medical Ltd.
- O'Dowd, G., Bell, S., & Wright, S. (2023). *Wheater's Functional Histology, E-Book: A Text and Colour Atlas*. Elsevier Health Sciences.
- Pehlivan, F. E. (2014). Effects of exogenously applied ascorbic acid on red cabbage cotyledons subjected to copper excess. *Fresenius Environmental Bulletin*, 2014, Vol. 23, No. 8, 1812-1815 ref. 21
- Pehlivan, F. E. (2017). Vitamin C: An antioxidant agent. *Vitamin C*, 2, 23-35. <http://dx.doi.org/10.5772/intechopen.69660>
- Sanni, M., Ejembi, D. O., Abbah, O. C., Olajide, J. E., Ayeni, G., & Asoegwu, C. M. (2014). Studies on the phytochemical screening and deleterious effects of aqueous extract of *Datura stramonium* on albino rats. *World Journal of Pharmaceutical research*, 3(6), 1110-36.
- Santos-Sánchez, N. F., Salas-Coronado, R., Villanueva-Cañongo, C., & Hernández-Carlos, B. (2019). Antioxidant compounds and their antioxidant mechanism. *Antioxidants*, 10, 1-29. <http://dx.doi.org/10.5772/intechopen.77838>
- Shakya, A. K. (2016). Medicinal plants: Future source of new drugs. *International journal of herbal medicine*, 4(4), 59-64.
- Sharma, M., Dhaliwal, I., Rana, K., Delta, A. K., & Kaushik, P. (2021). Phytochemistry, pharmacology, and toxicology of *Datura* species—A review. *Antioxidants*, 10(8), 1291. <https://doi.org/10.3390/antiox10081291>

- Shekhar, P., Joshi, A., Malviya, S., & Kharia, A. (2017). Wound healing activity of the hydro-alcoholic extract of datura stramonium leaves in wistar albino rats. *Journal of Drug Delivery and Therapeutics*, 7(7), 214-215. DOI <https://doi.org/10.22270/jddt.v7i7.1641>
- Singh, D. B., Pathak, R. K., & Rai, D. (2022). From traditional herbal medicine to rational drug discovery: strategies, challenges, and future perspectives. *Revista Brasileira de Farmacognosia*, 32(2), 147-159. <https://doi.org/10.1007/s43450-022-00235-z>
- Singh, V. (2020). *Textbook of Clinical Neuroanatomy-E-Book*. Elsevier Health Sciences.
- Singh-Bains, M. K., Mehrabi, N. F., Tan, A. Y., Faull, R. L., & Dragunow, M. (2021). Preparation, construction and high-throughput automated analysis of human brain tissue microarrays for neurodegenerative disease drug development. *Nature Protocols*, 16(4), 2308-2343.
- Srivastava, R., & Srivastava, P. (2020). The medicinal significance of Datura stramonium-A review. *Biomedical Journal of Scientific & Technical Research*, 29(2), 22223-22226. DOI: [10.26717/BJSTR.2020.29.004761](https://doi.org/10.26717/BJSTR.2020.29.004761)
- Ugboko, H. U., Nwinyi, O. C., Oranusi, S. U., Fatoki, T. H., & Omonhinmin, C. A. (2020). Antimicrobial importance of medicinal plants in Nigeria. *The Scientific World Journal*, 2020 | Article ID 7059323 | <https://doi.org/10.1155/2020/7059323>
- Winsor, L., & Sluys, R. (2018). Basic histological techniques for planarians. *Planarian regeneration: Methods and protocols*, 285-351.
- Yu, L. Q., Kan, I. P., & Kable, J. W. (2020). Beyond a rod through the skull: A systematic review of lesion studies of the human ventromedial frontal lobe. *Cognitive neuropsychology*, 37(1-2), 97-141.