

## Case study

### **Ebstein anomaly in an adolescent: A ‘Miranda warning’ against blaming Sickle Cell Cardiomyopathy - A case-based scholarly update**

**Commented [I1]:** The title is engaging and effectively highlights the complexity and importance of differentiating Ebstein anomaly (EA) from sickle cell cardiomyopathy (SCC) in clinical practice, to be more concise consider revising to: "Ebstein Anomaly in an Adolescent: Challenges in Differentiating from Sickle Cell Cardiomyopathy."

#### **Abstract**

##### **Background**

Ebstein's anomaly (EA) is a rare congenital heart disease characterized by apical displacement of the tricuspid valve associated with atrialization of the right ventricle. The defect arises from failure of the normal process by which the tricuspid valve is separated from the right ventricular myocardium. Most cases are diagnosed in childhood, but asymptomatic ones may remain undiagnosed until adulthood.

##### **Case Summary**

We present a rare case of EA diagnosed for the first time in a 13-year-old female sickle cell anaemia patient when she developed biventricular heart failure with severe tricuspid regurgitation and biventricular thrombi which was managed medically; however, patient died 17 days into admission.

##### **Conclusion**

The Ebstein anomaly can present in adolescents for the first time and is usually associated with pericardial effusion and ventricular thrombi. Due to its similarity in presentation to sickle cell cardiomyopathy, it can be missed in sickle cell anaemia patients. Echocardiography can help unravel this diagnostic dilemma.

**Keywords:** Biventricular Thrombi, Congenital heart defects, Diagnostic dilemma, Ebstein's anomaly, Echocardiography.

##### **Introduction**

Ebstein's anomaly (EA) is a rare congenital heart disease which occurs in approximately one per 20,000 live births and accounts for <1% of congenital cardiac diseases.<sup>1</sup> It presents with apical displacement of the septal and posterior leaflets of the tricuspid valve.<sup>2</sup> The anterior leaflet is large

**Commented [I2]:** The authors can consider rephrasing for better flow. For example: "Ebstein's anomaly (EA) is a rare congenital heart disease, occurring in approximately one per 20,000 live births and accounting for less than 1% of congenital cardiac diseases. Characterized by the apical displacement of the septal and posterior leaflets of the tricuspid valve, EA often features a large, redundant anterior leaflet described as 'Sail-like,' which may include fenestrations contributing to tricuspid regurgitation (TR). This anomaly results from a developmental failure to properly separate the tricuspid valve from the right ventricular myocardium."

Again the authors can expand on why EA can be mistaken for sickle cell cardiomyopathy. A brief comparative analysis would be beneficial: e.g. "The clinical manifestations of EA are highly variable, depending on factors such as the extent of tricuspid valve displacement and the severity of right ventricular outflow tract obstruction, along with associated malformations. This variability often leads to delayed diagnosis, with symptoms sometimes not appearing until teenage years or young adulthood. Moreover, the condition's complexities can mimic other cardiac disorders, notably sickle cell cardiomyopathy, due to overlapping clinical presentations such as heart failure and arrhythmias."

and redundant, hence, described as “Sail-like” and may feature fenestrations, contributing to the tricuspid regurgitation (TR).<sup>3</sup> The defect arises from failure of the normal process by which the tricuspid valve is separated from the right ventricular myocardium.<sup>2</sup> Clinical manifestations are highly variable and depend on the extent of displacement of the tricuspid valve, the severity of right ventricular outflow tract obstruction and its associated malformations.<sup>4</sup> In many patients, the symptoms are mild and may be delayed until the teenage years or young adult life. However, due to its variability in clinical presentation and age of presentation; with its associated complexities, it mimics a lot of cardiac disorders, one of which is sickle cell cardiomyopathy. The apical four chamber view is the preferred echocardiographic plane for evaluation.

#### Case Presentation

The patient was a 13-year-old female sickle cell anaemia (SCA) patient was diagnosed at 8 years of life but had since defaulted follow-up. She was referred from an NGO facility with a history of recurrent fever and cough of 2 months. Fever was low on and off, cough, which was nonproductive, non-barky or paroxysmal associated with bluish discoloration of the lips and had associated dyspnea on mild to moderate exertion for 2 months. There was an associated 6-week history of palpitations. The symptoms occurred at rest, 3-4 times per week, with no easy fatigability nor orthopnea. The patient did not report any previous heart disease and had only received folic acid and palludrine since diagnosis of SCA. She had been transfused in a primary health care facility on 5 different occasions in the past, last transfusion was 2 weeks prior to presentation. On examination, an acutely ill-looking child, in respiratory distress, afebrile, jaundiced, not pale, cyanosed, not dehydrated, no peripheral oedema, has grade III finger clubbing. She weighs 30kg (below 5th centile) and has a height of 144cm (between 10th and 25<sup>th</sup> centiles). Dyspneic with flaring of ala nasi and subcostal recession, and tachypneic with RR 30 c/m, SpO<sub>2</sub> of 82% in room

**Commented [I3]:** The introduction would benefit from incorporating more recent studies or reviews. This would provide up-to-date context and highlight ongoing advancements in the understanding and diagnosis of EA.

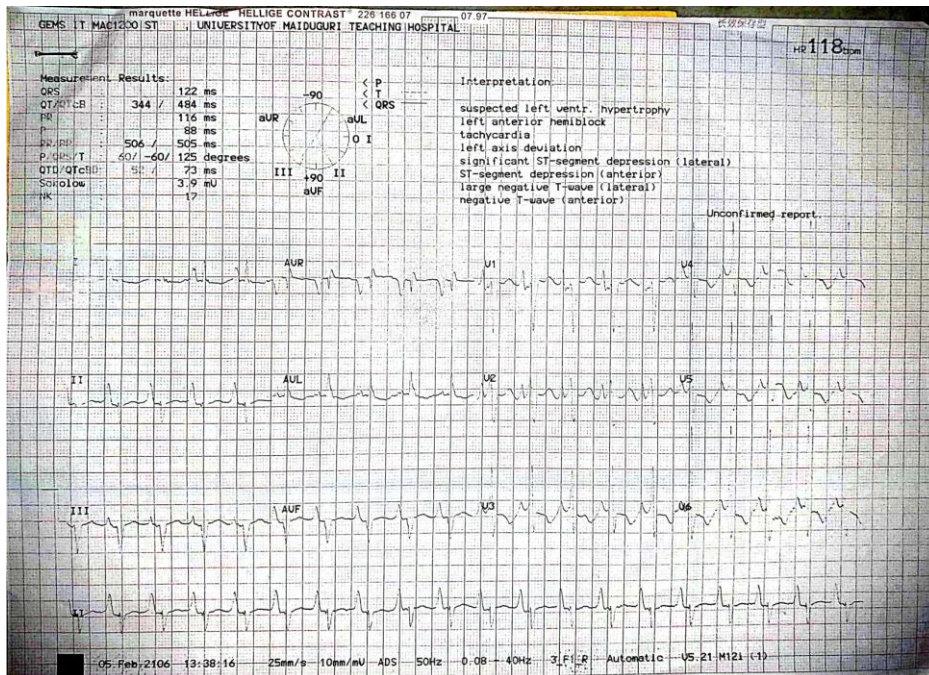
**Commented [I4]:** The mention of EA mimicking other cardiac disorders, particularly sickle cell cardiomyopathy, is crucial but could be expanded. For journal readers, a brief overview of why these conditions can be confused (e.g., shared symptoms, overlapping clinical presentations) would enhance the reader's understanding.

air. There was equal chest expansion bilaterally, the percussion notes were resonant and had clear lung fields. Although tachycardic (PR 186c/min), her BP (106/76mmHg) was within normal limits. The JVP was raised, had a hyperactive precordium and the apex was also displaced (6th ICS anterior axillary line). The heart sounds were normal but had associated Grade III holosystolic murmur loudest at the lower left sternal border. Abdomen was slightly distended with moderate ascites demonstrable by shifting dullness and had a firm, smooth and tender liver (hepatomegaly 6cm below the RCM).

The patient was initially evaluated for suspected desiminated tuberculosis (PTB and TB adenitis with moderate pleural effusion in a SCA patient, to rule out sickle cell cardiomyopathy. An electrocardiogram (ECG) revealed normal sinus rhythm, a tall p wave which suggests right atrial enlargement, a delta wave due to preexcitation from an accessory pathway, and a widened QRS complex (Figure 1). Chest USS showed mild-moderate pericardial fluid collection.

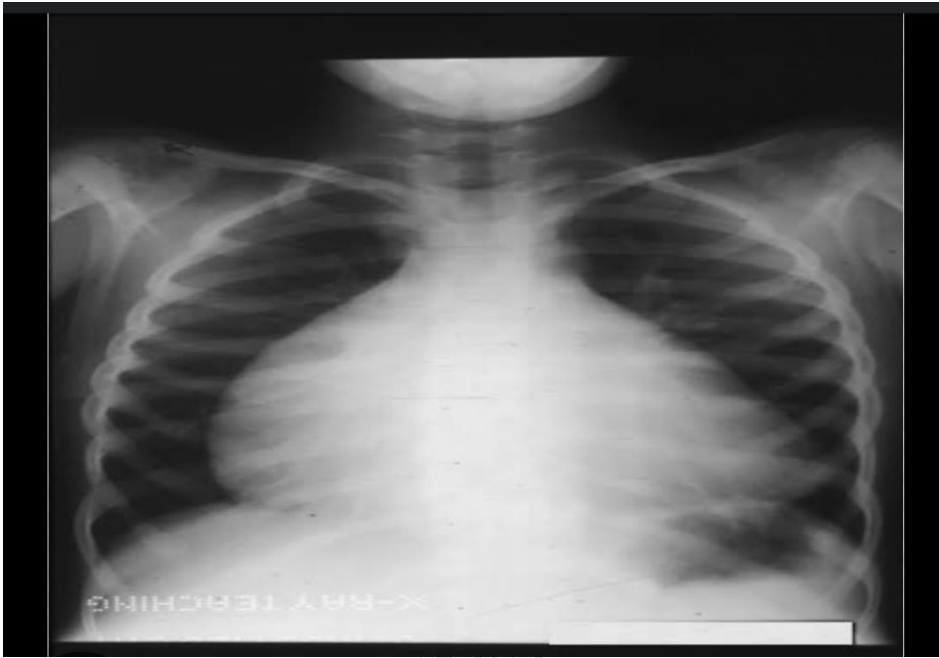
**Commented [15]:** While the findings from the ECG and chest ultrasound are described, interpreting these findings in the context of the differential diagnosis would be beneficial. The authors should explain how these findings led to the suspicion of EA and the rationale for ruling out other conditions like sickle cell cardiomyopathy and tuberculosis!

Integrate the diagnostic findings with the clinical picture. For example: "The ECG revealed normal sinus rhythm with a tall P wave, suggestive of right atrial enlargement, and a delta wave due to pre excitation from an accessory pathway, which, along with the widened QRS complex, raised suspicion for EA. The chest ultrasound showed mild to moderate pericardial fluid collection, supporting the diagnosis of EA over sickle cell cardiomyopathy."



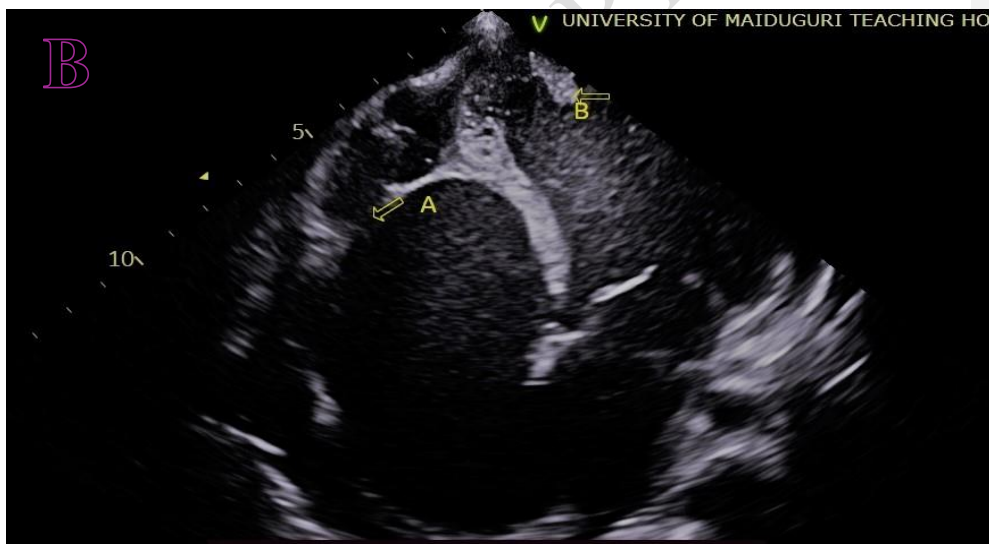
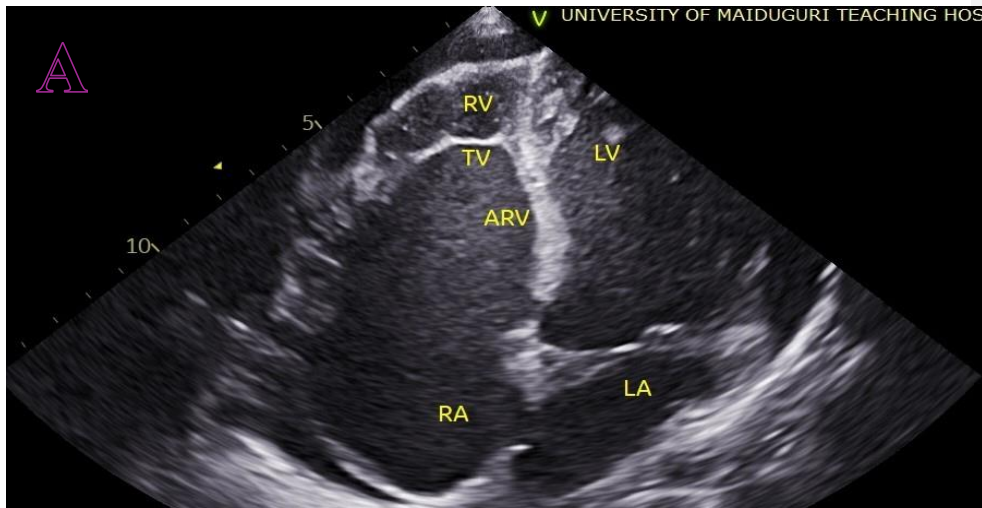
**Figure 1:** ECG revealed features consistent with Ebstein's Anomaly.

Chest radiograph showed an enlarged cardiac silhouette (cardiothoracic ratio: 0.67), resulting from enlarged right chambers. The pulmonary vascular network was slightly decreased, and the aortic knob was prominent (Figure 2).



**Figure 2:** Chest radiograph showing cardiomegaly with right sided chamber enlargement and prominent aortic knob.

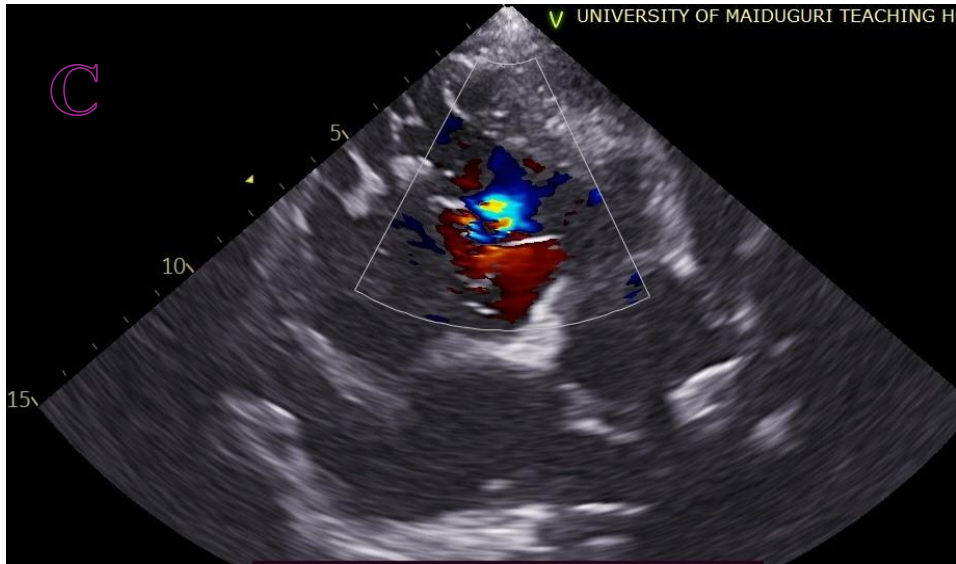
Transthoracic echocardiography demonstrated the presence of EA :the tricuspid valve was apically displaced, and formation of an “atrialized” right ventricle. There is an associated left ventricular thrombus (Figure 3A & 3B)



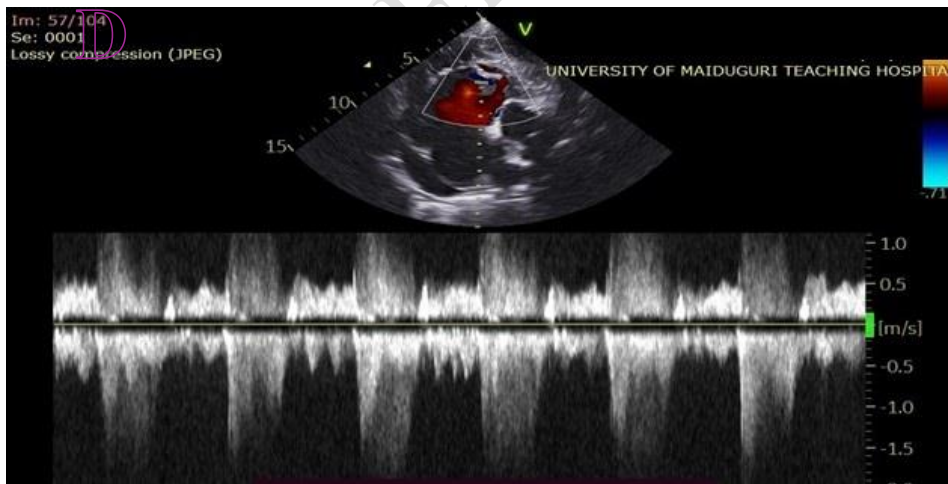
**Figure 3A:** Apical 4 chamber view showing Apical displacement of tricuspid valve with enlarged right atrium, "Atrialized" right ventricle and small "functional" right ventricle.

RV (Right ventricle), TV (Tricuspid valve), ARV (Atrialised' right ventricle), RA (Right atrium), LA (Left atrium), LV (Left ventricle).

**Figure 3B:** A: Tricuspid septal leaflet, B: LV thrombus.



**Figure 3C:** Parasternal short axis view at base. Colour doppler through the tricuspid valve showing tricuspid regurgitant jet.



**Figure 3D:** Continuous-wave spectral Doppler profiles through Tricuspid valve demonstrating a low-velocity jet with triangular jet profile indicating severe tricuspid regurgitation jet.

Other laboratory investigations showed the packed cell volume ranged between 33-37%, INR of 1.1 to 1.9 over the period of admission. All screenings for tuberculosis (sputum gene Xpert MTB/RIF, Mantoux test) were negative.

The patient was placed on treatment for heart failure according to the guideline-directed medical therapy using frusemide, carvedilol and enalapril. Placed on intranasal oxygen and subcutaneous Clexane at 30mg 12hrly X 5/7 and tabs warfarin 5mg od X 2/52 as per protocol.<sup>5</sup>

The patient's condition had clinically improved 16 days into admission and was out of heart failure, clinically. However, the patient developed a sudden episode of breathlessness and collapsed on her way to the bathroom. All resuscitative measures were not successful and was certified death. No permission for autopsy was granted postmortem by the parents; the child probably died from a thromboembolic phenomenon or paroxysmal tachyarrhythmia.

## Discussion

This report demonstrates the fact that patients with a long-standing condition and diagnostic dilemma may present to a secondary care facility without appropriate diagnostic tools like Potiskum General Hospital in Yobe State Northeast region of Nigeria that is devastated by insurgency, resulting in a delay in diagnosis and management. Diagnosis of EA is commonly made in younger children. It usually presents with features of heart failure and arrhythmia but can also have rare associations like pericardial effusion and biventricular thrombi as was seen in the index case. Diagnosis in older children can be challenging, especially in comorbid conditions like sickle cell anaemia, because EA can mimic sickle cell cardiomyopathy as seen in our patient. Although very rare, it can present in such patients as a comorbidity. A high index of suspicion and imaging is important in making a diagnosis.

Although survival has significantly improved in the last four decades, **the diagnosis of Ebstein's anomaly** is still associated with a 20-fold increased risk of mortality.<sup>6</sup> The main pathologic finding of EA is apical displacement of the tricuspid septal leaflet which our patient had. The diagnosis was confirmed after a thorough review of history, examination, and investigations (including

**Commented [16]:** The authors can consider organizing the content into clear subsections, such as "Diagnostic Challenges," "Prognostic Indicators," "Management Strategies," and "Implications for Resource-Limited Settings."

**Commented [17]:** Some points are repeated, such as the difficulty in diagnosing EA in the presence of comorbidities like SCA. Streamlining these points could make the discussion more concise and impactful.

echocardiography) in our patient. Common associations of EA include interatrial communication, patent foramen ovale, ventricular septal defect, and distal right ventricle anomalies.<sup>2</sup> The index patient had atrial septal defect. Clinical presentation is variable and depends on the degree of tricuspid valve malformation and associated cardiac anomaly. In infants, common presentation is usually an incidental murmur or insipient heart failure while in adolescents, presentation is usually with arrhythmias.<sup>7</sup> Poor prognostic indicators include male sex, cyanosis, Haemoglobin > 15 g/dL, heart failure, CRT  $\geq$  0.65 (index case had 0.67), atrial arrhythmia, Severe TR, intracardiac thrombi (index case had biventricular thrombi), and coronary artery disease.<sup>8</sup> Prior to our patient's demise, the prognosis was deemed unfavourable based on the aforementioned criteria.

Ebstein anomaly may pose a diagnostic dilemma in SCA presenting for the first time with heart failure in adolescent due to variability in its clinical presentation and rarity hence the clinical suspicion of its alternative diagnosis as SCA cardiomyopathy as suggested in our patient. Furthermore, chronic anaemia with repeated blood transfusions in her clinical history was a pointer to suggest that a causal relationship might exist. **This could have led to iron overload; the excess iron released into the circulation, causing saturation of the carrying capacity of transferrin, and non-transferrin bound iron (NTBI) will appear in the serum. This free iron is taken up by cells of various organs, including the heart: this increases reactive oxygen species production and causes cellular damage.**<sup>9</sup> Heart damage occurring due to the above-mentioned mechanism causes a unique form of cardiomyopathy. An infiltrative/restrictive cardiomyopathy with defining features as diastolic dysfunction, LA enlargement, and normal systolic function along with LV enlargement. Nevertheless, echocardiographic findings differentiate it from EA and thus, may assist in delineating the various pathologies specific to each disease state.

**Commented [18]:** For the journal readers; while the mechanism of iron overload leading to cardiomyopathy is discussed, it would be helpful to briefly explain why this is relevant to the differential diagnosis and how it specifically contrasts with the pathology of EA!

Definitive diagnosis of EA is made quantitatively when there is an apical displacement of the septal leaflet hinge point by at least 8 mm/M<sup>2</sup> from the anterior mitral leaflet insertion, assessed in a four-chamber view.<sup>10</sup> Multimodality imaging is key not only for anatomical and functional assessment of tricuspid valve and right-sided chambers but also for identifying associated lesions.

Transthoracic echocardiography (TTE) is usually the first diagnostic tool that is mostly effective and is available in our facility which we utilised. Second-line imaging includes transoesophageal echocardiography and cardiovascular magnetic resonance; the former with particular usefulness in TV assessment, the latter in right-sided chamber volumes calculation and myocardial characterisation. Our patient had only TTE as other imaging modalities were not available in our centre.

Multiple specialists evaluated our patient; Paediatric Haematologist, and cardiologist.

The effect of medical therapy on patients with EA has not yet been solidly investigated.<sup>11</sup> Medical therapy is individualised based on the patient's clinical presentation. Our patient had congestive cardiac failure and ventricular thrombi which were treated as per protocol.<sup>5</sup> However, even the decision for a definitive surgical treatment in EA is difficult due to the wide spectrum of the disease.<sup>4</sup>

Ebstein anomaly is associated with increased prevalence of atrial arrhythmias with or without an accessory pathway, predominantly paroxysmal supraventricular tachycardia. Our patient had pre-excitation suggested by the ECG. Atrial fibrillation and flutter and a smaller percentage of patients with paroxysmal ventricular tachyarrhythmias are also seen. Sudden cardiac death due to arrhythmias has been reported.<sup>12</sup>

**Commented [19]:** The section on multimodality imaging could be expanded to briefly describe the specific advantages and limitations of each imaging modality (TTE, transoesophageal echocardiography, and cardiovascular magnetic resonance) in diagnosing EA, the report usually carry a key message for the readers and the workup should be highlighted with a clear consensus.

**Commented [10]:** As a key message, detail the challenges in diagnosing EA, particularly in resource-limited settings and in patients with comorbid conditions like SCA should be clarify for the readers.

## Conclusion

Ebstein Anomaly can be complicated by congestive heart failure and ventricular thrombi in a SCA patient. A multispecialty review for a definitive diagnosis of EA, highlights the importance of accurate diagnosis using echocardiography in the likelihood of close differential diagnoses; this would have allowed for prompt care to prevent thrombus formation in resource-limited settings, had the patient presented earlier at a younger age as SCA cardiomyopathy was being blamed at lower-level health care centre.

**Commented [11]:** Please highlight the practical implications of the case, particularly for healthcare providers in similar resource-limited settings.

## References

1. Gotzsche H, Falholt W. Ebstein's anomaly of the tricuspid valve; a review of the literature and report of 6 new cases. *Am Heart J.* 1954; **47**: 587–603.”
2. Soham Shah, Trevor Jenkins, Alan Markowitz, Robert Gilkeson, Prabhakar Rajiah. Multimodal imaging of the tricuspid valve: normal appearance and pathological entities. *Insights Imaging* 2016; **7(5)**: 649–67. doi: 10.1007/s13244-016-0504-7 PMID: 27278389
3. Da Fonseca da Silva L, Devine WA, Alsaied T, Yeh J, Ivy Lin J-H, Da Silva J. Ebstein's Anomaly. In: *Congenital Heart Defects. Recent Advances.* Intech Open 2022.
4. Anita Saxena, Jay Relan, Ravi Agarwal, Neeraj Awasthy, Sushil Azad, Manisha Chakrabarty. et al. Indian guidelines for indications and timing of intervention for common congenital heart diseases: Revised and updated consensus statement of the Working group on management of congenital heart diseases. *Ann Pediatr Cardiol.* 2019; **12(3)**: 254–286. doi: 10.4103/apc.APC\_32\_19 PMID: 31516283

5. Santos BB, Heineck I, Negretto GW. Use of Warfarin in Pediatrics: Clinical and Pharmacological characteristics. *Rev Paul Pediatr* 2017; **35(4)**: 375-82. doi:10.1590/1984.0462
6. Geerdink L, Kapusta L. Dealing with Ebstein's anomaly. *Cardiol Young*. 2013; **24**: 191–200
7. Giglia TM, Massicotte MP, Tweddell JS, Barst RJ, Bauman M, Erickson CC, *et al*. American Heart Association Congenital Heart Defects Committee of the Council on Cardiovascular Disease in the Young, Council on Cardiovascular and Stroke Nursing, Council on Epidemiology and Prevention, and Stroke Council. Prevention and treatment of thrombosis in pediatric and congenital heart disease: a scientific statement from the American Heart Association. *Circulation* 2013; **128(24)**: 2622-703. doi: 10.1161/01.cir.0000436140.77832.7a. Erratum in: *Circulation*. 2014 Jan 14; *129(2)*: e23. PMID: 24226806.
8. Attie F, Rosas M, Rijlaarsdam M, Buendia A, Zabal C, Kuri J, *et al*. The adult patient with Ebstein anomaly. Outcome in 72 unoperated patients. *Medicine (Baltimore)* 2000; **79**: 27-36.
9. Gordan R, Wongjaikam S, Gwathmey JK, Chattipakorn N, Chattipakorn SC, Xie L-H. Involvement of cytosolic and mitochondrial iron in iron overload cardiomyopathy: an update. *Heart Fail Rev*. 2018; **23**: 801–16.
10. Attenhofer Jost CH, Edmister WD, Julsrud PR, Dearani JA, Savas Tepe M, Warnes CA; *et al*. Prospective comparison of echocardiography versus cardiac magnetic resonance imaging in patients with Ebstein's anomaly. *Int J Cardiovasc Imaging* 2012; **28**: 1147–59

11. Pasqualin G, Boccellino A, Chessa M, Ciconte G, Marcolin C, Micaglio E, *et al.*  
Ebstein's anomaly in children and adults: multidisciplinary insights into imaging and therapy *Heart* 2024; **110**: 236–245.
12. He BJ, Merriman AF, Cakulev I, Stambler BS, Srivastava D, Scheinman MM.  
Ebstein's Anomaly. *JACC Clin Electrophysiol* 2021; **7(9)**: 1198-206.

UNDER PEER REVIEW