

The Value of 2D Global Longitudinal Strain in Predicting the Severity of Coronary Artery Disease in Patients with NSTEMI and Unstable Angina and regional strain value for predicting the culprit artery

ABSTRACT

Background: Our study aimed to evaluate the predictive ability of resting strain to determine the severity of CAD in the absence of impaired LVEF in patients with NSTEMI and unstable angina. Additionally, the study sought to predict culprit and infarcted related artery (IRA) using regional strain (SLR).

Methods: The study was conducted between January 2023 and May 2023 at the cardiology department of Ibn Rochd Hospital, Morocco. We conducted a comparative analysis involving 30 patients, comprising 23 individuals with NSTEMI and 7 with unstable angina. In all cases, we assessed both GLS and RLS before proceeding to coronary angiography. Subsequently, we categorized the patients into two groups: one consisted of 18 individuals with severe coronary lesions, including left main trunk (LM) and three vessels lesions, while the other group, comprising 12 patients, served as the control group and had non-severe coronary lesions

Results: At resting GLS threshold below **-16,3 %**, despite its subnormal nature, should raise suspicion and suggest severe coronary artery disease. RLS in the "Single-vessel" group was significantly lower in the culprit artery territories, suggesting that RLS may be a better marker for identifying the culprit artery. Both GLS and the visual analysis of segmental kinetics by WMSI (Wall Motion Score Index) at rest, were statistically significant for detecting severe coronary lesions.

Conclusion: GLR and SLR are sensitive markers for early detection of myocardial ischemia and predicting its severity. A resting GLR threshold of less than -16.13% could indicate severe CAD with severe tri-truncular or LMT damage, especially when combined with abnormal WMSI scores. These 2D strain parameter changes precede subjective abnormalities in segmental kinetics, which are often considered normal at rest.

Key words: Coronary artery disease; Diabetes mellitus; Global longitudinal strain; Speckle tracking.

INTRODUCTION

The aim of this study is to assess the effectiveness of global 2D strain imaging in detecting and quantifying myocardial ischemia at rest, specifically to differentiate severe coronary artery disease (CAD) of the tri vessels and left main CAD (LMT) type from non-severe mono- or bi-vessel disease in patients with NSTEMI and unstable angina. Traditionally, the non-invasive echocardiographic detection of myocardial ischemia in CAD, especially severe disease, requires a stress test because abnormalities in segmental kinetics are often not present at rest [1,10-12]. However, recent studies have shown that 2D strain imaging has good sensitivity in detecting CAD at rest, even in cases where segmental kinetics are normal and left ventricular ejection fraction (LVEF) is within the normal range at baseline.

MATERIALS AND METHODS

1. AIM OF THE STUDY:

Our aim in this study was to evaluate the ability of resting 2D global strain to predict the severity of Coronary artery disease (CAD) in patients with NSTEMI and unstable angina by distinguishing the severe lesions defined by tree vessel lesions and left main lesions from one or two vessel CAD involvement. Also, to predict the infarcted related artery (IRA) by regional strain (SLR).

2. STUDY POPULATION

We conducted a prospective, longitudinal, evaluative study between January 2023 and May 2023 in the cardiology department of IBN ROCHD UNIVERSITY HOSPITAL OF CASABLANCA- MOROCCO. In this study, we compared data of 30 patients, including 23 patients with NSTEMI and 7 patients with unstable angina.

We conducted a comparative analysis involving 30 patients, comprising 23 individuals with NSTEMI and 7 with unstable angina. In all cases, we assessed both GLS and RLS before proceeding to coronary angiography. Subsequently, we categorized the patients into two groups (Figures N°1) :

- One consisted of 18 individuals with severe coronary lesions, including 5 patients with left main lesions (defined on coronary angiography by a significant lesion \geq 50% of the left main coronary artery); and 13 patients with three vessel lesions (defined on coronary angiography by a significant lesion \geq 70%).
- While the other group, comprising 12 patients, served as the control group and had non-severe coronary lesions defined by one and two vessel CAD.

The study participants were predominantly male, with a rate of 67.9% (n/N=19/30), compared with 28% (n/N=11/30) who were female. The average age of the participants was 62 years, with extremes ranging from 81 years to 60 years.

The exclusion criteria were simple and included: Unstable angina, Non-ST elevation myocardial infarction (NSTEMI) , Preserved LVEF while the exclusion criteria included Significant intercurrent pathologies that could potentially affect the strain study, such : (1) History of myocardial infarction (MI) and/or Percutaneous Coronary Intervention (PCI) or Coronary Artery Bypass Grafting (CABG), ST elevation coronary syndrome (STEMI) or post-MI, and chronic coronary syndrome. (2) left ventricular ejection fraction (LVEF) below 50%. (3) Individuals with congestive heart failure and haemodynamic instability. (4) significant mitral or aortic valve disease, arrhythmia, hypertrophic cardiomyopathy (septal, wide QRS \geq 120 ms, or pericardial involvement. (5) Patients whose echocardiographic images were not suitable for the evaluation of 2D strain parameters were excluded from the study. (6) The "control" group excluded individuals with a combination of significant stenoses of the proximal left anterior descending artery (LAD) and proximal circumflex artery (CX) to avoid potential confusion at the pathophysiological level with those of the three vessels and left main CAD

3. ECHOCARDIOGRAPHY:

On admission, a transthoracic echocardiography (TTE) was performed using a General Electric ViVid S70N machine. The TTE utilized a 2.5-5 MHz transducer and an M5s matrix probe while simultaneously recording the electrocardiogram. The imaging was conducted in apical views (including 4, 2, and 3 cavity slices) using two-dimensional loops. In addition to the standard echocardiography assessment, segmental parietal kinetics were evaluated based on the recommended segmentation of 17 segments established by the latest guidelines from American and European cardiology societies [2]. The wall motion score index (WMSI) was calculated by summing the individual WMSi values of each of the 17 segments analyzed and dividing by the total number of segments (17). The regional wall motion score index in the territories of the three main epicardial coronary arteries was calculated based on the allocation of segments to the corresponding coronary artery distributions [8].

4. CORONARY ANGIOGRAPHY (CA) :

Coronary Angiography (CA) was performed by the percutaneous femoral and radial approach. CA were obtained for each coronary vessel in 2 projections, and stenosis with 70% reduction in the lumen of the epicardial arteries and 50% for the LM trunk, was considered significant. The interpretation of the angiograms loops was performed visually by an experienced coronarographiste.

5. STATISTICAL ANALYSIS

All analyses were made using the “SPSS 17 for Mac” software package. Continuous variables were expressed as mean \pm standard deviation; categorical variables were expressed as percentages. Independent T-test was used to compare means, ANOVA to compare multiple groups. Chi-square test was used to compare percentages. Pearson’s correlation coefficients

were used to assess the strength of relationship between continuous variables. ROC curve was plotted to get cutoff value, sensitivity and specificity. We used multiple linear regression analysis, A p value of less than 0.05 was considered significant.

6. Ethics:

An informed written consent was obtained from each patient according to the declaration of Helsinki and the rules of the Local Ethics Committee of Faculty of Medicine, Ibn Rochd University hospital, Morocco.

RESULTS

Of the 30 patients participating in the study, 13 patients (or 43% of participants) had three vessel CAD and 5 patients (or 17%) had Left main CAD. In the "control" group 8 patients (or 13% of the participants) had one vessel CAD lesions and 27% (or 4 patients) had two vessel CAD lesions (Table 1). The two groups had similar age distributions. However, there was a male predominance in the group with severe lesions, specifically in cases involving left main CAD and three-vessel CAD, as shown in Table 1 . concern comorbidities, the severe lesions group exhibited a higher prevalence of comorbid conditions, with diabetes being particularly prominent. We categorized these patients as fertility patients (Table 1) .

The analysis of 2D strain echocardiography data revealed a significantly lower Global Longitudinal Strain (GLS) in both the subgroups "three vessels, LM CAD" groups (15.9% and 16.63% respectively) compared to the control group "one and two vessel CAD " (24.3% and - 22% respectively). The reduction in GLS in the subgroup of three vessels lesions correlated with a decrease in Segmental Longitudinal Radial (SLR) strain in the territories of LAD, CX, and RCA. However, in the "LM stenosis" group, SLR was lower only in LAD and CX territories.(Table 2)

Multivariate logistic regression analysis found that the most predictive parameter for severity of CAD is GLS cutoff -16.13%. SLR in the "one vessel " subgroup was significantly lower in the territories of the culprit arteries, suggesting it may be a better marker for determining the culprit artery. Global Longitudinal Strain (GLS) and visual analysis along with semi-quantitative analysis of segmental kinetics using the Wall Motion Score Index (WMSI) at rest were all statistically significant for detecting severe coronary lesions, with GLS showing superiority.

DISCUSSION:

Echocardiography is absolutely essential in assessing the cardiovascular function and mechanics [8]. Recently, a major breakthrough has been made with the implementation of two-dimensional speckle tracking echocardiography (2D-STE) [8]. Compared to visual wall motion analysis alone, the assessment of 2D global strain (GLS) via speckle-tracking echocardiography during rest can effectively increase detection of severe coronary artery disease (CAD), When looking for severe CAD, it is most effective to combine both GLS and SLR strain.

Our findings indicate that those with triple vessel CAD and left main CAD had lower GLS and SLR strain than those with less severe CAD. If GLS measures below -16.3, it may indicate the presence of severe CAD despite its abnormality. Detecting severe CAD is demonstrated by this outstanding threshold providing specificity above 90% and sensitivity around 60%. In conjunction with other studies, our findings validate GLS imaging's potential in gauging CAD severity [3, 6]. In the meta-analysis conducted by Norum and their team, as well as Keven Lior and their team, the potential of 2D strain was confirmed. They examined 1385 patients in 10 separate studies and found that resting strain serves as an early indication of myocardial ischemia and can predict moderate to severe coronary lesions in symptomatic individuals. Our cutoff for GLS at rest (-16.3%) aligns with the figures documented in this meta-analysis.

By adhering to the guidelines set forth by the American and European cardiology societies, 17 artery segments were carefully analyzed to determine their respective territories and calculate the regional strain (SLR). The effectiveness of this method has been repeatedly proven in

various studies, which also endorse implementing SLR measurement to pinpoint the infarct-related artery (IRA) through an examination of SLR throughout all epicardial artery territories and identifying any deviations.

CONCLUSION:

GLS and RLS are sensitive markers for early prediction of myocardial ischemia and its severity. A GLS threshold of less than **-16.13%** at rest, despite its subnormal nature, should be alerting and raise suspicion of coronary artery disease with severe three vessels or LMT lesions, especially if there are concomitant abnormalities in the WMSI score. This alteration in global longitudinal 2D strain precedes the subjective abnormalities in segmental wall motion, which were often considered normal at rest.

ETHICS

An informed written consent was obtained from each patient according to the declaration of Helsinki and the rules of the Local Ethics Committee of Faculty of Medicine, Hassan II University, Morocco.

References:

- 1 . elhendy a, van domburg rT, Bax JJ, roelandt Jr. significance of resting wall motion abnormalities in 2-dimensional echocardiography in patients without previous myocardial infarction referred for pharmacologic stress testing. J am soc echocardiogr off Publ am soc echocardiogr. 2000;13(1):1-8.
2. ang rM, Badano lP, Mor-avi V, afilalo J, armstrong a, ernande l, et al. recommendations for cardiac chamber quantification by echocardiography in adults: an update from the american society of echocardiography and the european association of Cardiovascular imaging. eur Heart J Cardiovasc imaging. 2015;16(3):233-70.

- 3 . Tsai WC, Liu YW, Huang YY, Lin CC, Lee CH, Tsai LM. Diagnostic value of segmental longitudinal strain by automated function imaging in coronary artery disease without left ventricular dysfunction. *J Am Soc Echocardiogr* 2010;23:1183-9.
- 4 . liou K, negishi K, Ho s, russell ea, Cranney g, ooi s-Y. detection of obstructive Coronary artery disease using Peak systolic global longitudinal strain derived by Two-dimensional speckle-Tracking: a systematic review and Meta-analysis. *J am soc echocardiogr off Publ am soc echocardiogr.* article in press.
5. norum iB, ruddox V, edvardsen T, otterstad Je. diagnostic accuracy of left ventricular longitudinal function by speckle tracking echocardiography to predict significant coronary artery stenosis. a systematic review. *BMC Med imaging.* 2015;15:25.
- 6 . Hubbard, R.T., Arciniegas Calle, M.C., Barros-Gomes, S. et al. 2-Dimensional Speckle Tracking Echocardiography predicts severe coronary artery disease in women with normal left ventricular function: a case-control study. *BMC Cardiovasc Disord* 17, 231 (2017). <https://doi.org/10.1186/s12872-017-0656-5>
- 7 . Bakhoun S, Taha HS, Abdelmonem YY, Fahim M. Value of resting myocardial deformation assessment by two dimensional speckle tracking echocardiography to predict the presence, extent and localization of coronary artery affection in patients with suspected stable coronary artery disease. *Egypt Heart J.* 2016;3(68):171–9
8. Automated tissue Doppler imaging for identification of occluded coronary artery in patients with suspected non-ST-elevation myocardial infarction Marlene Iversen Halvorsrød 1 2, Gabriel Kiss 1 3, Thomas Dahlslett 4, Asbjørn Støylen 1 2, Bjørnar Grenne 56 . *Int J Cardiovasc Imaging.* 2023 Apr;39(4):757-766. doi: 10.1007/s10554-022-02786-7. Epub 2023 Jan 30.
- 9 . Favot M, Courage C, Ehrman R, Khait L, Levy P. Strain echocardiography in acute cardiovascular diseases. *West J Emerg Med.* 2016;17(1):54–60.
10. Khosa, Z., Mehboob, M., Zubair, M., & Sana, H. (2019). Knowledge Assessment of Type 2 Diabetes Mellitus in First Professional Medical Students. *Asian Journal of Medicine and Health*, 16(2), 1–6. <https://doi.org/10.9734/ajmah/2019/v16i230141>
11. Fiagbe, J. W. K., Takramah, W., Axame, W. K., Owusu, R., Parbey, P. A., Adjuik, M., Takase, M., Tarkang, E., & Kweku, M. (2017). Risk Factors Associated with Diabetes Mellitus among Adults in the Hohoe Municipality of Ghana. *Journal of Advances in Medicine and Medical Research*, 23(2), 1–12. <https://doi.org/10.9734/JAMMR/2017/33846>

12. Springer SC, Silverstein J, Copeland K, Moore KR, Prazar GE, Raymer T, Shiffman RN, Thaker VV, Anderson M, Spann SJ, Flinn SK. Management of type 2 diabetes mellitus in children and adolescents. *Pediatrics*. 2013 Feb 1;131(2):e648-64.

UNDER PEER REVIEW

Figures N°1: The study conception and design

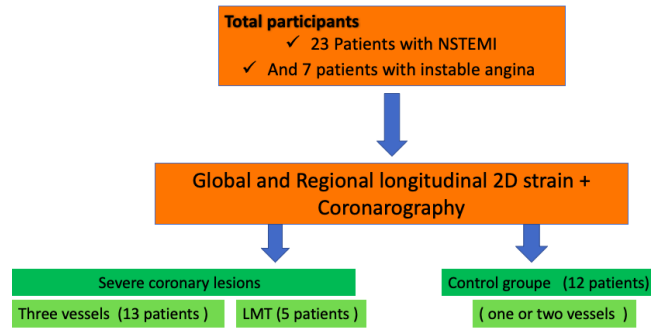


Table 1: Overview of General Characteristics of the Study Population

	Severe CAD		Groupe contrôle	
	Three vessel	LM	Two vessel	One vessel
Participants (n/N)	13/30	5/30	4/30	8/30
NSTEMI	10	5	3	5
Instable angina	3	0	1	3
Sexratio (M/F)	8/5	5/0	1/3	5/3
Average Age (year)	61.3	63.2	62	60
Diabete	6	2	0	2
Hypertension	8	4	3	6
Tabac	2	3	1	2
Dyslipidemie	2	3	1	2
History of stable angina	2	1	2	2

Table 2 : Resultats of Global longitudinal strain and angiographic resultats

	Severe CAD		Groupe contrôle	
	Three vessels	LM	Two vessels	One vessel
Participants (n/N)	13/30	5/30	4/30	8/30
NSTEMI	10	5	3	5
Instable angina	3	0	1	3
GLS** AVERAGE (%)	-15.9	-16.63 %	-22	-24.3
WMSI£ global n/N	6/17	7.7/17	4/17	2/17
RLS* LAD§ (%)	-14.6	-14.1	-27.5	-25
WMSI LAD n/N	2.6/7	3.2/7	1.5/7	0.4/7
RLS CX§ (%)	-14.8	-15.32	-20	-28.5
WMSI CX (n/N)	2.3/5	2.4/5	0.75/5	0.2
RLS RCA § (%)	-18.7	-22	-21	-27
WMSI RCA (n/N)	1/5	1/5	2.5/5	1.2/5

** : global longitudinal strain , * : regional longitudinal strain

§ : left anterior descending coronary artery, § : Right coronary artery

§ : Circonflex artery

£ : Wall Motion Score Index

