

Diagnostic Challenge and Management of a Giant Appendiceal Mucocele: Report of a case

Abstract:

The appendiceal mucocele, a relatively rare condition, presents a diagnostic conundrum as it may masquerade as acute appendicitis or manifest with perplexing symptoms. Recognizing its atypical presentation and establishing an accurate diagnosis are paramount in guiding effective management strategies. Utilizing advanced imaging techniques such as ultrasonography and computed tomography facilitates the detection of mucoceles, aiding in timely intervention. Early preoperative identification is imperative to mitigate potential intraoperative and postoperative complications, underscoring the significance of a comprehensive diagnostic approach. In this case report, we delve into the clinical scenario of a 39-year-old female experiencing right iliac fossa pain, highlighting the challenges encountered in diagnosing and managing appendiceal mucocele.

Keywords: appendix, mucocele, Mucinous neoplasms, abdominal pain, retention cyst, right sided abdominal pain, pseudomyxoma peritonei, appendiceal pathology, colorectal surgery, abdominal mass

Introduction:

Appendectomy is a common surgical procedure performed on a daily basis, globally, to manage the common clinical pathology of the appendix. Mucocele of the appendix is a rare appendiceal pathology encountered in 0.2% to 0.7% of all excised appendixes.¹ It is a term that describes the intraluminal accumulation of large amounts of mucus. It is mostly caused by epithelial proliferation, either benign or neoplastic, and less commonly due to inflammation and obstruction by a fecalith.²

Appendiceal mucinous lesions have a female predominance and are usually diagnosed in patients between the ages of 50s and 60s.³ Less than half of the patients present with signs or symptoms, which are generally associated with malignancy.⁴ These presentations may include right lower quadrant abdominal pain, abdominal mass, nausea, vomiting and weight loss. Careful pre-operative testing is necessary to avoid the most dreaded complication of benign or malignant mucocele - pseudomyxoma peritonei; which is difficult to treat surgically or medically and carries a poorer prognosis.

Herewith we present a case of mucocele of the appendix that was diagnosed in a patient with atypical presentation of right iliac fossa pain.

Case Report:

We present case of a 39-year-old Bahraini lady with a known case of ulcerative pancolitis for 15 years that controlled on mesalamine and azathioprine following regularly with gastroenterology. Prior to being referred to our colorectal service, the patient was

initially followed by gynecology for ectopic pregnancy for which a left salpingectomy was done in April 2021. Histopathology showed fallopian tube with chorionic villi in the lumen and no evidence of gestational trophoblastic disease noted. In July 2021, the patient presented to the emergency department with abdominal pain and right iliac fossa tenderness for which a pelvic ultrasonography was requested and showed a tubular-like structure at the right adnexa containing turbid echogenic material with no definite vascularity (Figure 1). The patient was managed conservatively and was followed up in the gynecology clinic.

Upon regular follow up with gastroenterology and part of the primary disease management, a colonoscopy was done in January 2022 which showed a cecal lesion versus appendiceal submucosal lesion, and random biopsies showed normal colon mucosa. A computerized Tomography (CT) of the abdomen and pelvis with oral and intravenous (IV) contrast was carried out and showed an elongated blind-ended cystic structure in the right iliac fossa, merging with the right side of the colon (cecum) and related terminal ileal loops, as well as the right adnexa; associated with mural wall thickening, suggesting appendiceal mucocele versus Meckel's diverticulum. There were no signs of acute inflammation, perforation, or intestinal obstruction (Figure 2, Figure 3). The patient was then referred to our colorectal services for assessment and clinical examination which revealed a palpable right iliac fossa fullness, the decision was taken to perform a diagnostic laparoscopy.

A laparoscopic converted to open right hemicolectomy with primary anastomosis was done. Intraoperatively a large mass at the appendix consistent with mucocele without perforation was discovered in the right iliac fossa (Figure 4). The peritoneal cavity was inspected thoroughly, and no signs of peritoneal dissemination were found. Given the size of the mucocele and to avoid potential complications, an extended right hemicolectomy with ileotransverse anastomosis was performed. Gross examination revealed a markedly distended appendix measuring 150 mm (length) x 65 mm (diameter), with a lumen filled with mucoid material, and a maximum wall thickness of 2mm. Microscopic examination showed sections of the appendix with partly ulcerated or denuded mucosa. The ulcerated surface shows a foreign-body giant cell reaction with calcification. The residual mucosa is thinned out and composed of benign columnar epithelium with minimal or absent underlying lymphoid stroma; consistent with a simple mucocele. There was no lymph node involvement. The patient tolerated procedure well and was shifted to the ward post operatively. The postoperative course was uneventful, and the patient was discharged on day 6 in good and stable condition. The patient was advised to follow up in the clinic one week after discharge. At the appointment the patient was in good condition.

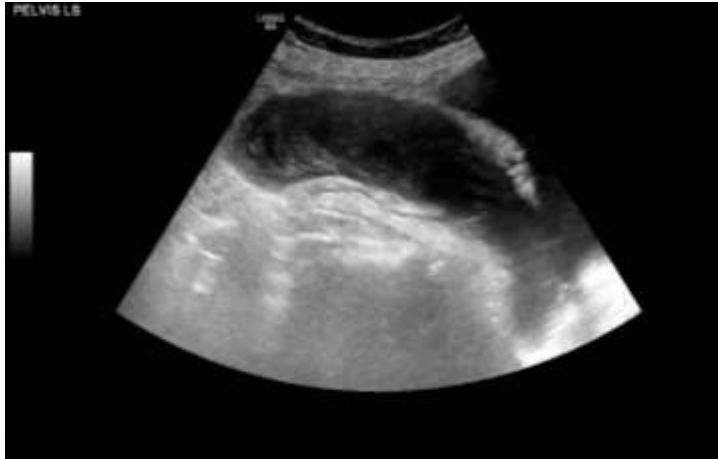


Figure 1. US of pelvis showing a tubular-like structure

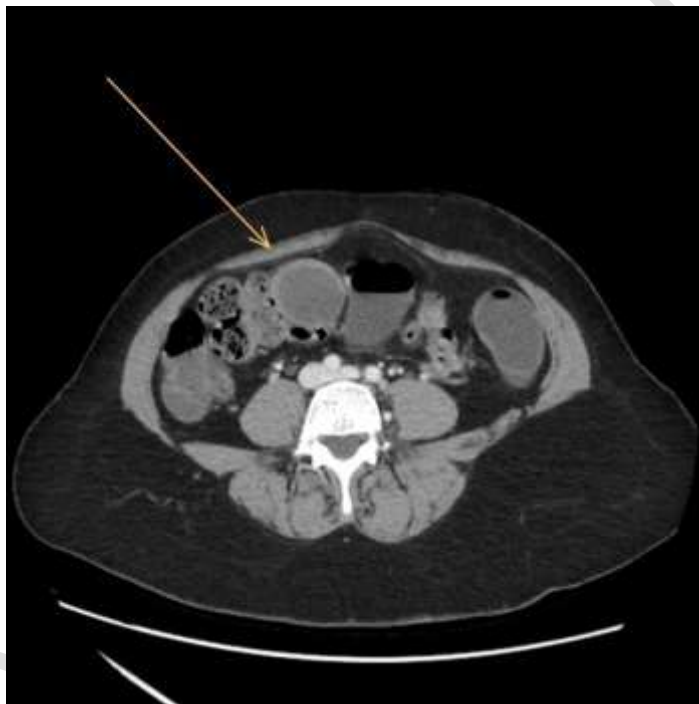


Figure 2. Axial view of CT abdomen with arrow pointing to the appendix

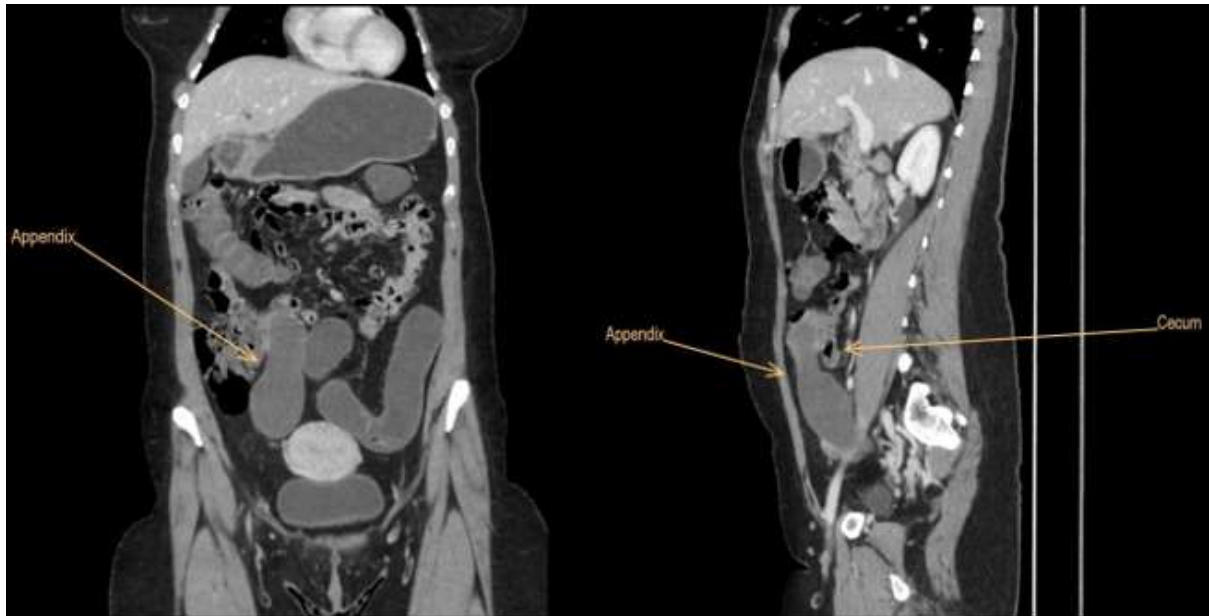

Figure 3. CT images of the mucocele appendix in relation to the cecum

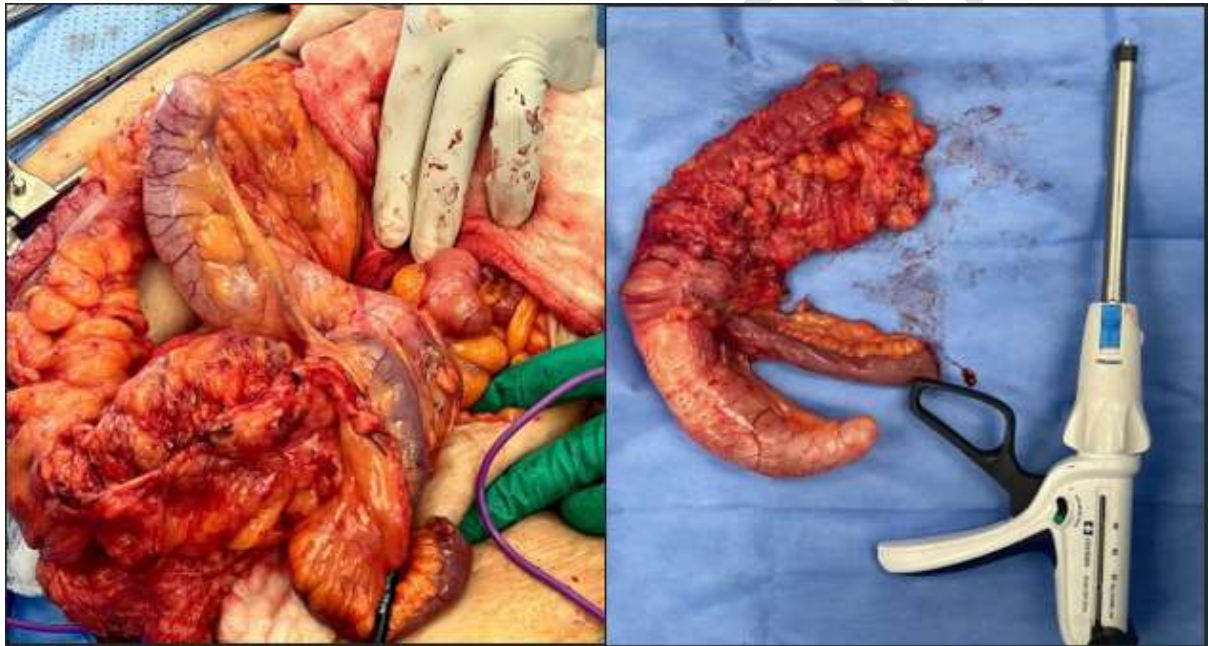

Figure 4. Intraoperative photographs of the appendiceal mucocele

Discussion:

The mucocele of the appendix is a rare clinical pathology that was first described in 1842 by Rokitansky.⁵ According to the Peritoneal Surface Oncology Group International (PSOGI), it is categorized into non-neoplastic, which consists of simple mucocele (also referred to as “retention cyst”) or neoplastic appendiceal mucinous lesions which is further subdivided into (a) Serrated polyps (with or without dysplasia), (b) Mucinous neoplasms (dysplastic mucinous tumors), and (c) Mucinous adenocarcinoma.⁶

Mucocele of the appendix can be discovered incidentally in radiological or endoscopic evaluations. Most patients are asymptomatic, however, could present with signs and symptoms similar to acute appendicitis including, acute or chronic abdominal pain in the right iliac fossa, or occasionally a palpable mass on physical examination.⁷ In our case the patient presented initially with right iliac fossa pain and an initial ultrasound pelvis that was misleading. Ultrasonographic pictures could not differentiate the appendicular mucocele given its large size in our case and was mistaken for a right adnexal mass.

Pre-operative diagnosis of a mucocele is important to establish an appropriate management plan to avoid peritoneal dissemination caused by spontaneous or iatrogenic perforation of the appendix, known as pseudomyxoma peritonei. As with any patient presenting with acute abdominal pain or a mass, Ultrasound is the first-line diagnostic modality used. Ultrasound may show an ovoid cystic mass with variable echogenicity depending on the consistency of the mucocele. The “onion skin” sign consists of multiple echogenic layers along a dilated appendix and is specific for the diagnosis of an appendiceal mucocele.⁷ Computed tomography (CT) is a more accurate method for diagnosis as it typically shows a low-attenuated, well-encapsulated, elongated mass adjacent to the cecum as seen in Figure 2 and 3. During a colonoscopy, a “volcano sign” would be seen, where the appendiceal orifice would move in and out with respiration.⁸ Inflammatory exudate may also be seen extruding from the appendiceal orifice.

It is important to discuss the relationship between Ulcerative Colitis and Mucocele of the Appendix as our patient is a known case of Ucerative Colitis. Ulcerative colitis (UC) is a chronic inflammatory bowel disease characterized by inflammation and ulceration of the colon and rectum. While the association between UC and appendiceal mucocele (AM) remains relatively understudied, emerging evidence suggests a potential link between these two entities. Chronic inflammation in UC may predispose individuals to develop appendiceal pathology, including mucocèles, through mechanisms that are not yet fully elucidated. Furthermore, the chronic inflammatory milieu in UC could contribute to alterations in the appendiceal microenvironment, promoting mucinous epithelial proliferation and ultimately leading to the development of mucocèles. Given the shared inflammatory pathways, clinicians should maintain a heightened suspicion for appendiceal pathology in patients with UC presenting with atypical abdominal symptoms, ensuring timely diagnosis and appropriate management.⁹

Although tumor markers are not routinely tested for because they are non-specific, CEA, CA 19-9 and CA-125 may be elevated in patients with neoplastic mucinous lesions, thus should be measured upon the diagnosis of appendiceal mucinous lesions and repeated routinely to monitor disease progression.⁷

For the management of appendiceal mucocele, surgical resection is recommended. Because there is no statistical difference in size between benign and malignant lesions¹⁰, and no reliable criteria to exclude malignant lesions, surgical resection is necessary to avoid potential rupture. In our case, we started with a laparoscopic approach, however, given the size of the mucocele, converted to open surgery. It allowed us to ensure the intact removal of the lesion and the ability to fully inspect the abdominal cavity for any potential malignant seeding from other mucinous tumors.

Dhage-Ivatury and Sugarbaker suggested a new algorithm for the management of appendiceal mucinous lesions. The surgical option depends on several factors: whether a

mucocele is perforated or not, whether the base of the base of the appendix (the margins) is involved or not, and there are positive lymph nodes of mesoappendix and ileocolic. The surgical options range from appendectomy to right hemicolectomy, including cytoreductive surgery, heated intraoperative intraperitoneal chemotherapy, early postoperative intraperitoneal chemotherapy. In view of the size, the surgical option For our patient was right hemicolectomy.^{11,12}

The most dreaded complication of a rupture of an appendiceal mucocele is the rare peritoneal malignancy, pseudomyxoma peritonei. is difficult to treat as recurrence is common and requires intraperitoneal chemotherapy along with cytoreductive surgery and a long term follow up. Survival rates strongly depend on the pathologic subtype and a 5-year survival probability is approximately 59.5%.¹³

Conclusion:

Appendiceal mucocele is a rare appendix pathology and has a vague clinical picture that could resemble other pathologies. Pre-operative radiological investigations using ultrasound and CT are necessary to carefully plan the surgical resection of the lesion. It is important to prevent the rupture of the mucocele to avoid the most dreadful complication, pseudomyxoma peritonei.

References:

1. Martinez, J. B., & Hayes-Jordan, A. (2021). Pseudomyxoma peritonei: Updates and surgical options. **Journal of Surgical Oncology**, 123(6), 1245–1251. <https://www.ncbi.nlm.nih.gov/pmc/articles/PMC7928084/>
2. Gonzalez-Moreno, S., & Sugarbaker, P. H. (2003). Clinical manifestation and natural history of pseudomyxoma peritonei. **Annals of Surgery**, 237(3), 409–415. <https://www.ncbi.nlm.nih.gov/pmc/articles/PMC3862129/>
3. Landen, S., Bertrand, C., Maddern, G. J., Herman, D., Pourbaix, A., de Neve, A., & Schmitz, A. (1992). Appendiceal mucoceles and pseudomyxoma peritonei. **Surgery, Gynecology & Obstetrics**, 175(5), 401–404. <https://pubmed.ncbi.nlm.nih.gov/1440166/>
4. Fenoglio-Preiser, C. M., Wang, J., & Stemmermann, G. N. (2003). Pathologic and clinical correlates of mucinous tumors of the appendix. **Cancer**, 98(11), 2485–2494. <https://pubmed.ncbi.nlm.nih.gov/12799327/>
5. Rokitansky, C. F. (1855). **A manual of pathological anatomy** (Vol. 2). Philadelphia: Blacard and Lea.
6. Carr, N. J., Cecil, T. D., Mohamed, F., Sobin, L. H., Sugarbaker, P. H., & González-Moreno, S. (2016). A consensus for classification and pathologic reporting of pseudomyxoma peritonei. **The American Journal of Surgical Pathology**, 40(1), 14–26. https://journals.lww.com/ajsp/Abstract/2016/01000/A_Consensus_for_Classification_and_Pathologic.4.aspx
7. Shaib, W. L., & Munkarah, A. (2024). Appendiceal mucinous lesions. In **UpToDate**. Retrieved May 30, 2024, from https://www.uptodate.com/contents/appendiceal-mucinous-lesions?search=simple%20appendiceal%20mucocele&source=search_result&selectedTitle=1~22&usage_type=default&display_rank=1#H553428626

8. Pai, R. K., & Longacre, T. A. (2005). Appendiceal mucinous neoplasms and pseudomyxoma peritonei. **Gastrointestinal Endoscopy**, 62(6), 972–984. [https://www.giejournal.org/article/S0016-5107\(05\)01881-X/fulltext](https://www.giejournal.org/article/S0016-5107(05)01881-X/fulltext)

9. Friedman, J., Finkelstein, S., & Goldenberg, S. (2024). Association Between Ulcerative Colitis and Appendiceal Mucocele: A Review of the Literature. **Journal of Gastrointestinal Surgery**, 1-10.

10. Ronnett, B. M., & Kurman, R. J. (2006). Pseudomyxoma peritonei: A clinicopathologic analysis. **JAMA Surgery**, 141(11), 1108–1116. <https://jamanetwork.com/journals/jamasurgery/fullarticle/394931>

11. Rampone, B., Roviello, F., Marrelli, D., & Pinto, E. (2005). Giant appendiceal mucocele: Report of a case and brief review. **World Journal of Gastroenterology**, 11(30), 4761–4763.

12. Dhage-Ivatury, S., & Sugarbaker, P. H. (2006). Update on the surgical approach to mucocele of the appendix. **Journal of the American College of Surgeons**, 202(4), 680–684.

13. Misdraji, J., & Young, R. H. (2004). Primary epithelial neoplasms and other epithelial lesions of the appendix (excluding carcinoid tumors). **Seminars in Diagnostic Pathology**, 21(2), 120–133. <https://www.ncbi.nlm.nih.gov/pmc/articles/PMC1867935/>

Ogbetere FE. Inflamed Right Inguinal Appendix in a Sixty-four-year-old Man: A Case Report and Review of the Literature. *J. Adv. Med. Med. Res.* [Internet]. 2021 Aug. 31 [cited 2024 May 23];33(18):176-80. Available from: <https://journaljammr.com/index.php/JAMMR/article/view/4166>

Jatal SN, Jatal S, Ingle S. Appendicitis Causing Small Bowel Strangulation a Rare Presentation– Three Case Reports. *Asian J. Res. Surg.* [Internet]. 2023 Jul. 6 [cited 2024 May 23];6(2):101-7. Available from: <https://journalajrs.com/index.php/AJRS/article/view/139>

Nussbaum DP, Speicher PJ, Gulack BC, Keenan JE, Ganapathi AM, Englum BR, Tyler DS, Blazer III DG. Management of 1-to 2-cm carcinoid tumors of the appendix: using the national cancer data base to address controversies in general surgery. *Journal of the American College of Surgeons.* 2015 May 1;220(5):894-903.