

Unexpected twists: The rare occurrence of volvulus in Meckel's diverticulum

ABSTRACT.

Aims: To present an unusual case and our therapeutic approach to a clinical case of volvulus caused by a Meckel's Diverticulum.

Presentation of Case: A 32-year-old male patient came to the emergency department with abdominal pain with constipation and abdominal distension for the last 3 days. An abdominopelvic computed tomography scan was suggestive of a perforated hollow viscus. An exploratory laparotomy was proposed. Intraoperatively, a small bowel volvulus secondary to Meckel's diverticulum was found, without pneumoperitoneum. The viability of the loops was confirmed and diverticulectomy was performed.

Conclusion: The hypothesis of Meckel's Diverticulum should always be considered in cases of small bowel obstruction.

Keywords: Volvulus, Meckel's Diverticulum, Small bowel obstruction

1. INTRODUCTION

Meckel's diverticulum (MD) is a true diverticulum of the small intestine. It consists of a partial remnant of the omphalomesenteric duct (communication of the primitive intestine with the yolk sac) resulting from non-obliteration during embryonic development. It usually appears on the antimesenteric border, at a variable distance from the ileocecal valve, which can be up to 1 meter^{1,2,12,13,14}.

MD is the most common congenital malformation of the gastrointestinal tract and is present in around 2% of the population, with a male-to-female ratio of 2:1^{2,3}.

The risk of complications is around 4% throughout life and decreases with age, with around 30% occurring in the first year of life and 40% until 10 years old. Complications include occlusion (more frequent in adults), inflammation, perforation, lower gastrointestinal bleeding, and neoplasms^{1,2,4}.

The aim is to present an unusual clinical case and the therapeutic approach chosen.

2. PRESENTATION OF CASE:

A 32-year-old male patient came to the emergency department with diffuse, constant pain, of increasing intensity, for 6 days, without irradiation, worsening, or relieving factors. It had been associated with constipation and abdominal distension for the last 3 days. He denied fever, nausea, vomiting, and alterations in the genitourinary system. Objectively, the abdomen was distended with hydro-aeric sounds with a metallic tone, without signs of peritoneal irritation or identifiable hernias. A nasogastric tube was placed and 3500cc of stasis content drained immediately.

An analytical study revealed leukocytosis ($14.83 \times 10^3/\mu\text{L}$), with neutrophilia (87%), elevated C-reactive protein (CRP) (10.03 mg/dL), and lactate dehydrogenase (305 U/L). He had acute renal failure with creatinine 7.16 mg/dL. Abdominal radiography showed distension of the small bowel and colon with hydro-aeric levels (Figure 1). An abdominopelvic computed tomography

scan (TC) with intravenous contrast was ordered that showed 'marked distension of the stomach and intestinal loops, compatible with a colon'. 'The possibility of pneumoperitoneum was suggested (Figure 2).

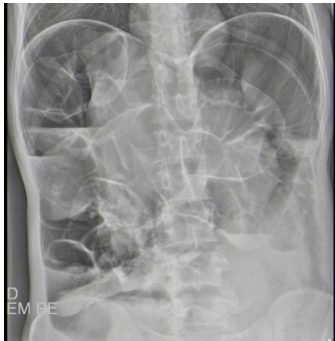

Figure 1: Abdominal X-ray in orthostatism

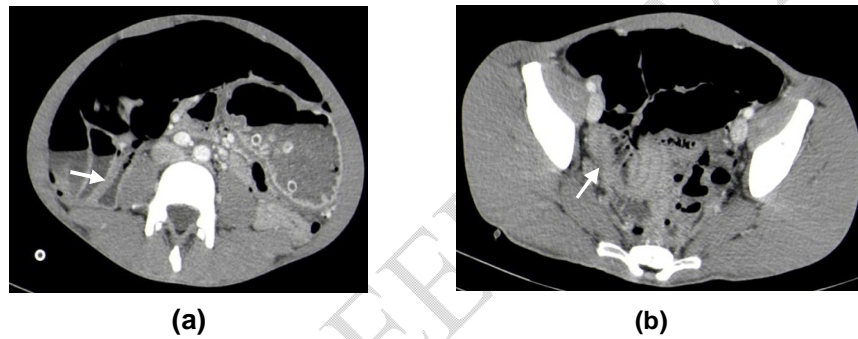


Figure 2: abdominopelvic TC- white arrowsshow aMesocolon torsion(a) and Meckel's diverticulum(b)

Exploratory laparotomy was proposed, to which the patient consented. Intraoperatively, an axial volvulus of the small intestine was found over a lax and long mesentery (Figure 3). After counter-rotating the volvulus, a MD was identified with a wide base of around 5cm and approximately 6cm long (Figure 4). Diverticulectomy was performed.

The surgico-pathologic study revealed: MD with gastric-type epithelium and inflammatory lesions; margins without lesions and no signs of malignancy were observed.

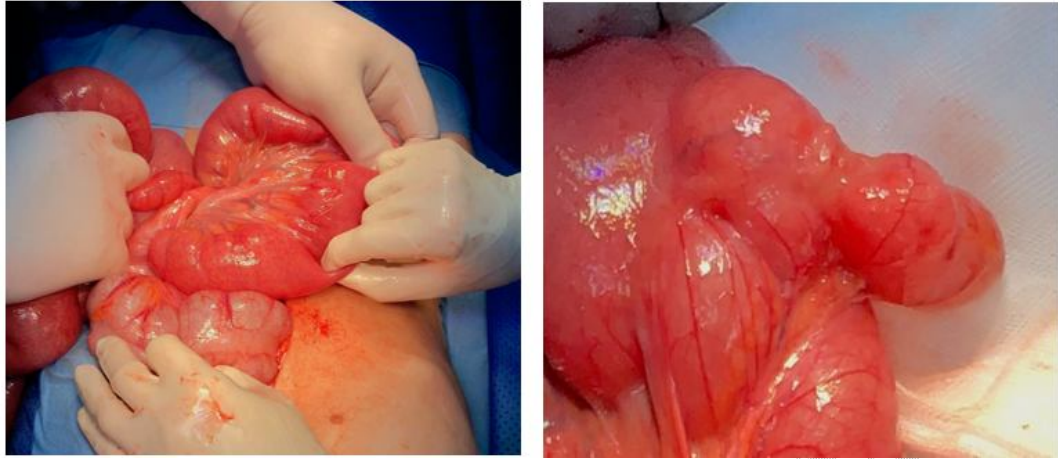


Figure 3: Volvulus Figure 4: Meckel's diverticulum

The patient had a favorable evolution and was discharged on the 11th postoperative day after the resolution of acute kidney injury.

3. DISCUSSION AND CONCLUSION:

Despite the increasing sensitivity and specificity of imaging tests, the preoperative diagnosis of MD is rare and a challenge¹. Most patients with Meckel diverticulum are asymptomatic and discovered incidentally by ultrasound, abdominopelvic CT, or exploratory surgery. The lifetime risk of related complications is estimated at 4%. These include gastrointestinal bleeding, obstruction, or diverticular inflammation^{1,3,4}. The most widespread complication in adults is bowel obstruction. Small bowel volvulus complicates 5.5% of Meckel's diverticulum.

Symptomatic diverticulum requires surgical resection. Three surgical techniques have been described: segmental enterectomy, wedge resection, and diverticulectomy. Recently, wider resection has been advocated, the segmental enterectomy, because it allows evaluation of the mucosa at the base of the diverticulum, avoiding non or incomplete resection of ectopic mucosa with a malignancy potential, which occurs in 0.5 to 3%^{2,6}.

Ectopic mucosa is present in around 20% of MDs (62% gastric, 6% pancreatic, 5% gastric and pancreatic, 2% jejunal, 2% gastric and duodenal mucosa, and 2% Brunner tissue. Rarely, histology can reveal colonic, rectal, endometrial, and hepatobiliary patterns⁷. In the case presented, diverticulectomy was performed and the histology revealed gastric epithelium. The main complication of gastric ectopic mucosa is ulceration, which can lead to bleeding and/or perforation. Since the margins were free of lesions and no signs of malignancy, reintervention with segmental enterectomy wasn't proposed.

In conclusion, Meckel's diverticulum should always be considered a cause of small bowel obstruction.

In complicated cases, the surgical procedure should be adapted to the patient, with a recent preference for segmental enterectomy.

Ethical Approval:

As per international standards or university standards written ethical approval has been collected and preserved by the author(s).

Consent

As per international standards or university standards, patient(s) written consent has been collected and preserved by the author(s).

Disclaimer (Artificial intelligence)

Option 1:

Author(s) hereby declare that NO generative AI technologies such as Large Language Models (ChatGPT, COPILOT, etc) and text-to-image generators have been used during writing or editing of manuscripts.

Option 2:

Author(s) hereby declare that generative AI technologies such as Large Language Models, etc have been used during writing or editing of manuscripts. This explanation will include the name, version, model, and source of the generative AI technology and as well as all input prompts provided to the generative AI technology

Details of the AI usage are given below:

- 1.
- 2.
- 3.

REFERENCES

1. Lequet, J., Menahem, B., Alves, A., Fohlen, A., & Mulliri, A. (2017). Meckel's diverticulum in the adult. *Journal of visceral surgery*, 154(4), 253–259. <https://doi.org/10.1016/j.jviscsurg.2017.06.006>
2. Grapin, C., Bonnard, A., & Helardot, P. G. (2006). Laparoscopic surgery of Meckel's diverticulum. *Annals of Surgery*, 131(3), 222–223. <https://doi.org/10.1016/j.anchir.2006.01.014>
3. Javid, P., & Pauli, E. (2024). Meckel's diverticulum. UpToDate. Retrieved June 6, 2024., from www.uptodate.com/contents/meckels-diverticulum.

4. Kuru, S., & Kismet, K. (2018). Meckel's diverticulum: clinical features, diagnosis and management. *Spanish journal of digestive diseases*, 110(11), 726–732.
<https://doi.org/10.17235/reed.2018.5628/2018>
5. Musteata, L., Geraldo, R. F., Ndasu Matendo, H., Reitz, A., Krasovski, V., Nitu, V., Gastaud, T., & Cattan, F. (2020). Meckel Diverticulum Causing Intestinal Volvulus. *Case reports in surgery*, 2020, 8872668. <https://doi.org/10.1155/2020/8872668>
6. López, F., Fernández-Salazar, L., Velayos, B., Aller, R., Juárez, M., & González, J. (2007). Meckel's diverticulum and gastrointestinal stromal tumor: an unusual association. *Gastroenterology and Hepatology*, 30(9), 534-537. <https://doi.org/10.1157/13111691>.
7. Rabinowitz, S., & Haribhai, M. (2020). Pediatric Meckel Diverticulum. Medscape. Retrieved June 6, 2024., from <https://emedicine.medscape.com/article/931229-overview>.
8. An, J., & Zabbo, C. P. (2023). Meckel Diverticulum. In StatPearls. Publicação StatPearls.
9. Anis, H., Racem, T., Sihem, H., & Salma, K. (2023). A gigantic Meckel's diverticulum: A case report of an exceptional cause of small bowel obstruction. *International journal of surgery case reports*, 110, 108788. <https://doi.org/10.1016/j.ijscr.2023.108788>
10. Paranjape, C., & Velmahos, G., (2022). Current Surgical Therapy: Small Bowel (14th Edition). Philadelphia, PA: Elsevier
11. Evan, C., Christy, K., Hanafi, R. V., & Rodjak, M. W. (2024). Acute intestinal obstruction due to meckel's diverticulum: A case report and literature review. *Heliyon*, 10(9), e30514. <https://doi.org/10.1016/j.heliyon.2024.e30514>
12. Janež, Jurij. 2024. “Large Inflammatory Tumor Due to Perforated Meckel's Diverticulum Managed With Extensive Ileocolic Resection”. *International Journal of Medical and Pharmaceutical Case Reports* 17 (1):1-4. <https://doi.org/10.9734/ijmpcr/2024/v17i1360>.
13. Jatal, Sopan N., Sudhir Jatal, and Sachin Ingle. 2023. “An Extremely Rare Case of Small Bowel Strangulation Due to Meckel's Diverticulum”. *Asian Journal of Research in Surgery* 6 (2):97-100. <https://journalajrs.com/index.php/AJRS/article/view/138>.
14. St-Vil D, Brandt ML, Panic S, Bensoussan A, Blanchard H. Meckel's diverticulum in children: a 20-year review. *Journal of pediatric surgery*. 1991 Nov 1;26(11):1289-92.