

# Case report Volvulus – a rare complication of Meckel's Diverticulum

Comment [LL1]: Diverticulum

Comment [LL2]:

Comment [LL3]: Another suggested title can be . . . Unexpected twists: The rare occurrence of volvulus in Meckel's diverticulum. A case report

## ABSTRACT.

**Aims:** To present an unusual case and our therapeutic approach to a clinical case of volvulus caused by a Meckel's Diverticulum.

**Presentation of Case:** A 32-year-old male patient came to the emergency department with abdominal pain with constipation and abdominal distension for the last 3 days. An abdominopelvic computed tomography scan was suggestive of a perforated hollow viscus. An exploratory laparotomy was proposed. Intraoperatively, a small bowel volvulus secondary to Meckel's diverticulum was found, without pneumoperitoneum. The viability of the loops was confirmed and diverticulectomy was performed.

**Discussion and Conclusion:** Meckel's Diverticulum is present in around 2% of the population. The risk of complications is around 4% throughout life. The most widespread complication in adults is bowel obstruction. In this particular case, it is complicated with volvulus. Small bowel volvulus complicates 5.5% of Meckel's diverticulum. In these cases, three surgical techniques have been described: segmental enterectomy, wedge resection, and diverticulectomy. Recently, wider resection has been advocated, the segmental enterectomy, because it allows evaluate the mucosa at the base of the diverticulum, avoiding non or incomplete resection of ectopic mucosa with a malignancy potential which occurs in 0.5 to 3%.

Comment [LL4]: Discussion is part of case report. In abstract you need to write only aims, case report and conclusion in your own words without any references.

*Keywords: Volvulus, Meckel's Diverticulum, Small bowel obstruction*

## 1. INTRODUCTION

Meckel's diverticulum (MD) is a true diverticulum of the small intestine. It consists of a partial remnant of the omphalomesenteric duct (communication of the primitive intestine with the yolk sac) resulting from non-obliteration during embryonic development. It usually appears on the antimesenteric border, at a variable distance from the ileocecal valve, which can be up to 1 meter<sup>1,2</sup>.

MD is the most common congenital malformation of the gastrointestinal tract and is present in around 2% of the population, with a male-to-female ratio of 2:1<sup>2,3</sup>.

The risk of complications is around 4% throughout life and decreases with age, with around 30% occurring in the first year of life and 40% until 10 years old. Complications include occlusion (more frequent in adults), inflammation, perforation, digestive bleeding, and neoplasms<sup>1,2,4</sup>.

Comment [LL5]: Lower gastrointestinal

The aim is to present an unusual clinical case and the therapeutic approach chosen.

## 2. PRESENTATION OF CASE:

A 32-year-old male patient came to the emergency department with diffuse, constant pain, of increasing intensity, for 6 days, without irradiation, worsening, or relieving factors. It had been associated with constipation and abdominal distension for the last 3 days. He denied fever,

nausea, vomiting, and alterations in the genitourinary system. Objectively, the abdomen was distended with hydro-aerial sounds with metallic tone, without signs of peritoneal irritation or identifiable hernias. A nasogastric tube was placed and 3500cc of stasis content drained immediately.

Comment [LL6]: Hydro-aeric

An analytical study revealed leukocytosis ( $14.83 \times 10^3/\mu\text{L}$ ), with neutrophilia (87%), elevated C-reactive protein (CRP) (10.03 mg/dL), and lactate dehydrogenase (305 U/L). He had acute renal failure with creatinine 7.16 mg/dL. Abdominal radiography showed distension of the small bowel and colon with hydroaerial levels (Figure 1). An abdominopelvic computed tomography scan (TC) with intravenous contrast was ordered that showed 'marked distension of the stomach and intestinal loops, compatible with a colon'. 'The possibility of pneumoperitoneum was suggested (Figure 2).

Comment [LL7]: Hydro-aeric

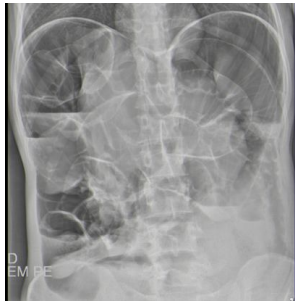

Figure 1: Abdominal X-ray in orthostatism

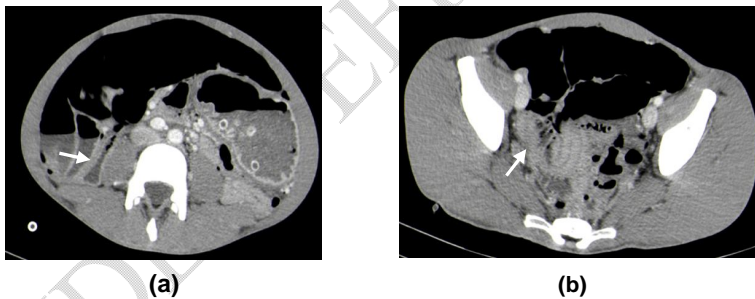

Figure 2: abdominopelvic TC- (a) Mesocolon torsion; (b) Meckel's diverticulum

Comment [LL8]: Please elaborate on where is mesocolon and its torsion

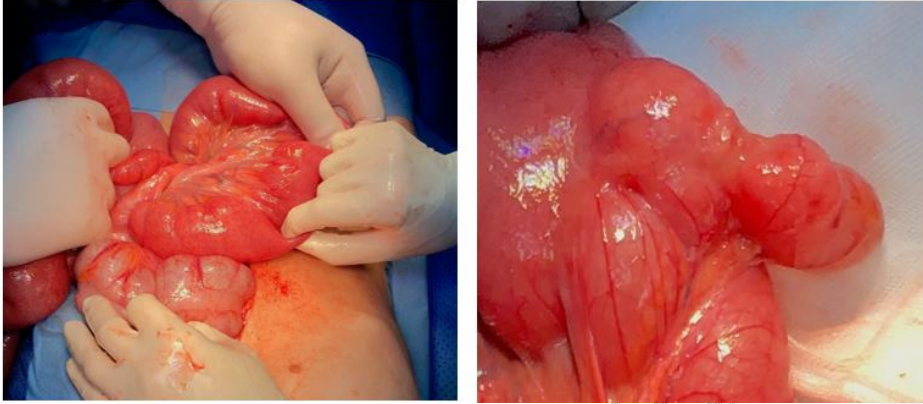
Exploratory laparotomy was proposed, to which the patient consented. Intraoperatively, an axial volvulus of the small intestine was found over a lax and long meso (Figure 3). After counter-rotating the volvulus, a MD was identified with a wide base of around 5cm and approximately 6cm in length (Figure 4). Diverticulectomy was performed.

Comment [LL9]: mesentery

The anatomopathological study revealed: MD with gastric-type epithelium and inflammatory lesions; tops without lesions and no signs of malignancy observed.

Comment [LL10]: surgico-pathologic

Comment [LL11]: margins



**Figure 3:**Volvulus **Figure 4:**Meckel's diverticulum

The patient had a favorable evolution and was discharged on the 11th postoperative day after solving acute kidney injury.

**Comment [LL12]:** resolution of

UNDER PEER REVIEW

### 3. DISCUSSION AND CONCLUSION:

Despite the increasing sensitivity and specificity of imaging tests, the preoperative diagnosis of MD is rare and a challenge<sup>1</sup>. Most of the patients with Meckel diverticulum are asymptomatic and discovered incidentally by ultrasound, abdominopelvic CT, or exploratory surgery. The lifetime risk of related complications is estimated at 4%. These include gastrointestinal bleeding, obstruction, or diverticular inflammation<sup>1,3,4</sup>. The most widespread complication in adults is bowel obstruction. Small bowel volvulus complicates 5.5% of Meckel's diverticulum.

Symptomatic diverticulum requires surgical resection. Three surgical techniques have been described: segmental enterectomy, wedge resection, and diverticulectomy. Recently, wider resection has been advocated, the segmental enterectomy, because it allows evaluate the mucosa at the base of the diverticulum, avoiding non or incomplete resection of ectopic mucosa with a malignancy potential, which occurs in 0.5 to 3%<sup>2,6</sup>.

Ectopic mucosa is present in around 20% of MDs (62% gastric, 6% pancreatic, 5% gastric and pancreatic, 2% jejunal, 2% gastric and duodenal mucosa, and 2% Brunner tissue. Rarely, histology can reveal colonic, rectal, endometrial, and hepatobiliary patterns<sup>7</sup>. In the case presented, diverticulectomy was performed and the histology revealed gastric epithelium. The main complication of gastric ectopic mucosa is ulceration, which can lead to bleeding and/or perforation. Given that the tops were free of lesions and there were no signs of malignancy, reintervention with segmental enterectomy wasn't proposal.

In conclusion, Meckel's diverticulum should always be considered as a cause of small bowel obstruction.

In complicated cases, the surgical procedure should be adapted to the patient in question, with a recent preference for segmental enterectomy.

### REFERENCES

1. Lequet J, Menahem B, Alves A, Fohlen A, Mulliri A. Non-adult Meckel's diverticulum. *J Visc Surg.* 2017;154(4):253-259.
2. Grapin C, Bonnard A, Helardot P-G. Meckel's diverticulum surgery. *EMC-Surgical Techniques-Digestive System.* 2006; 22(1):1-6
3. Javid P, Pauli E, Soybel D, Heyman M. Meckel's diverticulum. In: Chen W, ed. *UpToDate.* Waltham, Mass.: UpToDate, 2020. [www.uptodate.com/contents/meckels-diverticulum](http://www.uptodate.com/contents/meckels-diverticulum). Accessed March, 2023.
4. Kuru S, Kismet K. Meckel's diverticulum: clinical features, diagnosis and management. *Rev Esp Enferm Dig.* 2018 Nov;110(11):726-732.
5. Musteata L, Geraldo RF, Ndasu Matendo H, et al. Meckel Diverticulum Causing Intestinal Volvulus. *Case Rep Surg.* 2020;2020:8872668. Published 2020 Sep 25.
6. de la Morena López F, Fernández-Salazar L, Velayos B, Aller R, Juárez M, González JM. Meckel's diverticulum and gastrointestinal stromal tumor: an unusual association. *Gastroenterol Hepatol.* 2007;30(9):534-537.
7. Rabinowitz S, Haribhai M. Pediatric Meckel Diverticulum. In: Cufarri C, ed. *Medscape.* New Work.: Medscape, 2020. <https://emedicine.medscape.com/article/931229-overview>. Accessed March, 2023.

Comment [LL13]: Discussion  
No need for separate header of conclusion

Comment [LL14]: margins