

## Surgical management of oligometastatic port site recurrence following robotic assisted gynaecological cancer surgery – a case report

### **Abstract:**

#### **Background:** AIMS????

Port site recurrence is a rare complication of laparoscopic or robotic surgery for gynaecological cancer. The exact mechanism is not well understood and there are few cases detailing this phenomenon specifically after robotic assisted surgery for gynaecological cancer.

#### **Methods:** Presentation of Case, Discussion

The authors present a case of oligometastatic port site metastasis in a 49-year-old woman with Stage 1B1 grade 2 endocervical adenocarcinoma following primary robotic radical hysterectomy with lymph node dissection. The recurrence was diagnosed 16 months post primary surgery in the anterior abdominal wall and the lung. Both were resected with clear margins and the patient continued follow up. A further second ipsilateral port site recurrence was diagnosed 81 months after the initial surgery, this was also excised and the abdominal wall reconstructed with mesh. The patient is asymptomatic and disease-free 7.5 years after her initial diagnosis.

#### **Conclusion:**

Oligometastatic port site recurrence can be successfully managed by surgical excision in selected cases, however more research is required to develop better understanding of the mechanisms and risk factors for port site metastasis in different gynaecological cancers which would in turn help to improve clinical decision making.

Key words: Port site metastasis; Gynaecological cancer; Cervical cancer; Minimally invasive surgery; Robotic surgery

### **Introduction:**

Laparoscopic port site metastasis has been described as early as 1978 by Döbrönte et al (1978). At the time, the concept of robotic assisted surgery was still in the distant future yet the rapid advances in imaging technology, microprocessors and optics have paved the way for a new era in robotic surgery which is now widely implemented in the management of gynaecological cancer. The oncological safety of minimal access surgery has been a widely debated topic. One of the concerns with minimal access surgery is port site metastasis to the abdominal wall. The incidence of port-site metastasis after conventional laparoscopy is thought to be low and has been reported as 1–2% (Ramirez 2003, Zivanovic 2008). On the other hand, there are relatively few studies and case reports examining port site metastasis in robotic assisted surgery. The overall incidence of port-site metastasis after robotic assisted surgery is reported to be as low as 0.9% by Barraez et al (2015) in their analysis of endometrial cancer cases. Similarly, Lönnerfors et al (2013) reported robotic port-site metastasis in 1.9% (9 women) of cervical and endometrial cancer patients with high-risk histology

**Comment [AEFH1]:** . Case reports / Case studies (Mainly for bio-medical journals): Case reports describe patient cases which are of particular interest due to their novelty and their potential message for clinical practice. While there are several types of case reports, originality and clinical implications constitute the main virtues by which case reports are judged. (Ref: <http://www.ncbi.nlm.nih.gov/pubmed/18677298>). Case studies are an invaluable record of the clinical practices of a profession. While case studies cannot provide specific guidance for the management of successive patients, they are a record of clinical interactions which help us to frame questions for more rigorously designed clinical studies. Case studies also provide valuable teaching material, demonstrating both classical and unusual presentations which may confront the practitioner. (Ref: <http://www.ncbi.nlm.nih.gov/pmc/articles/PMC2597880/>). **Abstract (not more than 250 words)** of the Case reports should have the following sections: **Aims, Presentation of Case Discussion and Conclusion**. Only Case Reports have word limits: **Papers should not exceed 2000 words, 20 references or 5 figures**

**Comment [AEFH2]:** Reference style References must be listed at the end of the manuscript and numbered in the order that they appear in the text. Every reference referred in the text must also present in the reference list and vice versa. In the text, citations should be indicated by the reference number in brackets [3].

**Comment [AEFH3]:** Reference style References must be listed at the end of the manuscript and numbered in the order that they appear in the text. Every reference referred in the text must also present in the reference list and vice versa. In the text, citations should be indicated by the reference number in brackets [3].

and/or advanced stage thought to be contributing factors. **Nodofor(2011) et al** reported on 2 patients (1.1%) with port-site metastasis following robotic surgery for gynaecological malignancies. In both identified cases, the patients had concurrent metastasis elsewhere. Moreover, a retrospective cohort analysis by **Rindos et al (2014)** detected port site metastasis in 1.4% (2 of 142) patients who underwent robotic-assisted surgery for gynaecological cancer and in both cases the patients also had other areas of metastasis. Indeed, in the majority of reported cases, patients with port site metastasis have other concurrent metastasis while isolated and oligometastatic port site recurrence is rare.

**Comment [AEFH4]:** Reference style  
References must be listed at the end of the manuscript and numbered in the order that they appear in the text. Every reference referred in the text must also present in the reference list and vice versa. In the text, citations should be indicated by the reference number in brackets [3].

#### Case report:

A 49 year old woman presented to the gynaecology oncology clinic in December 2016 with a diagnosis of grade 2 endocervical adenocarcinoma following a **colposcopic** examination and targeted loop biopsy. The symptoms at presentation were postcoital bleeding and abnormal vaginal discharge. There were no medical comorbidities, and no previous surgery other than a caesarean section. On physical examination there was evidence of a 4cm exophytic tumour on the cervix with no vaginal or parametrial invasion. Radiological staging with a contrast CT of the thorax, abdomen and pelvis as well as a Pelvic MRI did not demonstrate any distant metastatic disease or lymphadenopathy. The cancer was pre-operatively staged by the gynaecological oncology **multidisciplinary team (MDT)** as **FIGO(2009)1b2?????** and she was offered surgery at a gynaecology cancer centre (**Pecorelli 2009**). She underwent a total robotic radical hysterectomy, left pelvic sentinel lymph node identification with bilateral pelvic lymphadenectomy. The procedure was performed on the Da Vinci Si Surgical System (Intuitive Surgical, Sunnyvale, California, USA). Indocyanine Green was injected at 3 and 9 o'clock into the cervix for sentinel node identification. A Vectec uterine manipulator was used. Primary Veress needle entry was performed and a 12mm camera port was placed 4cm above umbilicus. Further left lateral 12mm assistant port, left iliac fossa 8mm robotic port and two right 8mm robotic ports were placed under direct vision. The port placement was curvilinear and angled toward the pelvis (**Figure 1**). Lymph node retrieval was undertaken intraoperatively in an endoscopic bag. The uterus was retrieved vaginally. The skin incisions were closed with 2-0 vicryl rapide sutures. The procedure was uncomplicated with estimated blood loss of 175 milliliters. The patient was discharged the following day. The final histopathology report confirmed a grade 2 endocervical adenocarcinoma with no lymphovascular space invasion and a depth of stromal infiltration of 15mm.

**Comment [AEFH5]:** Reference style  
References must be listed at the end of the manuscript and numbered in the order that they appear in the text. Every reference referred in the text must also present in the reference list and vice versa. In the text, citations should be indicated by the reference number in brackets [3].

#### **Figure 1 figure this is where you go**

There was no evidence of extra cervical soft tissue extension. The tumour was completely excised with a margin of 9mm. All lymph nodes were negative for malignancy. The final **FIGO (2009) ????** cancer stage was 1B1 and after review by the MDT, clinical follow up was recommended. Unfortunately, after 16 months of follow up (May 2018), a surveillance CT scan had demonstrated a 17mm left rectus sheath nodule (**figure 2**) and a 7mm left lower lobe pulmonary nodule. A PET CT demonstrated increased uptake in the rectus sheath nodule (SUV 14.8). A diagnostic laparoscopy was performed to exclude intra-abdominal recurrence. She underwent radiolabelled excision of the lung and left rectus sheath nodules. Subsequent histopathological examination had demonstrated a metastatic adenocarcinoma of primary cervical origin in both specimens (CK7, CEA, P16 positive and lack of TTF1 and CK20 expression). Both resection margins were clear of the tumour. The results were discussed in the MDT and the patient continued follow up.

She continued follow up uneventfully until September 2023 (81 months after primary surgery) when she presented with left-sided abdominal pain. A contrast CT scan demonstrated a recurrence in the left rectus sheath with subsequent PET CT demonstrating

Figure 2 figure this is where you go!!!!!!!

INDICATE FIGURE 3 IN THE TEXT.

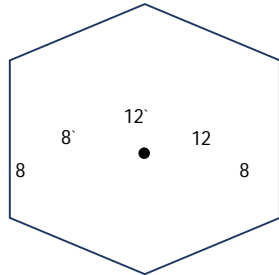



Figure 1: abdominal port placement for primary surgery (port size in mm). [X]

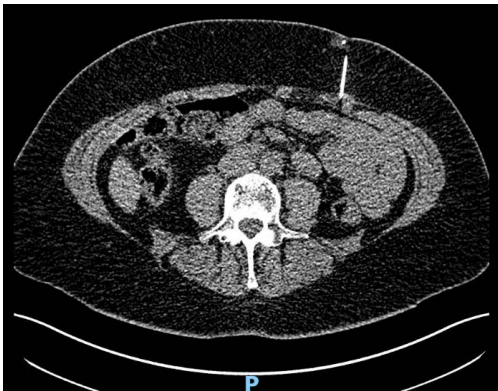

Figure 2: Axial CT marking left rectus sheath nodule [X]



LOTS OF FREE SPACE

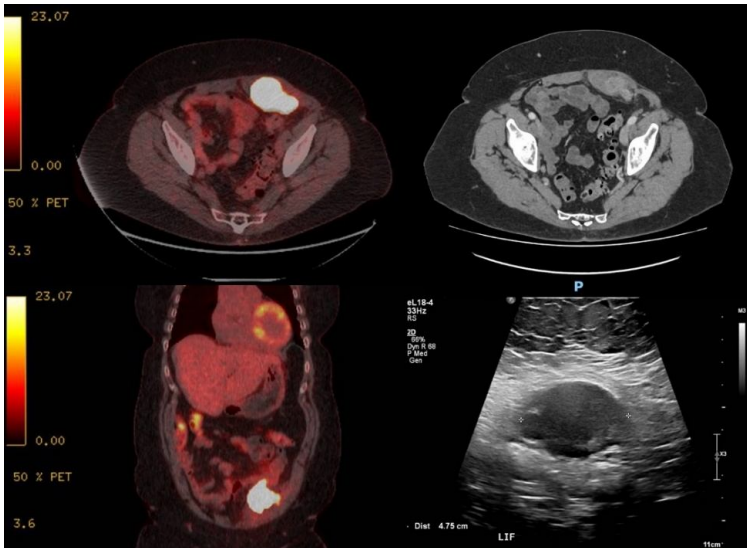



Figure 3: mass in the left rectus sheath (top left = axial PET CT, bottom left = coronal PET CT, top right = axial contrast CT, bottom right = trans-abdominal ultrasound [X]).

LOTS OF FREE SPACE



an FDG avid lesion (SUV 59) in the inferior aspect of the left rectus sheath measuring 7.5 cm. There was no evidence of other metastatic disease.

Following consensus from the MDT, the patient underwent a multi-speciality joint surgical procedure involving plastic surgery, general surgery as well as the gynaecological oncology team. The tumour was excised through an abdominoplasty (flap) approach, with subsequent defect reconstruction with acellular dermal matrix and mesh (figure 4). The tumour did not involve the bowel or other intra-abdominal structures.



LOTS OF FREE SPACE

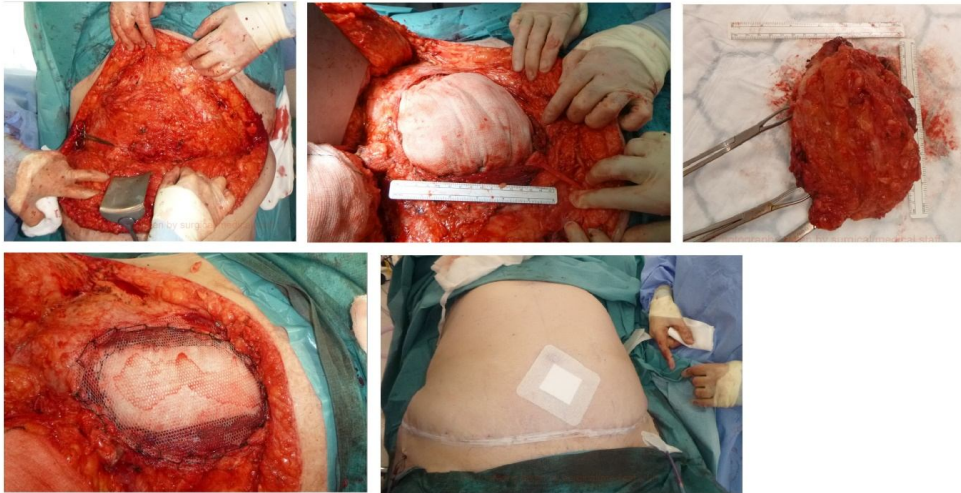


Figure 4: Rectus sheath tumour excision (abdominoplasty approach) and abdominal wall reconstruction [X].

The histopathology report showed a high-grade poorly differentiated adenocarcinoma. All of the surgical margins were clear. Tumour immunohistochemistry demonstrated positive staining for p16 and CK7 with overall impression favouring that of a metastatic HPV-associated adenocarcinoma of cervical origin. The patient has recovered well following surgery and is currently (7.5 years since the initial diagnosis) asymptomatic and disease free.

### Discussion

Isolated port site metastasis is defined as cancer recurrence at trocar sites with no evidence of metastatic disease elsewhere (Gao 2020). It is a rare complication of minimal access surgery for gynaecological cancer and is thought to have an estimated prevalence of 0.2-0.5% (Barres 2015, Lonnerfors 2013). In cervical cancer specifically, there are limited case reports describing port site metastasis (Zhong 2018) and the majority are thought to be associated with squamous cell histological type (Ramirez 2004). The management of port site metastasis is often individualised and is dependent on the distribution of the disease, presence of other metastasis, and patient fitness to undergo further treatment. Options include radical excision alone or in combination with adjuvant chemotherapy and abdominal wall irradiation (Benabou 2020). Benabou et al describe a comparable case of laparoscopically managed FIGO Stage 1B1 endocervical adenocarcinoma where the patient also underwent clinical surveillance. Abdominal wall recurrence was diagnosed after 4 years and this was also near the prior assistant port site; a port which was used for removal of lymph nodes in a laparoscopic bag (Benabou 2020). The recurrence was managed by surgical excision and reconstruction alone, however 3 years later the patient was diagnosed with a second port-site recurrence on the same side of the abdominal wall. Given the infrequent occurrence of port site metastasis and lack of data specific to gynaecological oncology, it difficult to draw conclusions and identify contributing factors. This case report demonstrates that port site metastasis can be successfully managed with surgical excision, as evidenced by this report where the patient is asymptomatic and disease free 7.5 years after her initial cancer diagnosis. It is clear that more research should be done to develop better understanding of the mechanisms and risk factors for port site metastasis in different gynaecological cancers which would in turn help to improve clinical decision making. CONCLUSIONS ?????

**Comment [AEFH6]:** 1. . Barraez, D., Godoy, H., McElrath, T. et al. Low incidence of port-site metastasis after robotic assisted surgery for endometrial cancer staging: descriptive analysis. *J Robotic Surg* 9, 91–95 (2015). <https://doi.org/10.1007/s11701-014-0491-y>

**Comment [AEFH7]:** Reference style  
References must be listed at the end of the manuscript and numbered in the order that they appear in the text. Every reference referred in the text must also present in the reference list and vice versa. In the text, citations should be indicated by the reference number in brackets [3].

**Comment [AEFH8]:** (Benabou2020).  
Benabou et al  
(Benabou2020), ??????????

12. . Benabou K, Khadraoui W, Khader T, Hui P, Fernandez R, Azodi M, Menderes G. Port-Site Metastasis in Gynecological Malignancies. *JLS*. 2021 Jan-Mar;25(1):e2020.00081. doi: 10.4293/JLS.2020.00081. PMID: 33879998; PMCID: PMC8035826.

## Abbreviations:

FIGO = International Federation of Gynecology and Obstetrics, CT = Computed tomography, MRI = Magnetic Resonance Imaging, PET = positron emission tomography, FDG = fluoro-deoxyglucose, SUV = Standardized uptake value, CK7 = Cytokeratin 7, CEA = carcinoembryonic antigen, p16 = p16 protein, TTF1 = Thyroid transcription factor 1, CK20= Epithelial marker with restricted expression, MDT = Multidisciplinary team, HPV = Human papillomavirus

## REFERENCE??????

1. Döbrönte, Z., Wittmann, T., & Karácsony, G. (1978). Rapid development of malignant metastases in the abdominal wall after laparoscopy. *Endoscopy*, 10(2), 127–130. <https://doi.org/10.1055/s-0028-1098280>
2. Ramirez, P. T., Wolf, J. K., & Levenback, C. (2003). Laparoscopic port-site metastases: etiology and prevention. *Gynecologic oncology*, 91(1), 179–189. [https://doi.org/10.1016/s0090-8258\(03\)00507-9](https://doi.org/10.1016/s0090-8258(03)00507-9)
3. Zivanovic, O., Sonoda, Y., Diaz, J. P., Levine, D. A., Brown, C. L., Chi, D. S., Barakat, R. R., & Abu-Rustum, N. R. (2008). The rate of port-site metastases after 2251 laparoscopic procedures in women with underlying malignant disease. *Gynecologic oncology*, 111(3), 431–437. <https://doi.org/10.1016/j.ygyno.2008.08.024>
4. Barraez, D., Godoy, H., McElrath, T. et al. Low incidence of port-site metastasis after robotic assisted surgery for endometrial cancer staging: descriptive analysis. *J Robotic Surg* 9, 91–95 (2015). <https://doi.org/10.1007/s11701-014-0491-y>
5. Lönnfors, C., Bossmar, T., & Persson, J. (2013). Port-site metastases following robot-assisted laparoscopic surgery for gynecological malignancies. *Acta obstetrica et gynecologica Scandinavica*, 92(12), 1361–1368. <https://doi.org/10.1111/aogs.12245>
6. Ndofo BT, Soliman PT, Schmeler KM, et al Rate of Port-Site Metastasis Is Uncommon in Patients Undergoing Robotic Surgery for Gynecological Malignancies *International Journal of Gynecological Cancer* 2011;21:936-940
7. Rindos N, Curry CL, Tabbarah R, Wright V. Port-site metastases after robotic surgery for gynecologic malignancy. *JLS*. 2014 Jan-Mar;18(1):66-70. doi: 10.4293/108680813X13693422519271. PMID: 24680146; PMCID: PMC3939345.
8. Pecorelli, S. (2009). Revised FIGO staging for carcinoma of the vulva, cervix, and endometrium. *International Journal of Gynecology & Obstetrics*, 105: 103-104. <https://doi.org/10.1016/j.ijgo.2009.02.012>
9. Gao Q, Guo L, Wang B. The Pathogenesis and Prevention of Port-Site Metastasis in Gynecologic Oncology. *Cancer Manag Res*. 2020 Oct 6;12:9655-9663. doi: 10.2147/CMAR.S270881. PMID: 33116825; PMCID: PMC7547761.
10. Zhong X, Wang Z, Tang J, Shi J, Li H, Wang J. Port site metastasis after minimally invasive surgery of cervical carcinoma: case report and review of the literature. *Eur J Gynaecol Oncol*. 2018 Jan 1;39(4):671-5.
11. Ramirez, P. T., Frumovitz, M., Wolf, J. K., & Levenback, C. (2004). Laparoscopic port-site metastases in patients with gynecological malignancies. *International journal of gynecological cancer : official journal of the International Gynecological Cancer Society*, 14(6), 1070–1077. <https://doi.org/10.1111/j.1048-891X.2004.14604.x>
12. Benabou K, Khadraoui W, Khader T, Hui P, Fernandez R, Azodi M, Menderes G. Port-Site Metastasis in Gynecological Malignancies. *JLS*. 2021 Jan-Mar;25(1):e2020.00081. doi: 10.4293/JLS.2020.00081. PMID: 33879998; PMCID: PMC8035826.
13. Martínez-Palones, J. M., Gil-Moreno, A., Pérez-Benavente, M. A., García-Giménez, A., & Xercavins, J. (2005). Umbilical metastasis after laparoscopic retroperitoneal paraaortic

**Comment [AEFH9]:** BARRES, 2015  
1. - Barraez, D., Godoy, H., McElrath, T. et al. Low incidence of port-site metastasis after robotic assisted surgery for endometrial cancer staging: descriptive analysis. *J Robotic Surg* 9, 91–95 (2015). <https://doi.org/10.1007/s11701-014-0491-y>

**Comment [AEFH10]:** DOES NOT APPEAR IN TEXT REFERENCES

lymphadenectomy for cervical cancer: a true port-site metastasis?. Gynecologic oncology, 97(1), 292-295. <https://doi.org/10.1016/j.ygyno.2004.11.056>

14. Reymond, M. A., Wittekind, C., Jung, A., Hohenberger, W., Kirchner, T., & Köckerling, F. (1997). The incidence of port-site metastases might be reduced. Surgical endoscopy, 11(9), 902-906. <https://doi.org/10.1007/s004649900483>

**Comment [AEFH11]:** DOES NOT APPEAR IN TEXT REFERENCES

14 REFERENCE. 12 REFERENCE 2003 ATE 2021. (MEDIA = 2012 APROX.)

2 REFERENCE. 1978- 1997.

PLEASE ENDORSE TO UPDATE THESE REFERENCES.

UNDER PEER REVIEW