

# Management of bilateral tension pneumothorax with extensive subcutaneous emphysema during one-lung ventilation

## ABSTRACT

**Introduction:** Severe intraoperative complications during thoracic procedures requiring one-lung ventilation (OLV) are rare but potentially life-threatening. Double-lumen endotracheal tubes (DLT) are commonly used but can lead to complications such as bilateral tension pneumothorax, presenting significant challenges for anesthesiologists and thoracic surgeons. This case highlights a critical incident during a mediastinoscopy under general anesthesia with OLV.

**Case Presentation:** A 43-year-old male with a history of Hodgkin's lymphoma underwent a mediastinoscopy. Anesthesia induction and intubation with a 37 French Carlen DLT were performed. Shortly after initiating OLV, the patient experienced sudden hypoxemia (SpO<sub>2</sub> 65%), increased peak airway pressures, bradycardia, and hypotension. Bilateral tension pneumothorax with subcutaneous emphysema was diagnosed, and emergency bilateral chest drain insertion stabilized the patient.

**Discussion:** This case illustrates the severity of DLT-associated complications, particularly tension pneumothorax caused by tube malpositioning and barotrauma. Diagnosing tension pneumothorax is challenging due to similar symptoms with other intraoperative issues. Clinical signs include severe hypoxemia, hypercarbia, hypotension, and increased airway pressures. Rapid diagnosis through chest X-rays and ultrasonography, along with immediate management, such as chest drain insertion, is crucial.

**Conclusion:** The case emphasizes the importance of vigilance and preparedness to manage anesthetic complications during thoracic procedures. Rigorous verification of DLT positioning, continuous monitoring, and prompt interventions are essential to prevent catastrophic events.

**Keywords:** Bilateral Pneumothorax-Subcutaneous emphysema-Double Lumen Tube (DLT)-One Lung Ventilation OLV - Anesthesia Complications

## INTRODUCTION

Double-lumen endotracheal tubes (DLTs) are frequently utilized in thoracic surgery for lung isolation and one-lung ventilation (OLV). While complications associated with DLTs are extensively discussed in major anesthesiology reports [1][2], tension pneumothorax, an urgent and life-threatening condition,

is often overlooked in these discussions. Tension pneumothorax occurs when air accumulates within the pleural space, leading to increased pressure on intrathoracic structures and compromising cardiac function and respiratory mechanics. Early recognition and prompt intervention are imperative to mitigate its potentially fatal consequences.

Tension pneumothorax is an uncommon condition that can be fatal if left untreated [3]. Intraoperative tension pneumothorax can be extremely dangerous, especially during OLV, and is a rare complication. It can cause sudden death or serious long-term organ damage. Notably, tension pneumothorax occurring specifically in the dependent ventilated lung during OLV is a scarcely documented phenomenon. Our case report contributes to the existing literature by presenting such a case, highlighting the importance of vigilance and preparedness among anesthesiologists and thoracic surgeons when managing complex thoracic procedures.

While DLTs offer precise control over ventilation during thoracic surgery, anesthesiologists must remain vigilant for rare but potentially life-threatening complications such as tension pneumothorax. Continued vigilance, prompt recognition, and swift intervention are crucial in optimizing patient outcomes during complex thoracic procedures.

## **CASE REPORT**

A 43-year-old male, weighing 90 kg, with a medical history significant for Hodgkin lymphoma treated with chemotherapy, was scheduled for biopsy of lymphadenopathy via mediastinoscopy with a minimally invasive approach under left one-lung ventilation with a double-lumen endotracheal tube (DLT). Pre-anesthetic assessment revealed no complaints of dyspnea or chest discomfort.

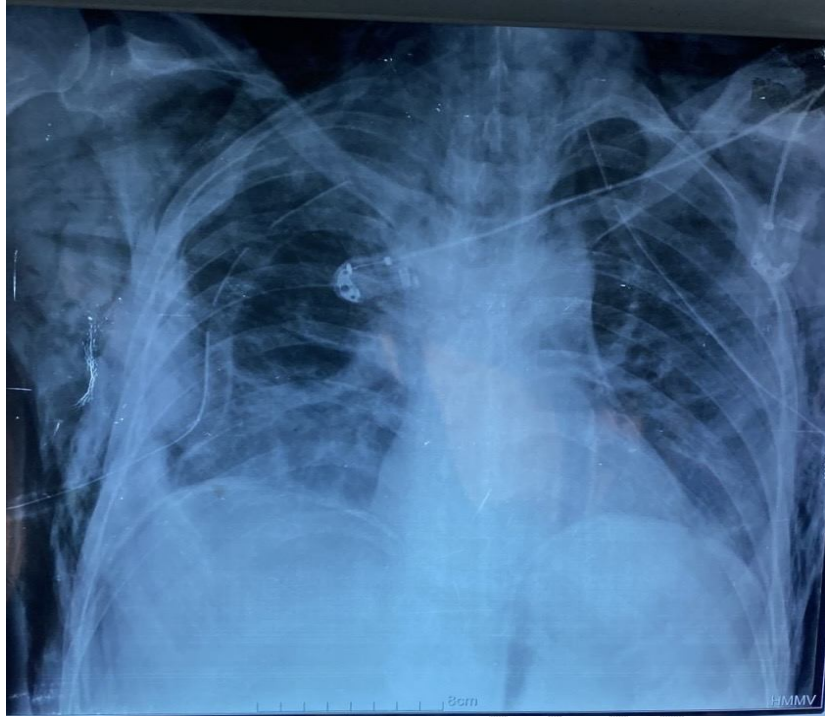
Intra-operative monitoring included non-invasive blood pressure measurement, electrocardiography, pulse oximetry, and end-tidal carbon dioxide (etCO<sub>2</sub>) concentration measurement. Anesthesia was induced with fentanyl 250 µg, propofol 250 mg, and rocuronium 50 mg. After 2 minutes of mask ventilation with FiO<sub>2</sub> = 100%, the trachea and left main bronchus were intubated with a 37 French double-lumen endobronchial tube (Carlen's). Following tracheal intubation, the stylet was removed, and the tube was turned 90° counterclockwise and advanced until moderate resistance was felt. The tracheal and bronchial cuffs were inflated until moderate tension was palpated in the pilot balloons (5 mL for the tracheal cuff and 2 mL for the bronchial cuff were required). Bilateral lung ventilation and isolation were confirmed by auscultation and fiberoptic bronchoscopy. Anesthesia was maintained with air: 55%, oxygen: 45%, and isoflurane: 1.5%. The patient was ventilated bilaterally with a tidal volume of 450 mL at a rate of 10 breaths/min, maintaining peak airway pressure between 16 and 18 cm H<sub>2</sub>O. Subsequently, the patient was placed in the left lateral decubitus position, and lung isolation was confirmed again by auscultation and fiberoptic bronchoscopy.

Upon clamping the tracheal lumen of the double-lumen tube to collapse the right non-dependent lung for thoracoscopy, the patient's oxygen saturation decreased to 65%, peak airway pressure increased to 30 cm H<sub>2</sub>O, heart rate decreased to 35 beats/min, blood pressure dropped to 70/30 mmHg, and end-tidal CO<sub>2</sub> also decreased to 10 mmHg. Manual ventilation with 100% oxygen was challenging. One-lung ventilation was switched to two-lung ventilation, and a phenylephrine bolus was administered, and norepinephrine infusion were started. Upon turning the patient to the supine position, the abdomen became tense, and subcutaneous emphysema developed from head to legs.

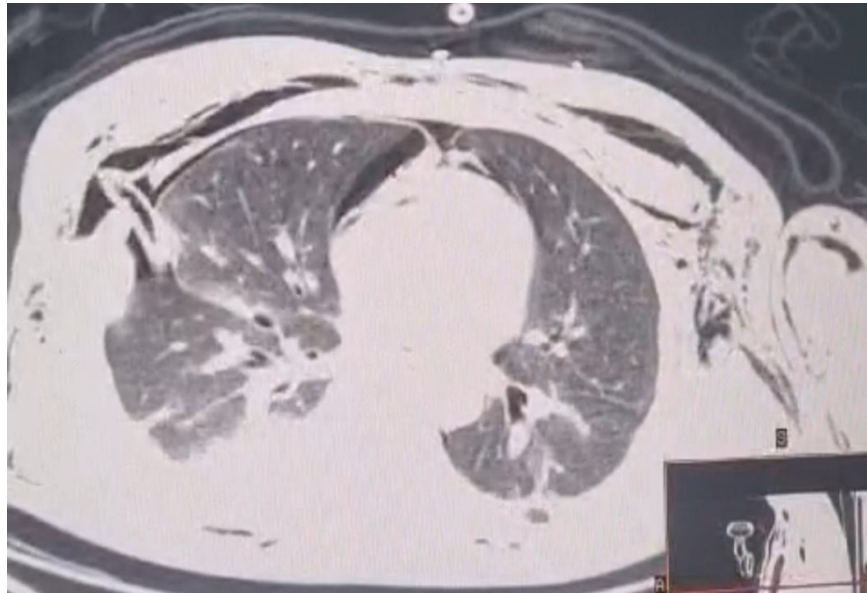
Absence of chest expansion on both sides, with hyperresonance on percussion, led to a tentative diagnosis of major airway trauma with bilateral tension pneumothorax.

Given this situation of desaturation, hemodynamic instability, and subcutaneous emphysema, emergency bilateral pneumothorax drainage was performed by simultaneously inserting a 26 French chest tube at the 4th-5th intercostal space on the left and the 3rd-4th intercostal space on the right. Additionally, the patient was reintubated with a single-lumen endotracheal tube. Following these procedures, there was improvement in vital parameters, including oxygen saturation (SpO<sub>2</sub>) and hemodynamic status. Symmetrical and bilateral chest expansion was observed, accompanied by reassuring auscultation findings. On tracheobronchofibroscope there was no visible mechanical injury. A chest X-ray was performed, revealing both drains in place, bilateral pneumothorax, and subcutaneous emphysema extending from the thorax to the neck [Figure 1]. These findings were subsequently confirmed by thoracic CT scan [Figure 2]. Following extubation in the operating room, the patient was transferred to the intensive care unit (ICU) for further monitoring. Post-extubation, the patient regained full consciousness and responsiveness. In the ICU, while receiving 40% oxygen via mask, arterial blood gas analysis showed parameters within the normal range, indicating improvement in the patient's condition. Arterial blood gas and oxygen saturation remained stable during this period. The following day, the patient became fully alert and oriented, initiating oral fluid intake. Complete resolution of subcutaneous emphysema was observed. With stable oxygen saturation of 98% on room air, the patient was transferred to the ward with the chest tube in situ. The chest tube was removed on the 4th postoperative day, followed by a subsequent chest radiography showing normal findings. The patient was discharged from the hospital on the 5th postoperative day.

**Figure 1: Chest X-ray revealing both drains in place, bilateral pneumothorax, and subcutaneous emphysema extending from the thorax to the neck :**



**Figure 2: Thoracic CT scan showing bilateral pneumothorax with right and left chest tubes in place, pneumomediastinum, and subcutaneous emphysema.**



## DISCUSSION

The occurrence of bilateral tension pneumothorax and extensive subcutaneous emphysema in a patient undergoing mediastinoscopy with one-lung ventilation (OLV) underscores the significant risks associated with airway management during thoracic procedures, particularly when using double-lumen endotracheal tubes (DLTs) [4]. Tension pneumothorax, although rare, poses a significant threat to patient safety if left untreated [5]. Its occurrence during OLV in the intraoperative setting adds complexity to an already delicate surgical scenario. Hoechter et al. [6] noted a limited number of cases published up to 2018, highlighting the rarity of this complication. However, it is important to recognize the potential for underreporting, as evidenced by the discrepancy between reported cases and the actual incidence observed in larger patient cohorts [6].

Clinical manifestations of tension pneumothorax are characterized by a rapid deterioration in oxygen saturation, diminished cardiac output, elevated airway pressures, and ventilation disturbances, particularly in the ipsilateral lung [7][8]. These manifestations arise from the displacement or compression of mediastinal structures and lung parenchyma, as well as the presence of air in anatomical spaces. The reduction in cardiac output is multifactorial, likely stemming from hypoxemia, impaired venous return, and mechanical compression of cardiac structures and the contralateral lung [9]. Without prompt recognition and intervention, tension pneumothorax can progress rapidly, potentially culminating in cardiac arrest [10].

**Mechanisms and Risk Factors** The development of tension pneumothorax during OLV, although rare, is a recognized complication that can arise from several mechanisms. One primary cause is barotrauma due to the malpositioning of the DLT, leading to over-distension of a single lung segment. In this case, surgical manipulation likely caused the DLT to shift, resulting in malpositioning and subsequent barotrauma, where the entire tidal volume was delivered preferentially to the left lower lobe. This scenario aligns with previous reports highlighting the risk of barotrauma from DLT malpositioning during thoracic surgery [11] [12] [13]

In this case, the possibility is the displacement of the DLT during the transition to the lateral position for thoracoscopy. This scenario could lead to malpositioning of the tube, causing uneven ventilation and overdistension of certain lung segments, thereby increasing the risk of barotrauma and tension pneumothorax. The use of vigorous positive pressure ventilation while in a right bronchial intubated state may have precipitated the development of tension pneumothorax. The presence of high inspiratory peak pressures following the placement of the double-lumen endotracheal tube (DLT). In our patient after single-lumen tube reintubation with adequate mechanical ventilation, we could not find any laceration or perforation of the tracheobronchial wall.

Careful monitoring and reassessment of DLT placement after patient repositioning are crucial to prevent such complications. This highlights the importance of meticulous attention to ventilation parameters and tube position during thoracic procedures to mitigate the risk of catastrophic outcomes. Additionally, patients with underlying pulmonary pathology, such as COPD, are at an increased risk of pneumothorax during positive pressure ventilation due to their already compromised alveolar integrity [14][15]. While this patient did not have a known history of emphysema, the mechanical forces during OLV and mediastinal manipulation were sufficient to precipitate tension pneumothorax.

Recent studies emphasize the importance of advanced monitoring techniques to detect early signs of complications during thoracic surgery. For instance, lung ultrasound has proven valuable in quickly diagnosing pneumothorax in the intraoperative setting [16]. Additionally, continuous end-tidal CO<sub>2</sub> monitoring can provide early indicators of ventilation issues, which might precede clinical signs of pneumothorax [17].

**Diagnostic Challenges and Management :** Diagnosing tension pneumothorax in the context of OLV is particularly challenging [18]. The signs of hypoxemia, hypotension, and increased airway pressures are relatively common during thoracic surgery and can easily be attributed to other intraoperative issues such as tube malposition or ventilation-perfusion mismatch [19]. In this case, the presence of bilateral subcutaneous emphysema and the rapid decline in respiratory and cardiovascular parameters were key indicators that led to the provisional diagnosis of major airway trauma and bilateral tension pneumothorax.

Immediate intervention involved the insertion of chest tubes bilaterally, which resulted in rapid stabilization of the patient's vital signs. This step was crucial and is consistent with recommended emergency management for suspected tension pneumothorax [18]. The reintubation with a single-lumen endotracheal tube further facilitated adequate ventilation and oxygenation, allowing for subsequent diagnostic confirmation and ongoing management.

## **CONCLUSION**

This case underscores the critical importance of vigilance and prompt intervention in managing anesthetic complications during thoracic surgery. The integration of these practices can significantly improve patient outcomes and prevent catastrophic events.

### **CONFLICT OF INTEREST STATEMENT**

The authors declare no conflicts of interest related to this case report.

### **ETHICS STATEMENT**

None.

### **CONSENT**

Written informed consent was obtained from the patient's next of kin.

### **REFERENCES**

1. Langiano N, Fiorelli S, Deana C, Baroselli A, Bignami EG, Matellon C, Pompei L, Tornaghi A, Piccioni F, Orsetti R, Coccia C, Sacchi N, D'Andrea R, Brazzi L, Franco C, Accardo R, Di Fuccia A, Baldinelli F, De Negri P, Gratarola A, Angeletti C, Pugliese F, Micozzi MV, Massullo D, Della Rocca G. Airway management in anesthesia for thoracic surgery: a "real life" observational study. *J Thorac Dis.* 2019 Aug;11(8):3257-3269. doi: 10.21037/jtd.2019.08.57. Erratum in: *J Thorac Dis.* 2022 Sep;14(9):3651-3652. PMID: 31559028; PMCID: PMC6753428.
2. Benumof JL, Alfery DD: Anesthesia for thoracic surgery. In: Miller RD (ed): *Anesthesia*, 5th ed. New York: Churchill Livingstone, 2000:1689–705.
3. Hoechter DJ, Speck E, Siegl D, Laven H, Zwissler B, Kammerer T. Tension Pneumothorax During One-Lung Ventilation - An Underestimated Complication? *J Cardiothorac Vasc Anesth.* 2018 Jun;32(3):1398-1402. doi: 10.1053/j.jvca.2017.07.022. Epub 2017 Jul 21. PMID: 29361455.

4. Cohen E. Recommendations for airway control and difficult airway management in thoracic anesthesia and lung separation procedures. Are we ready for the challenge? *Minerva Anestesiologica*. 2009 Jan-Feb;75(1-2):3-5. Epub 2008 Nov 28. PMID: 19039300.
5. Rojas R, Wasserberger J, Balasubramaniam S. Unsuspected tension pneumothorax as a hidden cause of unsuccessful resuscitation. *Ann Emerg Med* 1983; 12: 411-2.
6. Hoechter DJ, Speck E, Siegl D, Laven H, Zwissler B, Kammerer T. Tension pneumothorax during one-lung ventilation - an underestimated complication? *J Cardiothorac Vasc Anesth* 2018; 32: 1398-402
7. Heyba M, Rashad A, Al-Fadhli AA. Detection and Management of Intraoperative Pneumothorax during Laparoscopic Cholecystectomy. *Case Rep Anesthesiol*. 2020 Apr 7;2020:9273903. doi: 10.1155/2020/9273903. PMID: 32318295; PMCID: PMC7166272.
8. Lee SK, Seo KH, Kim YJ, Youn EJ, Lee JS, Park J, Moon HS. Cardiac arrest caused by contralateral tension pneumothorax during one-lung ventilation: - A case report. *Anesth Pain Med (Seoul)*. 2020 Jan 31;15(1):78-82. doi: 10.17085/apm.2020.15.1.78. PMID: 33329794; PMCID: PMC7713858.
9. Gabbott DA, Carter JA. Contralateral tension pneumothorax during thoracotomy for lung resection. *Anaesthesia*. 1990 Mar;45(3):229-31. doi: 10.1111/j.1365-2044.1990.tb14692.x. PMID: 2159249
10. Leigh-Smith S, Harris T. Tension pneumothorax--time for a re-think? *Emerg Med J*. 2005 Jan;22(1):8-16. doi: 10.1136/emj.2003.010421. PMID: 15611534; PMCID: PMC1726546.
11. Baek J, Park SJ, Seo M, Choi EK. Unexpected Tension Pneumothorax after Double-Lumen Endotracheal Intubation in Patients with Pulmonary Edema: A Case Report. *Medicina (Kaunas)*. 2023 Feb 25;59(3):460. doi: 10.3390/medicina59030460. PMID: 36984461; PMCID: PMC10058528.
12. Finlayson, Gordon N. MD, FRCP; Brodsky, Jay B. MD. Tension Pneumothorax During One-Lung Ventilation. *Anesthesia & Analgesia* 106(5):p 1590-1591, May 2008. | doi: 10.1213/ane.0b013e31816b53a8
13. Sivalingam P, Tio R. Tension pneumothorax, pneumomediastinum, pneumoperitoneum, and subcutaneous emphysema in a 15-year-old Chinese girl after a double-lumen tube intubation and one-lung ventilation. *J Cardiothorac Vasc Anesth*. 1999 Jun;13(3):312-5. doi: 10.1016/s1053-0770(99)90270-7. PMID: 10392684.
14. Hsu CW, Sun SF. Iatrogenic pneumothorax related to mechanical ventilation. *World J Crit Care Med*. 2014 Feb 4;3(1):8-14. doi: 10.5492/wjccm.v3.i1.8. PMID: 24834397; PMCID: PMC4021154.

15. Amaniti E, Provitsaki C, Papakonstantinou P, Tagarakis G, Sapalidis K, Dalakakis I, Gkinas D, Grosomanidis V. Unexpected Tension Pneumothorax-Hemothorax during Induction of General Anaesthesia. *Case Rep Anesthesiol.* 2019 Feb 24;2019:5017082. doi: 10.1155/2019/5017082. PMID: 30923639; PMCID: PMC6409028.
16. Goffi A, Kruisselbrink R, Volpicelli G. The sound of air: point-of-care lung ultrasound in perioperative medicine. *Can J Anaesth.* 2018 Apr;65(4):399-416. English. doi: 10.1007/s12630-018-1062-x. Epub 2018 Feb 6. PMID: 29411300.
17. Lee GM, Kim YW, Lee S, Do HH, Seo JS, Lee JH. End-Tidal Carbon Dioxide Monitoring for Spontaneous Pneumothorax. *Emerg Med Int.* 2021 Jun 14;2021:9976543. doi: 10.1155/2021/9976543. PMID: 34234966; PMCID: PMC8216832.
18. Bacon AK, Paix AD, Williamson JA, Webb RK, Chapman MJ. Crisis management during anaesthesia: pneumothorax. *Qual Saf Health Care.* 2005 Jun;14(3):e18. doi: 10.1136/qshc.2002.004424. PMID: 15933291; PMCID: PMC1744020.
19. Alexander Ng, Justiaan Swanevelder, Hypoxaemia during one-lung anaesthesia, *Continuing Education in Anaesthesia Critical Care & Pain*, Volume 10, Issue 4, August 2010, Pages 117–122, <https://doi.org/10.1093/bjaceaccp/mkq019>