

# Case Report and Review of Pemphigus Vulgaris

---

## ABSTRACT

**Introduction:** Currently the real cause of pemphigus vulgaris is unknown, however, it has been considered a genetic predisposition, associated with certain haplotypes (HLA), such as HLA-DR4 in the Jewish population, and HLA-DR14 and HLA-DR10 in Mexicans.

**Objective:** To report, and review the literature, in a case of blistering skin and scaly oral lesions consistent with Pemphigus Vulgaris in an 8-year old girl.

**Case presentation:** 8-year-old female, presenting with reactive blisters. Physical examination revealed scaly areas, scars in various stages, blisters and bullae on the extremities, abdomen and face.

**Conclusions:** Interdisciplinary work between doctors and dentists allows the early detection and treatment of systemic pathologies in order to reduce their impact.

*Keywords: Pemphigus, Mouth, Surgery Oral, Dermatology*

## Introduction

In this case report we review the definition of Pemphigus vulgaris over the past 300 years, the first being in 1791 when Doctor Wickman described a blistering skin disease. By 1881, Doctor Auspitz presented histological sections where the disappearance of the intercellular bridges of the keratinocytes could be seen, calling this phenomenon acantholysis. In 1892, Dr. Ernest Besnier described a very pruritic chronic dermatosis that began with papulovesicular lesions with suppuration and crusting. Finally, it is considered that in 1943 Doctors Darier and Civatte gave importance to the diagnosis of this pathology[14]. Currently we know that pemphigus comprises a group of autoimmune diseases where antibodies ignore the surface cells of keratinocytes, producing acantholysis and consequently forming blisters.<sup>1-3</sup>

## Etiology

The exact cause of pemphigus vulgaris remains unknown, although several theories and factors have been proposed that could be involved in its etiology and pathogenesis. A genetic predisposition has been suggested, associated with certain haplotypes (HLA), such as HLA-DR4 in the Jewish population, and HLA-DR14 and HLA-DR10 in Mexicans. In addition, it has been observed that certain medications, such as phenylbutazone, piroxicam, rifampicin and captopril, can induce an autoimmune response. Other triggering factors have also been

identified, such as burns and radiotherapy. In the context of the autoimmune response, the formation of antibodies occurs, mainly of the IgG4 subclass, which react with the Dsg desmogleins, located in the desmosomes of the cell surface of keratinocytes, especially Dsg1 of 160 kDa and Dsg3 of 130 kDa. . . These antibodies inhibit the adhesive function of Dsg, triggering a series of intracellular events, such as changes in intracellular calcium concentration and activation of phosphokinase C, stimulation of the mitogenic activated protein kinase p58, transcriptional regulation and activation of the proteinases. These events lead to the disassembly of desmosomes, resulting in blister formation. The genetic factor is considered to contribute to the development of pemphigus vulgaris by allowing the presentation of Dsg3 or Dsg1 peptides to TH1 cells. Furthermore, it has been discovered that some peptides derived from Dsg3 have the ability to bind to the binding site of an HLA-DR3<sup>4</sup>.

### **Epidemiology**

Although it has been considered the most common form of pemphigus, this will depend on geographical location and race, and its prevalence has been documented in the Jewish and Indian populations. Affecting men and women equally, occurring at any time of life with a higher incidence in the fourth to sixth decade of life. It has been estimated to occur with a distribution of 0.76:100,000 in Finland, 1.61:100,000 in Jerusalem, 1.6-3.2:100,000 in Ashkenazi. The mortality rate has been decreasing over the years, in 1950 it was 75%, with the appearance of corticosteroids it decreased to 30% and today it rarely exceeds 5%<sup>3-7</sup>.

### **Clinical features**

Blisters appear on the skin and mucosa, which are very painful, especially in the oral cavity, and are usually accompanied by symptoms such as salivation and bloody saliva. After a few weeks or months after the first lesion on the mucosa, blisters appear in other areas of the skin, predominantly in the scalp, inguinal folds, armpit, navel, and submammary region. The size of the lesion is varied; it can range from a few millimeters to lesions measuring 3cm in diameter, which are flaccid and rupture, leaving denuded areas, with meliceric scabs and dermal excoriations<sup>4,5,8</sup>.

### **Diagnosis**

The correct diagnosis is achieved through four main criteria, which include clinical and histopathological manifestations, direct immunofluorescence tests for the perilesional area or performing mucosal biopsy and serological detection; ELISA or immunoblot can also be used. The diagnosis is divided into two: those that correlate with anti-Dsg3 autoantibodies, when it affects the mucosa and the skin, a relationship is formed with Dsg1 and Dsg3. Acupressure shows a positive Nikolsky with Asboe-Hansen sign<sup>4,8</sup>.

### **Differential diagnosis**

It should include pathologies that manifest in the mucosa and skin such as bullous pemphigus, erythema multiforme, herpes simplex, dermatitis herpetiformis and exudative erythema multiforme<sup>9</sup>.

### **Histopathological**

It is recommended to perform a biopsy of the gallbladder within 24 hours of its generation; if this is not possible, it is recommended to take a third of the peripheral portion of a blister. At a microscopic level, acantholysis is seen in the granular stratum, suprabasal intraepidermal blisters with multiple acantholytic keratinocytes, perivascular inflammation of lymphocytes, eosinophils and neutrophils and suprabasal blisters<sup>4,10</sup>.

### Treatment

Currently there is no definitive treatment, the first choice treatment is based on the administration of corticosteroids that can be oral, pulsed or topical. While second-line treatments, corticosteroids as monotherapy and plasmapheresis are recommended. Which offer temporary and minor adverse effects. The administration of anti-CD20 together with corticosteroids and azothioprine with topical corticosteroids has also been reported<sup>4,8,11,12</sup>.

### Case presentation

An 8-year old girl presented to the maxillofacial surgery clinic with a history of repeated 'injuries' caused by minor skin trauma such as scratching or other minor abrasions. On physical examination, scaly areas, scars in various stages and blisters and bullae can be seen, which are distributed as follows: On the arm, a 3x2.5x1.5cm bulla can be seen, areas of healing in the proliferative phase and remodeling on the forearm, Note areas of hyperpigmentation. On the hand: well-defined areas of hypopigmentation can be seen on the fingers of the right hand on the phalanges and areas of hyperpigmentation on the knuckles, color changes due to scarring and the presence of scarring in the remodeling phase on the index, middle and ring fingers. In the abdominal region there are areas of hyperpigmentation that cover the umbilical and periumbilical region where scars can be seen in the inflammation, proliferative and remodeling phases. On the face: blisters are observed in the chin region ranging from 0.2mm to 0.5mm. In the antrum of the nostrils at the height of Cupid's bow two blisters 0.5mm in diameter. And in the area of the wing of the nose above the nasolabial fold 3 blisters ranging from 0.5mm to 6mm in their greatest diameter. Figure 1.

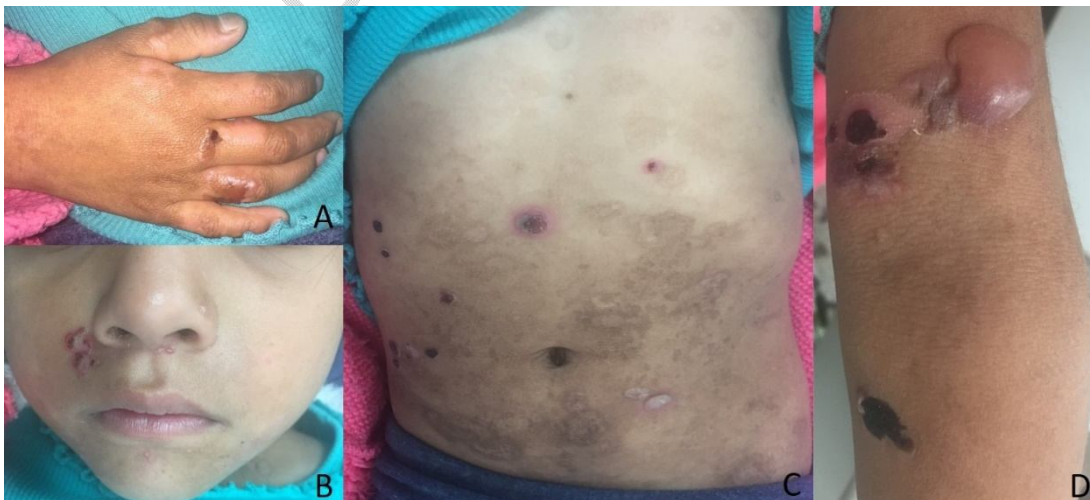


Figure 1: A) well-defined areas of hypopigmentation can be seen on the fingers of the right hand in the phalanges and areas of hyperpigmentation. B) blisters in the chin region, in the antrum of the nasal passages at the level of Cupid's bow C) areas of hyperpigmentation that

cover the umbilical and periumbilical region where scars can be seen in the inflammation, proliferative and remodeling phases. D) On the arm there is a 3x2.5x1.5cm bulla, areas of healing in the proliferative phase.

On intraoral examination, an erythematous area was located in the lining mucosa of the right cheek. On the tongue, peeling of the taste buds, localized gingivitis and gingival hyperplasia in the dental organs occur 11,12,21,22. It is indicated to keep the mucosa hydrated with saliva substitute and Sorensen's solution. It refers to the dermatology department where the application of Triticum vulgare 10g, fusidic acid cream 2%, and application of Vaseline and moisturizing cream is indicated. Figure 2.

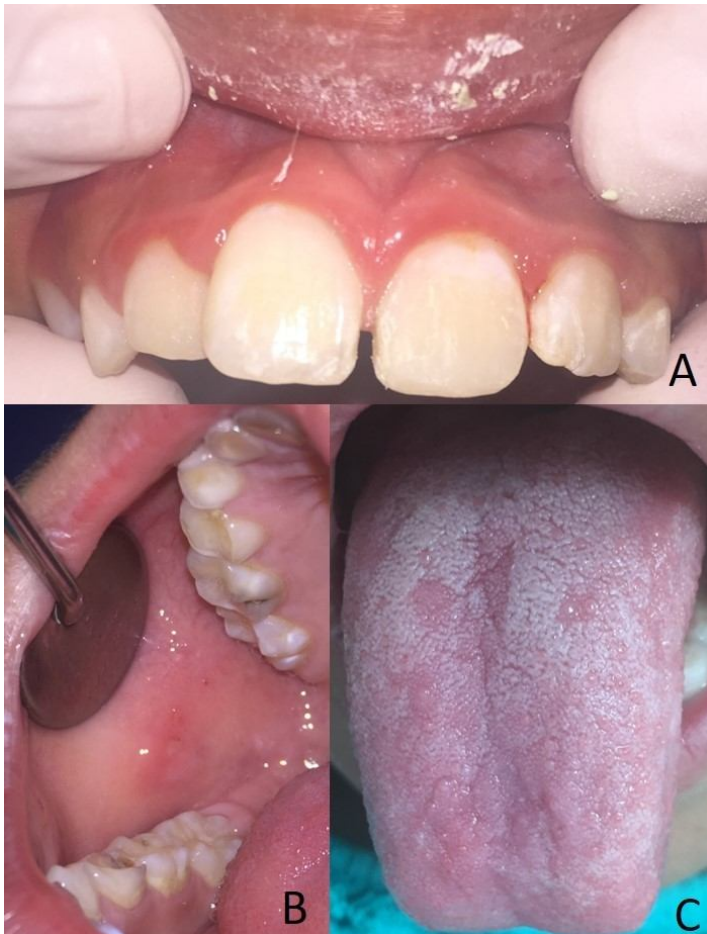

Figure 2: A) localized gingivitis and gingival hyperplasia in the dental organs. B) right cheek an erythematous area. C) Peeling of the taste buds occurs on the tongue.

Surgical time is scheduled to take an excisional biopsy, obtaining as macroscopic results a fragment of skin that measures 0.9x0.7x0.7cm, on its epidermal surface that shows a grayish-brown serohematic scab, when cut, it is uniformly solid. color. white. Microscopically: the histopathological sections show thin skin with suprabasal acantholysis, the stratum corneum is seen detached, in the superficial dermis a mononuclear inflammatory infiltrate is

observed arranged in a band and around the skin annexes. The reticular dermis and subcutaneous cellular tissue do not show alterations. Figure 3.

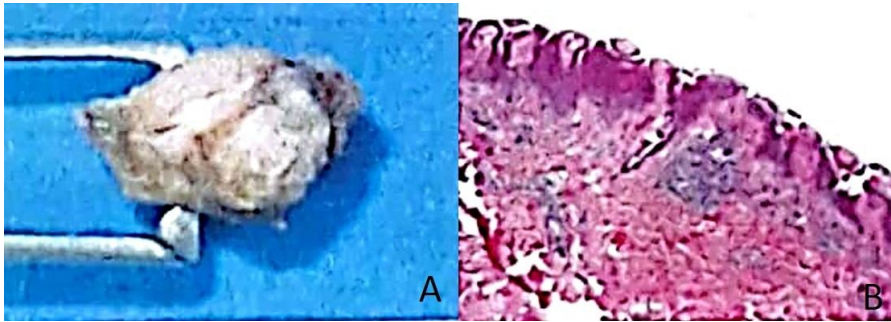


Figure 3: A) skin fragment on its epidermal surface showing a grayish-brown serohematic crust; when cut, it is uniformly solid and white. B) Thin skin with suprabasal acantholysis is shown.

With the data provided, the diagnosis of pemphigus vulgaris, negative for malignancy, is confirmed. Treatment by a dermatologist continues.

### Discussion

Cáceres-Obregón LE in 2024 recommends evaluating the impact of patients' quality of life using questionnaires such as the Dermatology life quality index (DLQI) and other more specific ones such as the Autoimmune bullous disease quality of life (ABQOL) or the Treatment autoimmune bullous disease quality of life (TABQOL)<sup>13</sup>.

Calvo-Moreno GD and Serrano OA in 2024 denote the importance of taking a correct anamnesis, investigating the possible induction of new drugs such as angiotensin-converting enzyme inhibitors (ACE inhibitors) and angiotensin II receptor antagonists (ARA-II), beta blockers, cephalosporins, rifampicin or penicillin. It also demonstrates that body weight, blood pressure, temperature, Karnofsky index, diabetes, cardiovascular disease and neoplasms must be considered<sup>5</sup>.

### Conclusion

Interdisciplinary work between doctors and dentists allows for the early detection and treatment of systemic pathologies in order to reduce their impact.

Ethical Approval:

As per international standards or university standards written ethical approval has been collected and preserved by the author(s).

Consent

As per international standards, parental written consent has been collected and preserved by the author(s).

## References

1. Mercado-Villarreal ME, Castillo LD, González-Sánchez SD. Case report: Pemphigus vulgaris. Conference procedures for research sessions in dentistry. 2023;3(3):58-63.
2. Delaire PL. History of eczema in general; that of atopic dermatitis in patients. *Ann Dermatol Venereol*. 2000;127:657-659.
3. Castellanos-Íñiguez AA, Guevara GE. Pemphigus vulgaris. *Dermatology Rev Mex*. 2011;55(2):73-83.
4. Medina-Vicent NA. Pemphigus vulgaris and foliaceus: An overview of the current therapies. *Dermatol Rev Mex*. 2023;67(4):518-529.
5. Calvo-Moreno GD, Serrano OA. Update on the management of pemphigus vulgaris. *More dermatol*. 2024;45:5-10.
6. Barnales SA, Neves JE, Fuenzalida CH, Pereira RF. Pemphigus vulgaris. *Fur*. 2024;39(5):279-288.
7. Veneri N, Al-Nakash DB, Martínez RN, Leco BI, Madrigal-Martínez PC, Martínez-González JM. Mucous pemphigus Vulgarus: about a case. *Cient Dent literature review*. 2021;18(4)::427-253.
8. Barrera-Arango MJ, Ortiz-Bonilla JA, Maya-Matamoros SP, Villalta-Barreto ME. Pemphigus vulgaris: advances and treatments. *Sun. Hundred*. 2023;9(4):256-270.
9. Regezi S. *Oral Pathology: Clinical Pathologic Correlations*. (7th ed). Inter-American Editorial. 2017.
10. López-Zenteno BE, Cano-Aguilar LE, Argüelles HJ, Herrera CA. Non-paraneoplastic oral pemphigus vulgaris in young adults. *Dermatol Rev Mex*. 2020;64(6):722-728.
11. Cura MJ, Torre AC, Cueto-Sarmiento KY, Bollea-Garlatti ML, Riganti J, Puga MC, Mazzuocolo LD. Pemphigus vulgaris: retrospective cohort study of its clinical characteristics, treatments used and evolution. *Derma-Syphiliographic Records*. 2020;3(5):398-407.
12. RS Market. Infantile pemphigus vulgaris. Presentation of a case. *Student Medical Gazette*. 2020;1(1):57-66.
13. Cáceres-Obregón LE. Case report: Pemphigus Vulgarus. (Internet). *Magazines.unsaac*. (cited May 27, 2024). Available at: <https://revistas.unsaac.edu.pe/index.php/SITUA/article/view/1080/1439>

14. Robinson JC, Lozada-Nur F, Frieden I. Oral pemphigus vulgaris: a review of the literature and a report on the management of 12 cases. *Oral Surgery, Oral Medicine, Oral Pathology, Oral Radiology, and Endodontology*. 1997 Oct 1;84(4):349-55.

UNDER PEER REVIEW