

Original Research Article

Outcome of Propranolol and in Combination with Intralesional Triamcinolone Therapy in Infantile Haemangioma

ABSTRACT

Background: Infantile haemangiomas (IHs) are the most common vascular tumors of infancy. Oral propranolol has achieved great success in treating IHs since 2008. Recently combined oral propranolol with intralesional injection of Triamcinolone acetonide is the effective method of treatment for infantile haemangioma with minimal adverse effects. **Objectives:** To observe the effectiveness of oral propranolol and in combination with intralesional Triamcinolone acetonide therapy in infantile haemangioma. **Materials and Methods:** This prospective comparative study was carried out in the Department of Paediatric Surgery, Sylhet MAG Osmani Medical College Hospital, Sylhet during the period from January 2018 to December 2019. 42 patients with infantile haemangioma requiring medical treatment were selected. Infantile haemangioma with arrhythmia, asthma, history of hypoglycemia, diabetes mellitus, hypertension, hypotension, liver failure, renal failure; family history with regard to atopy, or recent/repeated outbreak of wheezing; failure of medical treatment; and congenital haemangiomas and vascular malformations were excluded. They were divided in to two groups each consisting 21 by random allocation using odd and even number. The odd number was taken in group-A and even number was taken in Group-B. The patients in Group-A was treated with oral propranolol and those in Group-B was treated with oral propranolol in combination with intralesional Triamcinolone acetonide. In group-A, propranolol was starting at a dose of 1 mg/kg per day in two divided doses and increased to 2mg/kg/d on the second day, if tolerated well. In case of adequate response with only minor side effects, the drug was continued at 2 mg/kg/d. Maximum dose was kept at 3 mg/kg/d and was given only if the lesion did not improve further for more than 1 month at any point of treatment. In Group-B, intralesional injection Triamcinolone acetonide 40 mg/mL in a dose of 0.1 to 0.2 ml per square centimeter of involved skin full strength in small sized haemangioma or diluted with local anesthetics, maximum dose of 3-4 mg/kg body weight. Maximum 3 cycles were given in 4 weeks interval. After intralesional injection, all the patients were received oral Propranolol in similar manner in Group-A. Patients of either group were followed up on every 4 weeks' interval for first 3 months and finally at 6 weekly intervals for a period of 3 months. **Results:** The median age of the patients (10.0 months versus 10.5 months; $p=0.457$) and sex (61.9% female versus 71.4% female; $p=0.744$) did not differ significantly between the groups. The mean size (5.76 ± 2.53 cm versus 4.79 ± 2.70 , $p=0.234$). Medium size of IH was more frequent types in both groups (71.4% and 52.4% respectively) and the difference was not significant ($p=0.094$). Site of IH was more common in head and neck region, 47.6% and 57.1% respectively in group-A and Group-B ($p=0.809$). Type of IH was mixed types in both groups, 17 (81.0%) and 17 (81.0%) respectively in group-A and Group-B ($p=0.451$). Pretreatment complications (38.9% versus 14.3%; $p=0.132$) patients presented with some complications in Group-B; the difference was not significant ($p=0.132$). Excellent response in regression of size was 38.1% in group-A and 71.4% in Group-B, Excellent response was much more in Group-B but did not reach the level of significance ($p=0.080$). Excellent colour regression was 9.5% of patients in group-A and 90.5% of patients in Group-B. Colour regression was significantly more in Group-B compared to group-A ($p<0.001$). The mean treatment cost was 124.76 ± 30.88 Taka per patient in group-A and was 187.86 ± 39.70 Taka per patient in Group-B. Treatment cost was significantly higher in Group-B compared to Group-A ($P<0.001$). Regarding adverse effects, 2 patients in group-A and 1 patient in Group-B developed bradycardia in first month follow up, difference was not significant ($p=0.606$). No discontinuation was required. **Conclusion:** Combined propranolol and intralesional Triamcinolone is more effective compared to propranolol alone in the treatment of IHs. **Keywords:** Infantile haemangioma, Triamcinolone, Propranolol.

INTRODUCTION

Haemangiomas are the most common benign soft tissue tumor of infancy and childhood, occurring in 12% of all infants and are found in greater frequency in girls, whites, premature infants, twins and are usually born to mothers of higher maternal age. They occur most frequently in head and neck region (60%), followed by the trunk (25%) and the extremities (15%), which are grouped into Infantile Haemangiomas (ihs) and Congenital Haemangiomas (chs) 0 [1]. Presence of a bright red mass, that too in locations of obvious visibility in infants is horrifying and a source of concern to parents. In the 19th century, Virchow first labeled the IH 'angioma simplex', a lesion that has been historically referred to as 'capillary haemangioma' and 'strawberry haemangioma'. The etiology of these haemangiomas is still unclear with the involvement of angiogenic and vasculogenic factors [2]. Ihs are not fully developed at birth and appear as a pin head lesion at around 2-3 weeks of life [1]. Most ihs have a characteristic dynamic natural history of rapid growth during the first 3 to 12 months of age, followed by slow and spontaneous involution from 3 to 7 years of age. There is often

continued gradual regression of the color and bulk of the tumor until 10 to 12 years of age [3]. The proliferation and involution phases of the tumor are controlled by multiple regulators that include molecular, cellular and hormonal changes [4]. However, spontaneous regression is no guarantee of a satisfactory cosmetic result [5]. Approximately, 30% of ihs result in pain, bleeding, ulceration, infection, or functional impairment with vision, feeding, or breathing necessitating medical or surgical treatment. Larger and/ or multiple cutaneous ihs may be associated with high-output cardiac failure, cosmetic disfigurement and psychological morbidity in both child and the family [6]. Nevertheless, some haemangiomas can impair vital functions or cause morbidity and mortality [5].Ihs are regarded as problematic haemangiomas when they have massive growth, bleeding, ulceration, cause disfigurement or impair normal function or cosmetic development. Complication rates and need for treatment varied according to location of ihs. Common locations for problematic IH include face, ear, orbit, and airway and anogenital region. These haemangiomas subsequently require early and aggressive treatment for ideal functional and cosmetic outcomes [7]. Therefore, haemangiomas often require systemic, surgical and or laser treatment to avoid these adverse effects. Until recently, the mainstay of treatment for Infantile haemangiomas has been corticosteroids in various forms, including topical, intralesional and oral formulations, with the most common being oral prednisolone [8]. Recent study revealed intralesional injection of Triamcinolone acetonide in periorbital Infantile haemangioma was an effective and safe method of treatment with minimal adverse effects eg. Temporary subcutaneous atrophy [9]. Unlike oral prednisolon, intralesional Triamcinolone acetonide is devoid of systemic side effects like impaired growth, weight gain, cushingoid facies, hypertension etc[9]. Prospective data on corticosteroid therapy are lacking, and no consensus exists regarding the optimal treatment regimen and response rate [8,7]. Effectiveness, defined as stabilization or decrease in size, has been reported in up to 75% of cases with doses of 2–3 mg/kg/day, but optimal dose and regimen for tapering remain unknown [8]. The mechanism of action of steroids is not clearly understood. Edgerton has shown that steroids tend to sensitize the vascular bed to vasoconstricting agents and it has been seen that the effect of intralesional Triamcinolone was more on haemangiomas with finer vessels as Infantile haemangiomas[10].Other therapeutic modalities for complicated haemangiomas include interferon and vincristine [11,12]. A significant risk of neurologic and hematologic toxicity is associated with these modalities, which has limited their use [12]. However, all these options have potential side effects or unknown long-term safety. Propranolol hydrochloride (a nonselective β -blocker) has been introduced as a novel pharmacologic agent for the treatment of infantilehaemangiomas[13-16].Propranolol's presumed mechanisms of action on haemangiomas are vasoconstriction by decreasing the release of nitric oxide, inhibition of proangiogenic signals such as vascular endothelial growth factor, basic fibroblast growth factor, and matrix metalloproteinase, and induction of apoptosis in proliferating endothelial cells [17]. In different case series, it has been observed that, propranolol hydrochloride produce dramatic involution [18,19]. It is more cost-effective and resulted in fewer surgical interventions and demonstrated better tolerance, with rare side effects such as bradycardia, hypoglycemia, hypotension, rash, wheezing, somnolence etc. Propranolol appears superior to oral prednisolone in inducing more-rapid and greater clinical improvement in treating IH [20]. Early commencement of propranolol prevents significant tissue loss in life threatening large ihs which offers ease to later reconstructive surgery [14]. It may also be effective as an adjunctive measurement to other treatment modalities.Although attractive in concept, laser therapy is not often beneficial for ihs. Additionally carries risk of scarring, hypopigmentation and ulceration. Indication for resection of IH vary with patient's age. After complete involution, cosmetic distortion often becomes the primary indication for excision [21]. So, the aim of tihs combined therapy is to get the synergistic effects of two different mechanisms of action with lessening the side effects of both drugs [4].The proposal of this study is to assess the use of oral propranolol versus combined oral propranolol with intralesional Triamcinolone in treating Infantile haemangiomas.

OBJECTIVES

General objective

- To observe the effectiveness of oral propranolol and in combination with intralesional Triamcinolone acetonide therapy in infantile haemangioma.

Specific Objectives

- To observe the treatment outcome of propranolol by response of size and color regression of IH.
- To observe the treatment outcome of combined oral propranolol and intralesional Triamcinolone by response of size and color regression.
- To assess side effects and complication of propranolol therapy.

- To assess side effects and complication of combined propranolol and intralesional Triamcinolone therapy.
- To record the treatment cost of both treatment modalities.

MATERIALS AND METHODS

This was a prospective comparative study. The patients were selected non probability convenient consecutive sampling method. A total of 42 patients were included in this study- group A and group B. Group A patients received oral Propranolol with a follow-up period of 6 months and group B patients were received combined intralesional injection of Triamcinolone acetonide with oral propranolol with a follow-up period of 6 months. The study was conducted in the Department of Paediatric Surgery, Sylhet MAG Osmani Medical College Hospital, Sylhet, Bangladesh. At January 2018 to December 2019.

Inclusion criteria

- All patients who are clinically diagnosed as infantile haemangioma with indication for treatment.
- Age: <12 years of either sex.

Exclusion criteria

- Infantile haemangioma with
- Cardiac arrhythmia,
- Asthma,
- History of hypoglycemia,
- Diabetes mellitus,
- Hypertension,
- Hypotension,
- Liver failure,
- Renal failure,
- Family History with regard to atopy, or recent/repeated outbreak of wheezing.
- Haemangiomas in unapproachable area (eg. Intraoral, retroorbital etc).
- Uncomplicated small IH of trunk and extremities.
- Treatment failure cases.
- Congenital haemangiomas and vascular malformations.

Procedure of data collection

Informed written consent was obtained from the attendants after full explanation of the details of the disease process (Appendix-I). A proper diagnostic work up was made by taking detail IH history, clinical examination and investigations. The inclusion and exclusion criteria were applied. Those who fulfilled the inclusion criteria were taken as sample. Thus 42 patients with infantile haemangioma were selected. Each lesion was evaluated clinically for size, color (red, purple, blue, normal skin), overlying temperature and consistency. The diameter in two axes perpendicular to each other were measured and the maximum diameter was considered as size of the lesion. According to the size of the tumor, they were classified into three categories: small (<3 cm), medium (>3 cm and <8 cm), and large (>8 cm). The lesion was photographed with and without flash with a standard 5-megapixel digital camera at 30-cm distance. Electrocardiographic (ECG) evaluation was done to rule out treatment contraindications in suspicious cases. Echocardiography was done in case of unusual ECG findings. Ultrasonography was done to distinguish IH from other vascular malformations in clinically confusing cases. Bleeding Time and Clotting Time were done.

Data analysis

All the collected data were compiled and analyzed using the SPSS (Statistical package for social science) 22 for windows.

Quantitative data were analyzed by mean and standard deviation and comparison was done by unpaired t test or Mann-Whitney U test. Qualitative data were expressed as frequency and percentage and comparison was carried by Chi-square (χ^2) Test or Fisher's Exact test. A probability value (p) of less than 0.05 was considered as statistical significance.

Ethical issues

Informed written consent was taken from each of the parents either mother or father. The consent form clearly described the purpose and methods of the study, confidentiality of the interviews, risks and benefits of participating in the study; and IHs/her right to refuse participation or withdraw consent at any time without prejudicing IHs/her offspring's further treatment. An approval of the study protocol was obtained from the Institutional Ethics Committee of Sylhet M.A.G Osmani Medical College, Sylhet prior to the commencement of the study. All information was collected confidentially with complete respect to the parent's wish and without any force or pressure.

RESULTS

Table 1: Distribution of patients by age (N=42)

Age	Study subjects		p-value
	Group-A (n=21)	Group-B (n=21)	
1 to 6 months	7(33.3)	2(9.5)	*p=0.202
7 to 12 months	10(47.7)	13(61.9)	
>12 month	4(19.0)	6(28.6)	
Median	10.0	10.5	†p=0.457

Table 1 showed parenthesis denote corresponding percentage. Group-A: oral propranolol and Group-B: combined oral propranolol and intralesional Triamcinolone. The median age of the patients of Group-A was 10.0 months (Range, 1-132 months) and Group-B was 10.5 months (Range, 1-133 months); the difference was not statistically significant ($z=0.744$; $p=0.457$). Table-1 demonstrated that majority of patients were in the age group of 7 to 12 months [10 (47.6%) in group A and 13 (61.9%) in Group-B] and difference between two groups was not significant ($p=0.202$).

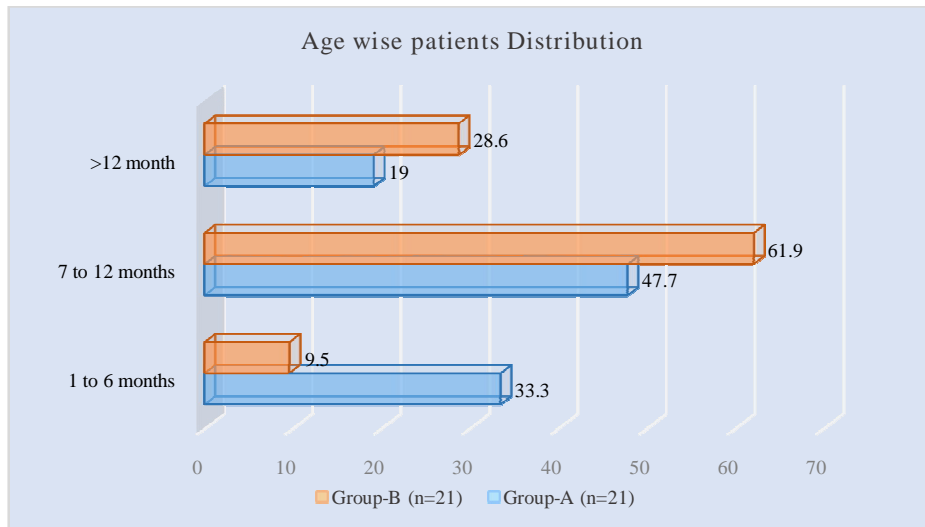


Figure I: Bar chart showed distribution of the patients by age in two group (N=42)

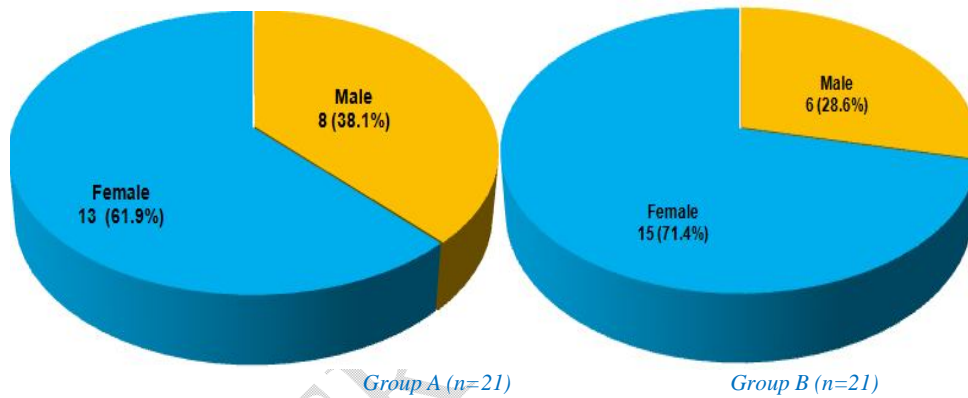


Figure II: pie chart showed distribution of patients by sex in tow group (N=42)

FigureII showed majorities of the patients in the both groups were female (61.9% versus 71.4%) while, 38.1% of patients in Group-A and 28.6% of patients in Group-B were male. There was no significant difference of sex between the groups ($\chi^2=0.429$; $p=0.744$).

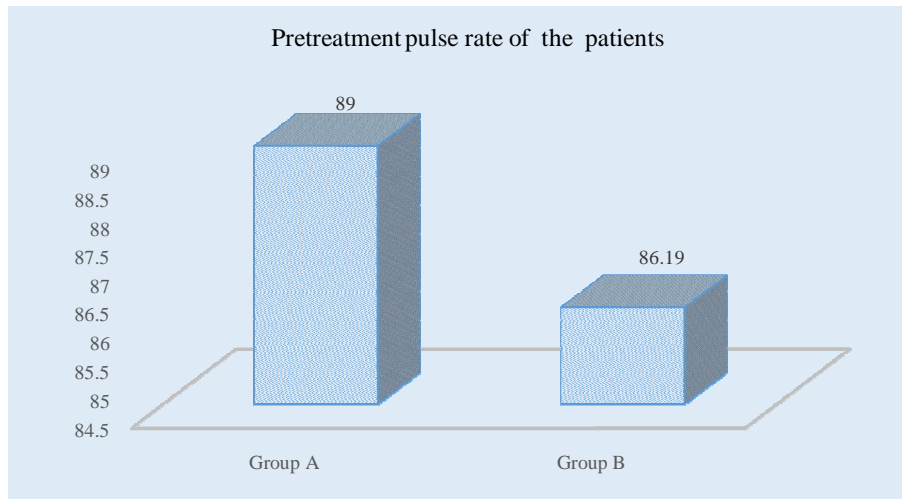


Figure III: Column chart showed distribution of patients by pretreatment pulse rate (N=42)

Figure III showed depicts that, in group-A (Propranolol treated group) mean pulse rate was 89.00 ± 8.63 beats/minute. In Group-B (Propranolol plus Triamcinolone treated group) mean pulse rate was 86.19 ± 7.45 beats/minute. Pretreatment pulse rate did not differ significantly between group-A and Group-B ($t=1.129$; $*p=0.265$).

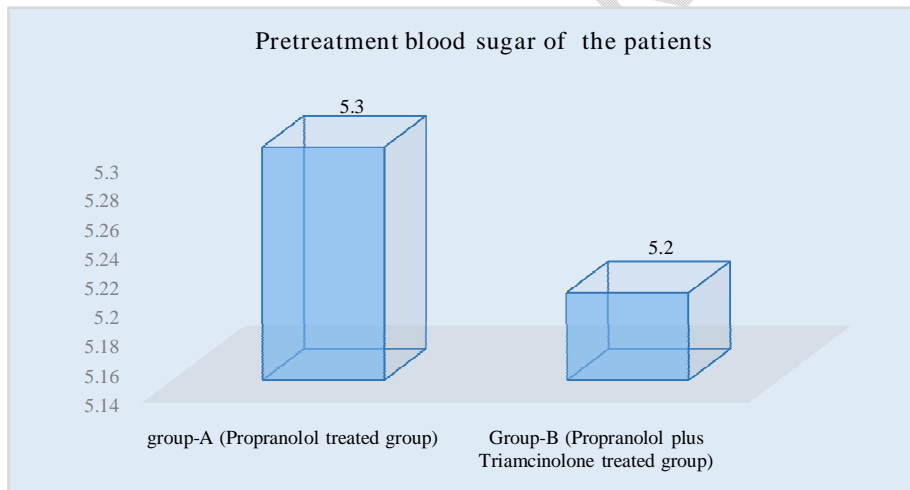


Figure IV: Column chart showed distribution of patients by pretreatment blood sugar (N=42)

Figure IV showed group-A (Propranolol treated group) mean pretreatment blood sugar (mmol/dl) was 5.30 ± 0.84 . In Group-B (Propranolol plus Triamcinolone treated group) mean pretreatment blood sugar (mmol/dl) was 5.20 ± 0.58 . Pretreatment blood sugar did not differ significantly between group-A and Group-B ($t=0.610$; $p=0.454$). Unpaired t test was applied

Table 2: Distribution of patients by Site of IH (N=42)

Site of IH	Study subjects		*p-value
	Group-A (n=21)	Group-B (n=21)	
Head and Neck	10 (47.6)	12 (57.1)	
Trunk	6 (28.6)	4 (19.0)	†p=0.809
Extremity	4 (19.0)	3 (14.3)	
Others	1 (4.8)	2 (9.5)	

Table 2 showed site of IH was more common in head and neck region, 47.6% and 57.1% respectively in group-A and Group-B; There was no significant difference between two groups (p=0.809).

Follow up	Study subjects	p-value
-----------	----------------	---------

Table 3:
Distribution of patients by

type of IH (N=42)

Type of IH	Study subjects		p-value
	Group-A (n=21)	Group-B (n=21)	
Superficial	1 (4.8)	3 (14.3)	p=0.451
Deep	3 (14.3)	1 (4.8)	
Mixed	17 (81.0)	17 (81.0)	

Table 3 showed mixed type of IH was the commonest in both groups, 17 (81.0%) and 17 (81.0%) respectively in group-A and Group-B; There was no significant difference between two groups (p=0.451).

Table 4: Distribution of patients by pretreatment complications (N=42)

Pretreatment Complications	Study subjects		p-value
	Group-A (n=21)	Group-B (n=21)	
Ulceration	4 (19.0)	0 (0.0)	p=0.132
Bleeding	3 (14.3)	1 (4.8)	
Ulceration + Bleeding	2 (9.5)	2 (9.5)	
No complication	12 (57.1)	18 (85.7)	

Table 4 showed parenthesis denote corresponding percentage. Nine (38.9%) of group A and 3 (14.3%) of group B presented with bleeding and or ulceration. Majority of patients had no pretreatment complications (Table 4). here observed no difference in presence or absence of pretreatment complication (p=0.132).

Table 5: Distribution of patients by Pretreatment Size of IH (N=42)

Pretreatment Size of IH	Study subjects		p-value
	Group-A (n=21)	Group-B (n=21)	
Mean \pm SD	5.76 \pm 2.53	4.79 \pm 2.70	p=0.234
Small	2 (9.5)	8 (38.1)	p=0.094
Medium	15 (71.4)	11 (52.4)	
Large	4 (19.0)	2 (9.5)	

Table 5 showed parenthesis denote corresponding percentage. SD=standard deviation The mean Size of IH was 5.76 \pm 2.53 cm in group-A and was 4.79 \pm 2.70 cm in Group-B; difference was not significant (t=1.208; p=0.234). Medium size of IH was more frequent types in both groups (71.4% and 52.4% respectively) and the difference was not significant (p=0.094).

	Group-A (n=21)	Group-B (n=21)	
At 1 month			
Size (Mean ± SD)	5.67 ± 2.42	4.69 ± 2.68	*p=0.222
Color fading (Mean ± SD)	3.76 ± 0.62	4.24 ± 0.77	*p=0.033
Complications			
Bradycardia	2 (9.5)	1 (4.8)	†P=0.606
No complication	19 (90.1)	20 (95.2)	
At 2 month			
Size (Mean ± SD)	4.69 ± 2.18	3.90 ± 2.65	*p=0.301
Color fading (Mean ± SD)	3.76 ± 0.62	4.24 ± 0.77	*p=0.033
Complications			
Bradycardia	1 (4.8)	0 (0.0)	†p=1.000
No complication	20 (95.2)	21 (100.0)	
At 3 month			
Size (Mean ± SD)	3.90 ± 2.27	3.10 ± 2.57	*p=0.286
Color fading (Mean ± SD)	5.33 ± 0.97	5.76 ± 0.89	*p=0.143
Complication	0 (0.0)	0 (0.0)	
At 4.5 month			
Size (Mean ± SD)	3.24 ± 2.40	2.36 ± 1.55	*p=0.256
Color fading (Mean ± SD)	6.57 ± 1.57	8.05 ± 1.56	*p=0.004
Complication	0 (0.0)	0 (0.0)	
At 6 month			
Size (Mean ± SD)	2.50 ± 1.59	1.56 ± 1.50	*p=0.256
Color fading (Mean ± SD)	6.57 ± 1.57	8.10 ± 1.58	*p=0.003
Complication	0 (0.0)	0 (0.0)	

Table 6: Distribution of patients by follow up:

Table 6 showed group-A: oral propranolol alone and Group-B: combined oral propranolol and intralesional Triamcinolone

At 1 month

The mean Size of IH was 5.67 ± 2.42 cm in group-A and was 4.69 ± 2.68 cm in Group-B; difference was not significant ($t=1.241$; $p=0.222$). The mean color fading of IH was 3.76 ± 0.62 in group-A and was 4.24 ± 0.77 in Group-B; color fading was significantly more in Group-B compared to group-A ($t=-2.203$; $p=0.033$). Majority of patient of Group A and Group B (90.1% and 95.2%) did not show any complication, while 9.5% in Group A and 4.8% in Group B developed bradycardia. Side effects were almost similar in both groups ($p=0.606$).

At 2 months

The mean Size of IH was 4.69 ± 2.18 cm in group-A and 3.90 ± 2.65 cm in Group-B; difference in size was not significant ($t=1.048$; $p=0.301$). The mean color fading of IH was 3.76 ± 0.62 in group-A and was 4.24 ± 0.77 in Group-B; color fading was significantly more in Group-B compared to group-A ($t=-2.203$; $p=0.033$). Complication was observed in either treatment group except a single patient (4.8%) in Group A exhibit bradycardia. Side effects were almost similar in both groups ($p=1.000$).

At 3 months

The mean Size of IH was 3.90 ± 2.27 cm in group-A and 3.10 ± 2.57 cm in Group-B; difference was not significant ($t=1.082$; $p=0.286$). The mean color fading of IH was 5.33 ± 0.97 in group-A and was 5.76 ± 0.89 in Group-B; color fading was significantly more in Group-B compared to group-A ($t=-1.496$; $p=0.143$). None of the patients in either group showed any sign of complication.

At 5 months

The mean Size of IH was 3.24 ± 2.40 cm in group-A and 2.36 ± 1.55 cm in Group-B; difference was not significant ($t=1.153$; $p=0.256$). The mean color fading of IH was 6.57 ± 1.57 in group-A and was 8.05 ± 1.56 in Group-B; color fading was significantly more in Group-B compared to group-A ($t=-3.055$; $p=0.004$). None of the patients developed any side effects or complications in either group.

At 6 months

The mean Size of IH was 3.24 ± 2.40 cm in group-A and was 2.36 ± 1.55 cm in Group-B; difference was not significant ($t=1.151$; $p=0.256$). The mean color fading of IH was 6.57 ± 1.57 in group-A and was 8.05 ± 1.56 in Group-B; color fading was significantly more in Group-B compared to group-A ($t=-3.139$; $p=0.003$). None of the patients developed any complications in either group.

Table 7: Distribution of patients by regression of size of IH (N=42)

Regression of size	Study subjects		p-value
	Group-A (n=21)	Group-B (n=21)	
Excellent	8 (38.1)	15 (71.4)	*p=0.080
Good	8 (38.1)	5 (23.8)	
Fair	0 (0.0)	0 (0.0)	
Poor	5 (23.8)	1 (4.8)	
Total	21 (100.0)	21 (100.0)	

Table 7 showed regression in the size of IHS was clinically assessed. It was evaluated according to 0%-to-100% scale. An excellent response denotes 75% to 100% regression. A good response denotes 50% to 75% regression. A fair response denotes 25% to 50% regression. Finally, a poor response denotes 25% or less regression. Excellent response was much more in Group-B but did not reach the level of significance ($p=0.080$).

Table 8: Distribution of patients by color regression of IH (N=42)

Color regression	Study subjects		p-value
	Group-A (n=21)	Group-B (n=21)	
Excellent	2 (9.5)	19 (90.5)	*p<0.001
Good	17 (81.0)	1 (4.8)	
Fair	0 (0.0)	0 (0.0)	
Poor	2 (9.5)	1 (4.8)	
Total	21 (100.0)	21 (100.0)	

Table 8 showed regression in the color of IHS was clinically assessed. It was evaluated according to 0%-to-100% scale. An excellent response denotes 75% to 100% regression. A good response denotes 50% to 75% regression. A fair response denotes 25% to 50% regression. Finally, a poor response denotes 25% or less regression. Excellent color regression was significantly more in Group-B compared to group-A ($p<0.001$).

Table 9: Distribution of patients by response of IH (N=42)

Outcome of IH	Study subjects		p-value
	Group-A (n=21)	Group-B (n=21)	

Regression	16 (76.2)	20 (95.2)	*p=0.107
Stabilization	4 (19.0)	0 (0.0)	
Failure	1 (4.8)	1 (4.8)	
Recurrence	0 (00)	0 (00)	
Total	21 (100.0)	21 (100.0)	

Table 9 showed regression in group-A 16 (76.2%) patients and in Group-B 16 (76.2%) patients had regression in size. Regression in size of IH was much more in Group-B but did not reach the level of significance (p=0.107).




Figure V: Column chart showed comparison of treatment cost between two groups (N=42)

Figure V showed group-A (Propranolol treated group) average treatment cost was 124.76 ± 30.88 Taka per patient. In Group-B (Propranolol plus Triamcinolone treated group) average treatment cost was 187.86 ± 39.70 Taka per patient. Treatment cost was significantly higher in Group-B compared to Group-A ($t=-5.806$; $P<0.001$, analyzed by unpaired t test).

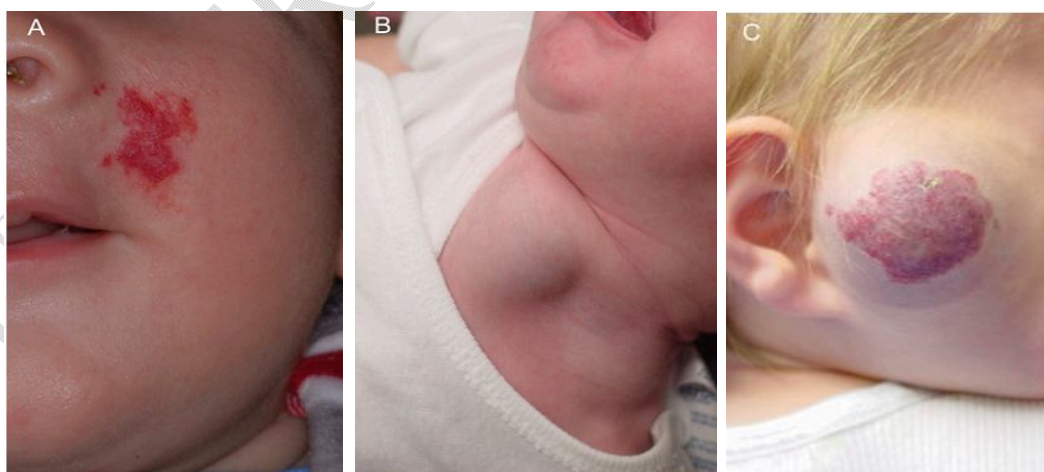


Figure VI showed Cutaneous IH may be classified on the basis of their depth. A, Superficial IHs are visible only at the skin surface and may be focal (as shown) or segmental. B, Deep IHs have no surface involvement. C, Mixed, or compound, IHs have both superficial and deep components

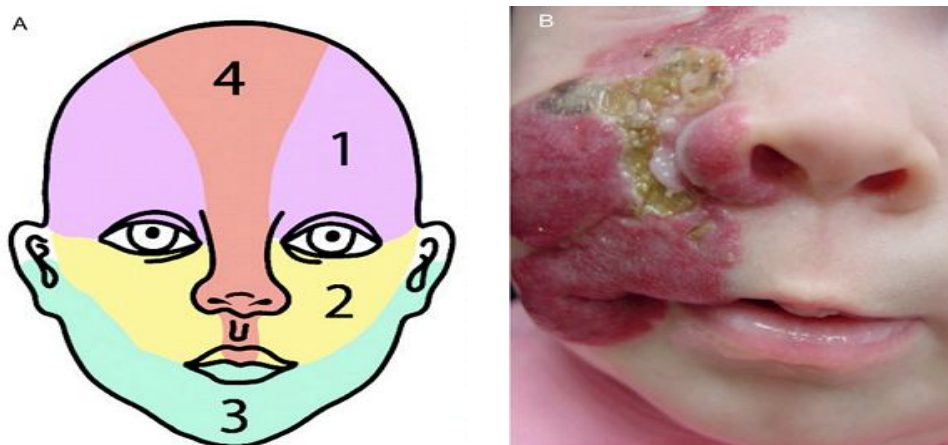


Figure VII: Segmental IH of the face (A) Patterns of segmental IH of the face extracted from image analysis defined. Seg1 (frontotemporal), Seg2 (maxillary), Seg3 (mandibular), and Seg4 (frontonasal). (B) An ulcerated segmental IH in the maxillary distribution

DISCUSSION

Infantile haemangiomas (IHs) are the most common soft tissue tumors of infancy, occurring in 4% to 10% of children under 1 year of age [12]. The exact frequency of a precursor lesion at birth has not been well studied, because the average age of presentation to a specialist for evaluation ranges from 3 to 5 months of age [22]. However, a retrospective photograph review showed 65% of patients with a precursor lesion shortly after birth [23], and another study noted 48% of patients had precursor lesions at the time of birth [24]. There is a rapid proliferation phase of infantile haemangiomas, with recent evidence suggesting that 80% of the growth occurs in the first 3 months of life, and an accelerated growth period may occur between 5.5 and 7.5 weeks of age [22,23]. This is followed by a slower growth phase until 6–9 months of age, with years of involution. The established belief is that involution of infantile haemangiomas occurs at about 10% per year, so by the age of 5 years, each lesion would demonstrate 50% resolution [25]. Although most infantile haemangiomas are usually not problematic, up to 12% can cause significant morbidity, including disfigurement, difficulty in feeding, ulceration, vision loss, airway compromise, congestive heart failure, and death. The more complex, challenging infantile haemangiomas are those that warrant referral to a specialist for consideration of treatment, which often includes systemic pharmacotherapy. Unfortunately, even when the infantile haemangiomas do not cause significant morbidity, there is a high rate of scarring or residual lesions, especially when these are not treated [25]. One study showed that when left untreated, infected, ulcerated, or bleeding, infantile haemangiomas produced a scar 97% of the time [24]. Systemic corticosteroids were considered as the mainstay therapy of IH before the introduction of beta-blockers in recent years. Due to potential adverse effects of systemic corticosteroids, many have turned to local injections of a corticosteroid. There are several protocols, however, injecting a maximum of 1–5 ml depending on the size and number of lesions of Triamcinolone 40 mg/ml with or without betamethasone 4 mg/ml has been widely suggested [26]. The effect of systemic beta-blockers such as propranolol in the treatment of haemangioma was first noted in 2008 when two children showed a rapid regression of haemangiomas after receiving propranolol for cardiopulmonary indications [13]. Oral propranolol has been associated with dramatic improvement of IPH lesions in young children [27,28]. Early effects of propranolol on haemangiomas are evidenced by shrinkage in the size and reduction of the surface redness due to a decrease in nitric oxide and subsequent vasoconstriction. Intermediate effects are a reduction in and blockage of proangiogenic factors and finally, after long time usage, it induces apoptosis in proliferating phase. Possible side effects of propranolol are bradycardia, hypotension, and bronchial hyperactivity especially in patients with reactive airways, hypoglycemia, hyperkalemia, sleep disorder, and gastrointestinal disturbance [26]. For the best results and the least side effects, patients have been treated initially with a low dosage of oral propranolol 0.5 mg/kg/day, divided three times daily while hospitalized under Paediatric specialist supervision. After toleration of two doses, the amount is doubled toward maximum dosage. Patients can be discharged after 2–3 days, and their medication is continued orally at home for several months [1]. In this study the median age of the patients was 10.0 months (Range, 1-132 months) in propranolol alone treated group and was 10.5 months (Range, 1-133 months) in combined propranolol and intralesional Triamcinolone treated group; the difference was not statistically significant

($p=0.457$). Wu et al., (2018) [29] found that the mean age of IHs at initiation of the treatment was 5.8 months. Manunza et al., (2010) [20] briefly described their experience with propranolol in 30 infants with haemangioma between July 2008 and April 2009, the average patient's age at the start of therapy was 5.8 month (range 1.2-13.5 month). More et al., (2018) found that the average age of patient at the start of therapy was 8.8months. This was somewhat lower than the results of the present study. According to Bennet et al., (2008) [30] most infantile haemangiomas (IHs) complete their proliferative growth phase before 9 months of age and they identified 29.6% of patients of IHs show prolonged growth after 9 months of age. In Hogeling et al., (2011) [19] infantile haemangiomas (IHs) complete their proliferative growth phase before 6 months and this age group constituted 52.45% of their patients. Natural historical feature of IH is rapid growth during 1st 6 months of life as a consequence age group is similar to this study. This may be due to ignorance of the parents of the children about the treatment of IHs and this may delay to attend the study place to take treatment. This study also demonstrated that majority of patients were in the age group of 7 to 12 months [10 (47.6%) in group A and 13 (61.9%) in Group-B] and difference between two groups was not significant ($p=0.202$). Saha et al., (2017) [6] found that 53% of children under Propranolol therapy were of 0-6 month age, 40% from age group 7-12 month and 7% of patients was of more than one year of age. This study showed that majorities of the patients in the both groups were female (61.9% versus 71.4%) while, 38.1% of patients in Group-A and 28.6% of patients in Group-B were male. There was no significant difference of sex between the groups ($p=0.744$). Wu et al., (2018) [29] found female preponderance of IHs with 82.7% female and 17.3% male. Female preponderance of infantile haemangioma was reported in several other studies [31,5,4]. In the present study the mean Size of IH was 5.76 ± 2.53 cm in group-A and was 4.79 ± 2.70 cm in Group-B; difference was not significant ($t=1.208$; $p=0.234$). Medium size of IH was more frequent types in both groups (71.4% and 52.4% respectively) and the difference was not significant ($p=0.094$). Alsmman and Mounir, (2017) [4] found that 54.5% of IHs were small size, 39.4% were medium size and only 9.1% were large size IHs. In the current study the site of IH was more common in head and neck region, 47.6% and 57.1% respectively in group-A and Group-B; trunk was involved in 28.6% and 19.0% % respectively; extremities were involved in 19.0% and 14.3% respectively; and other region in 4.8% and 9.5% respectively in group-A and Group-B. There was no significant difference between two groups ($p=0.809$). Head and neck regions were cosmetically very much important site. Price et al., (2011) [5] found that 78% of IHs were located on the head and neck (59% on the face and 19% on the scalp), the rest were distributed on the trunk (7%), extremities (10%), and genitalia (5%). Pandey et al., (2009) [32] found that in most of cases lesion were in head and face region (64.9%). According to Sans et al., (2009) [33] and Smithers and Fishman, (2010) [34] most of the lesions were in the head and face region 60% and 63% respectively. So sites of the infantile haemangiomas are similar in all these studies. Small lesions in trunk and limbs usually failed to draw attention, in our study they mostly presented due to their extensive nature or complications. In the present study the type of IH was mixed types in both groups, 17 (81.0%) and 17 (81.0%) respectively in group-A and Group-B; There was no significant difference between two groups ($p=0.451$). Samuelov et al., (2018) [35] found that superficial lesions were noted in 47% of patients. The remaining 53% had a deep component as an isolated finding or in combination with a superficial component. There were 9 (38.9%) patients presented with some complications (ulceration bleeding or combined) in group-A and were 3 (14.3%) patients presented with some complications in Group-B. There was no significant difference of complication at presentation between two groups ($p=0.132$). Bleeding was self-limiting in all cases but the ulcerations necessitated topical treatment and healed with topical antibiotics. After healing of ulcer intralesional Triamcinolone were injected in patient with group B. House et al., (2014) [36] found three patients of IHs came with bleeding and five presented with ulceration and infection during initiation of treatment. Among them 5 received propranolol. Bleeding episode did not occur in any case after starting treatment with propranolol and all 3 cases with ulcer were healed within one month. But in prednisolone group bleeding was controlled by surgical dressing and pressure bandage. Regarding regression of tumor (IHs) it is very important to measure the percentage of regression. Many studies used VAS scoring to assess the tumor regression which is subjective evaluation. But some centre used direct measurement by soft flexible measuring tape and calipers [37,5]. In the present study 38.1% patients had an excellent response, 23.8% patients had a good and 4.8% patient had poor response in Group-A. Whereas 71.4% of patients had an excellent response, 38.1% patients had a good and 23.8% patients had poor response in Group-B. Excellent response was much more in Group-B but did not reach the level of significance ($p=0.080$). A multicentre retrospective comparative study by Price et al., (2011) [5] showed duration of treatment 2-7 month and 85.3% of the patients receiving propranolol got regression $>75\%$. A Randomized Controlled Trial of Propranolol for Infantile Haemangiomas by Bertrand et al., (2011) showed similar result. All these results significantly proved that tumor regression clearly more satisfactory by propranolol. Saha et al., (2017) [6] reported that excellent responder was of (33%) and they were graded as six, poor responder was 10%, very poor responder in 7% and

non responder in 7% of patients in propranolol treated group. In this study 14.3% patients had an excellent color regression, 76.2% patients had a good color regression and 9.5% patients had poor color regression in Group-A. Whereas 90.5% patients had an excellent color regression, 4.8% patient had a good color regression and 4.8% patient had poor color regression. Excellent color regression was significantly more in Group-B compared to group-A ($p < 0.001$). Bertrand et al., (2011) [37] showed excellent 80% in propranolol recipient. Actually color clearance is a significant cosmetically important in the treatment outcome of IHs. So it is certainly clear that combined propranolol and intralesional Triamcinolone is superior to propranolol alone. In the present study 16 (76.2%) patients had regression in size of IH, 4 (19.0%) patients remain static and 1 (4.8%) deteriorate or failure in Group-A. Whereas 16 (76.2%) patients had regression in size and 1 (4.8%) deteriorate or failure in Group-B. Regression in size of IH was much more in Group-B but did not reach the level of significance ($p = 0.107$). Alsmman and Mounir, (2017) [4] found that regression of the tumor occurred in 28 patients (85%), stabilization occurred in three of them (9%), and failure in two (6%), which necessitated repeated intralesional injection of Triamcinolone but with minimal response. As bradycardia is potentially common after ingestion of propranolol, in this study every patient was monitored for this effect. The side effects were bradycardia in 9.5% of cases in group-A ($p = 0.606$), whereas 4.8% patients developed bradycardia in Group-B at first month of follow up. In subsequent follow up at second month only 4.8% of cases in group-A had bradycardia and no patients had bradycardia after that. Alsmman and Mounir, (2017) [4] found that there were no recorded cases of hypotension, bradycardia, or hypoglycemia during the course of oral propranolol treatment.

Limitations of the study

This study was not without limitations. The limitations of the study were

Small sample size due to time constraints.

Some guardians were impatient to take treatment of long duration, so it was challenging to counsel them.

Follow up period was short.

Study was conducted in a single tertiary hospital only and multicenter study was not possible.

Recommendations

Based on the findings of the study following recommendation can be made regarding better care for infantile haemangioma.

Combined propranolol and intralesional Triamcinolone therapy is one of the choice of treatment in infantile haemangioma.

However further studies involving multicenter, large sample and long term follow up should be conducted to compare combined propranolol and intralesional Triamcinolone versus propranolol in infantile haemangioma for authentication of this protocol of treatment in infantile haemangioma.

Conclusion

This study showed that combined propranolol and intralesional Triamcinolone therapy was more effective in lesion clearance and color fading compared to oral propranolol alone in infantile haemangioma. Both treatment options were well tolerated with minimal adverse effects. Treatment cost was significantly higher in combined propranolol and intralesional Triamcinolone compared to propranolol alone. Therefore, based on the results of this study, it may be concluded that combined propranolol and intralesional Triamcinolone is more effective compared to oral propranolol in infantile haemangioma.

REFERENCES

1. George A, Mani V, Noufel A. 2014. Update on the classification of haemangioma. *Journal of Oral and Maxillofacial Pathology*, 18(1), 117-120.
2. Higgins EM, Glover MT. 2016. Dermatoses and Haemangiomas of Infancy. In: Griffiths CEM, Barker J, Bleiker T, Chalmers R, Creamer D, eds. *Rook's Textbook of Dermatology*. New Delhi: John Wiley & Sons, Ltd; p. 117.1

3. Coran AG, Adzick NS, Krummel TM, Laberge JM, Shamberger RC, Caldamone AA. 2011. Paediatric Surgery. Philadelphia: Elsevier Saunders, pp. 1613-1614.
4. Alsmann AH, Mounir A. 2017. Combined oral propranolol with intralesional injection of Triamcinolone acetonide in treatment of infantile periocular haemangiomas. *Clinical Ophthalmology*, 11, 2177–2181.
5. Price CJ, Lattouf C, Baum B, McLeod M, Schachner LA, Duarte AM, et al. 2011. Propranolol vs corticosteroids for infantile haemangiomas: a multicenter retrospective analysis. *Archives of Dermatology*, 147, 1371-1376.
6. Saha N, Talukder SA, Khan N. 2017. Propranolol Versus Corticosteroids for Infantile Haemangiomas: A Randomised Control Trial in a Tertiary Care Hospital. *Bangladesh Medical Research Council Bulletin*, 43, 44-50
7. Haggstrom AN, Drolet BA, Baselga E, Chamlin SL, Garzon MC, Horii KA, et al. 2006a. Prospective study of infantile haemangiomas: clinical characteristics predicting complications and treatment. *Paediatrics*, 118, 882-887.
8. Bennett ML, Fleischer AB Jr, Chamlin SL, Frieden IJ. 2001. Oral corticosteroid use is effective for cutaneous haemangiomas: An evidence-based evaluation. *Archives of Dermatology*, 137, 1208–1213.
9. Chowdhury TA, Bhuiyan AH, Hakim MM. 2014. Intralesional Dexamethason versus oral prednisolon in the treatment of infantile haemangioma. *Journal of Paediatric Surgeons of Bangladesh*, 5(1), 12-19.
10. Gangopadhyay AN, Sharma SP, Gopal SC, Gupta DK, Panjawani K, Sinha JK. 1995. Local steroid therapy in cutaneous haemangiomas. *Indian Journal of Surgery*, 33, 32-33.
11. Enjolras, O., Breviere, G. M., Roger, G., Tovi, M., Pellegrino, B., Varotti, E., ... & Leverger, G. (2004). Vincristine treatment for function-and life-threatening infantile hemangioma. *Archives de pediatrie: organe officiel de la Societe francaise de pediatrie*, 11(2), 99-107.
12. Frieden IJ, Haggstrom AN, Drolet BA, Mancini AJ, Friedlander SF, Boon L, et al. 2005. Infantile haemangiomas: current knowledge, future directions. Proceedings of a research workshop on infantile haemangiomas, April 7–9, 2005, Bethesda, Maryland, USA. *Paediatric Dermatology*, 22, 383–406.
13. Lèautè-Labrèze C, de la Roque ED, Hubiche T, Boralevi F, Thambo JB, Taïeb A. 2008. Propranolol for severe haemangiomas of infancy. *The New England Journal of Medicine*, 358(24), 2649-2651.
14. Theletsane T, Redfern A, Raynham O, Harris T, Prose NS, Khumalo NP. 2009. Life-threatening infantile haemangioma: a dramatic response to propranolol. *Journal of the European Academy of Dermatology and Venereology*, 23(12), 1465-1466.
15. Mazereeuw-Hautier J, Hoeger PH, Benlahrech S, Ammour A, Broue P, Vial J, et al. 2010. Efficacy of propranolol in hepatic infantile haemangiomas with diffuse neonatal haemangiomatosis. *The Journal of Paediatrics*, 157(2), 340-342.
16. Schiestl C, Neuhaus K, Zoller S, Subotic U, Forster-Kuebler I, Michels R, et al. 2011. Efficacy and safety of propranolol as first-line treatment for infantile haemangiomas. *European Journal of Paediatrics*, 170(4), 493-501
17. Storch CH, Hoeger PH. 2010. Propranolol for infantile haemangiomas: insights into the molecular mechanisms of action. *The British Journal of Dermatology*, 163(2), 269-274.
18. Buckmiller LM, Munson PD, Dyamenahalli U, Dai Y, Richter GT. 2010. Propranolol for infantile haemangiomas: early experience at a tertiary vascular anomalies center. *Laryngoscope*, 120, 676-681.
19. Hogeling M, Adams S, Wargon O. 2011. A randomized controlled trial of propranolol for infantile haemangiomas. *Paediatrics*, 128, e259-e266
20. Manunza F, Syed S, Laguda B, Linward J, Kennedy H, Gholam K, et al. 2010. Propranolol for complicated infantile haemangiomas: a case series of 30 infants. *The British Journal of Dermatology*, 162, 66–468.
21. Holcomb GW, Murphy PJ, Ostlie DJ. 2014. *Ashcraft's Paediatric Surgery*. China: Elsevier Saunders, 1007-10
22. Chang LC, Haggstrom AN, Drolet BA, Baselga E, Chamlin SL, Garzon MC, et al; Haemangioma Investigator Group. 2008. Growth characteristics of infantile haemangiomas: implications for management. *Paediatrics*, 122(2), 360–367.
23. Tollefson MM, Frieden IJ. 2012. Early growth of infantile haemangiomas: what parents' photographs tell us. *Paediatrics*, 130, e314–e320.
24. Bauland CG, Lüning TH, Smit JM, Zeebregts CJ, Spauwen PH. 2011. Untreated haemangiomas: growth pattern and residual lesions. *Plastic and Reconstructive Surgery*, 127(4), 1643–1648.
25. Ames JA, Sykes JM. 2015. Current trends in medical management of infantile haemangioma. *Curr Opin Otolaryngol Head Neck Surg*, 23(4):286–291

26. Tavakoli M, Yadegari S, Mosallaei M, Aletaha M, Salour H, Lee WW. 2017. Infantile Periocular Haemangioma. *Journal of Ophthalmic & Vision Research*, 12, 205-211.
27. Aletaha M, Salour H, Bagheri A, Raffati N, Amouhashemi N. 2012a. Oral propranolol for treatment of Paediatric capillary haemangiomas. *Journal of Ophthalmic & Vision Research*, 7, 130-133.
28. Aletaha M, Salour H, Bagheri A, Raffati N, Amouhashemi N. 2012b. Successful treatment of orbital haemangioma with propranolol in a 5-year-old girl. *Orbit*, 31, 18-20.
29. Wu, Haiwei & Wang, Xuan & Zhang, Ling & Zheng, Jia Wei & Liu, Chao & Yan, an. (2018). Topical Timolol Vs. Oral Propranolol for the Treatment of Superficial Infantile Hemangiomas. *Frontiers in Oncology*. 8. 10.3389/fonc.2018.00605.
30. Bennett ML, Fleischer AB Jr, Chamlin SL, Frieden IJ. 2008. Oral corticosteroid use is effective for cutaneous haemangiomas: an evidence-based evaluation. *Archives of Dermatology*, 137(9), 1208-1213
31. Zaher H, Rasheed H, Hegazy RA, Hegazy RA, Abdelhalim DM, et al. 2011. Oral propranolol: an effective, safe treatment for infantile haemangiomas. *European Journal of Dermatology*, 21(4), 558-63.
32. Pandey A, Gangopadhyay AN, Gopal SC, Kumara V, Sharma SP, Gupta DK, et al. 2009. Twenty years' experience of steroids in infantile haemangioma—a developing country's perspective. *Journal of Paediatric Surgery*, 44, 688-694.
33. Sans V, de la Roque ED, Berge J, Grenier N, Boralevi F, Mazereeuw-Hautier J, et al. 2009. Propranolol for severe infantile haemangiomas: follow-up report. *Paediatrics*, 124(3), e423-e431.
34. Smithers CJ, Fishman SJ. 2010. Vascular anomalies. In: Holcomb WG, Murphy PJ, eds. *Ashcraft's Paediatric Surgery*. 6th ed. Philadelphia: Saunders Elsevier; pp. 982-988.
35. Samuelov L, Kinori M, Rychlik K, Konanur M, Chamlin SL, Rahmani B, et al. 2018. Risk factors for ocular complications in periocular infantile haemangiomas. *Paediatric Dermatology*, 35(4), 458-462.
36. Haque MM, Ferdous KMN, Saha BK, Paul SK, Islam MK. 2014. Oral Propranolol and Prednisolone in the Treatment of Infantile Haemangioma: A Comparative Study. *Chattagram Maa-O-SIHshu Hospital Medical College Journal*, 13(1), 26-31.
37. Bertrand J, McCuaig C, Dubois J, Hatami A, Ondrejchak S, Powell J. 2011. Propranolol versus Prednisone in the Treatment of Infantile Haemangiomas: A Retrospective Comparative Study. *Paediatric Dermatology*, 28(6), 649-654.