Recurrent spontaneous pneumothorax revealing Marfan syndrome: A case report

Abstract

The present study reports about recurrent spontaneous pneumothorax revealing Marfan syndrome.Marfan syndrome is a rare autosomal dominant disease that affects connective tissue and affects several organs, including the lung. It appears at a variable age and can be unrefined. This is a case of patient aged 16 years, eldest of two siblings, without toxic habits, treated for pulmonary tuberculosis confirmed bacteriologically 2 years ago and operated on 5 years ago for a left inguino-scrotal hernia. The patient presented to the department on day 7 after discharge following spontaneous stabbing left chest pain associated with dyspnea at the slightest effort. On clinical examination, there was a syndrome of air effusion in the left hemithorax. The frontal chest X-ray revealed a large total left pneumothorax which was drained.Lung involvement rarely modifies the respiratory functional prognosis. The occurrence of a pneumothorax is rarely a mode of entry into the disease, hence the interest in discussing the diagnosis in cases of recurrent spontaneous pneumothorax or thoracic deformation.

Keywords: pneumothorax, chest X-ray, pulmonary tuberculosis, Marfan syndrome, aortic dilatation

UNDER PEER REVIEW

Introduction

Marfan syndrome is a rare autosomal dominant disease that affects connective tissue and affects several organs, including the lung[20-22]. It appears at a variable age and can be unrefined. The diagnosis is made on a combination of clinical, paraclinical and sometimes evolving arguments. The occurrence of a pneumothorax is rarely a mode of entry into the disease.

Case presentation

This is a patient aged 16 years, eldest of two siblings, without toxic habits, treated for pulmonary tuberculosis confirmed bacteriologically 2 years ago and operated on 5 years ago for a leftinguino-scrotal hernia . He was admitted for sudden, spontaneous stabbing left chest pain blocking inspiration without any notion of trauma. On admission, the patient desaturated to SpO2 = 90% on room air. He was tachycardic at 110 bpm and polypneic at 22 cycles/min with signs of respiratory struggle. Examination of the thorax revealed a moderate pectus excavatum (Figure 1A) as well as an air effusion syndrome at the level of the outer 1/3 of the left hemithorax.
On skeletal examination, the patient had a slender morphotype with a height of 1.86 m and a weight of 57 kg, so a BMI of 16.5 kg/m2. The wingspan/height ratio was 0.96 (<1.05), the thumb and wrist signs were positive (Figure 1C, 1D), the feet were flat (Figure 1B) and the

fingers were thin and long (arachnodactyly). He had a long, narrow face with enophthalmos, downward-facing eyelid fissures, and prognathism (Figure 1 E). A clinical picture in favor of Marfan syndrome.
The chest x-ray on admission (Figure 2A) revealed a large total left pneumothorax with some finely rimmed lumens, infiltrates on the right as well as a scoliotic attitude.

The patient received chest drainage at the level of the 5th left intercostal space on the middle axillary line with the lung returning to the wall after 5 days, then the drain was removed after a 48-hour clamping test without incident.
A chest CT and spirometry were scheduled remotely and the alpha-1-antitrypsin dosage was normal.
The patient presented to the department on day 7 after discharge following spontaneous stabbing left chest pain associated with dyspnea at the slightest effort. On clinical examination, there was a syndrome of air effusion in the left hemithorax. The frontal chest X-ray revealed a large total left pneumothorax which was drained.
The file was discussed for surgical talcage except that the patient had presented during the same hospitalization a contralateral pneumothorax which was also drained (Figure 2B,C) then he was transferred to the thoracic surgery department where he was operated on the left side by Wedge resection of the apex removing emphysema bubbles with a left pleurectomy under uniportal VATS. On pathological study, the lungs were emphysematous with chronic non-specific pachypleuritis without signs of malignancy.

The evolution 2 days after his discharge was marked by a recurrence of the right pneumothorax (Figure 2D) motivating a surgical revision on the right side using the same technique.

After stabilization of the patient, an assessment was requested to look for others suffering from Marfan syndrome.
Ophthalmological examination was normal in both eyes. On cardiac evaluation, the electrocardiogram was normal and the echocardiography showed a non-dilated, non-hypertrophied LV, the site of septal dyskinesia with an LVEF of 45-50%. The tricuspid valve was the site of minimal aortic insufficiency without stenosis. The mitral valve was normal, the right cavities not dilated. The ascending aorta was dilated (sinus = 41mm ST junction = 38mm ascending aorta = 40mm). The IVC was compliant and not dilated and the pericardium was dry. A chest CT angiogram (Figure 2E) was performed showing the sinus of valsalva dilated to 39mm, the sinotubal junction to 28mm, the arch of the aorta to 23mm and the descending aorta to 23mm. The z-score calculated using the Campens method was 3.78 (>2), and it was 2.83 (>2) using the Gautier method.
On the parenchymal scan sections (Figure 2F), we noted foci of central and peripheral bronchiectasis, a mosaic appearance as well as reticulo-micronodular infiltrates of fowlers.

According to the diagnostic criteria for Marfan syndrome revised in 2010 by Loeys et al, the patient had no known family history, the z-score for ascending aortic dilation was >2, and he had a systemic score to 9 (>7). The diagnosis was that of a bilateral and recurrent pneumothorax revealing classic Marfan syndrome.

UNDER PEER REVIEW

After consultation with the cardiologists, there was no urgency to start beta-blockers as a preventative measure, close cardiac monitoring was proposed. Annual ophthalmological monitoring is planned. Vitamin D supplementation as well as anti-flu, anti-pneumococcal and anti-covid19 vaccinations and physiotherapywere prescribed.

Figure1: Skeletal anomalies. A: Moderate pectus excavatum B: Flat feet C: Thumb sign D: Wrist sign E: Particular facial features

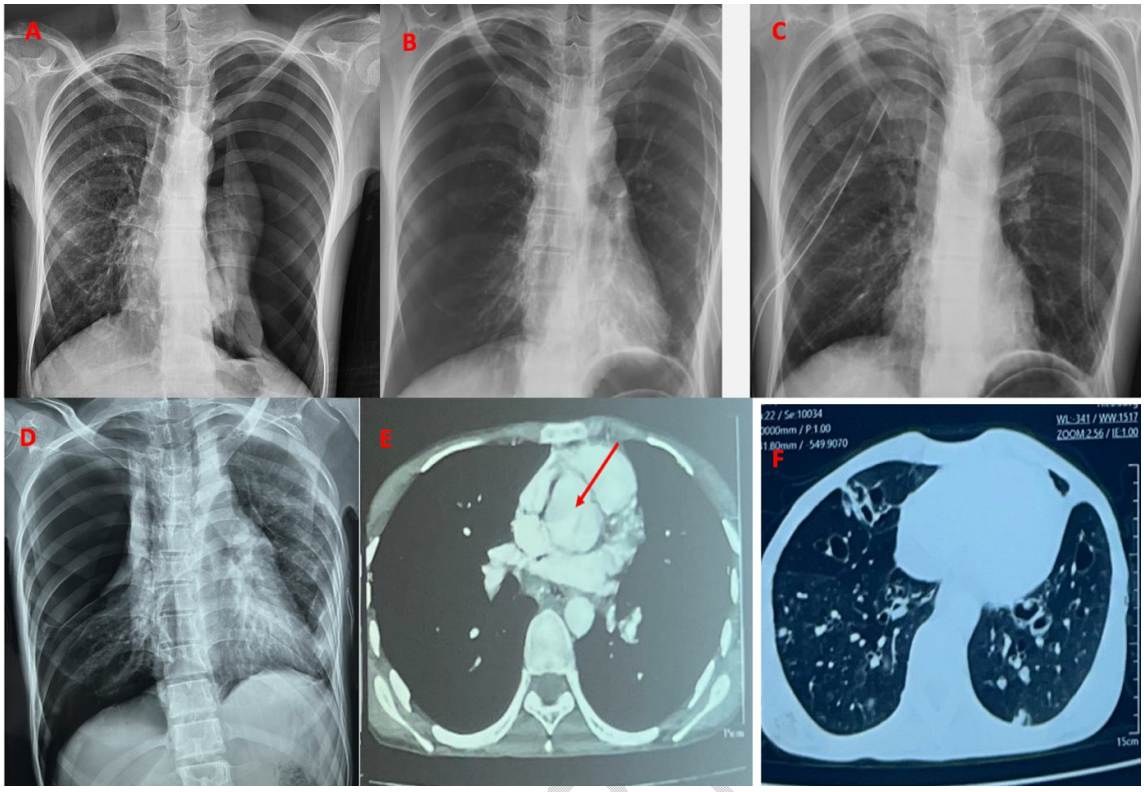

Figure2: Thoracic imaging. A: Chest x-ray showing a left pneumothorax B,C: Chest x-rays showing a drained bilateral pneumothorax D: Chest x-ray showing recurrence of the right pneumothorax E: Chest CT angiogram showing dilation of the ascending aorta F: Parenchymal CT section showing dilations of bronchi, mosaic appearance and micronodular infiltrates of fowlers

UNDER PEER

Discussion

Marfan syndrome is a rare autosomal dominant genetic disorder linked to mutation of the FBN1 gene encoding fibrillin. The vital prognosis is linked to the aortic damage and the functional prognosis depends on the ophthalmic and musculoskeletal damage.[1]

The prevalence is estimated between 1 and 3 people per 10,000. This prevalence remains underestimated given the variability of symptoms and the presence of de novo mutations in 25% of cases. The incidence does not reveal any gender preference or ethnic origin. Life expectancy has increased by 30 years and is getting closer to that of the non-sick population thanks to advances in diagnostic and monitoring means. [2],[3]

The syndrome was described in 1896 by the pediatrician Antonio-Bernard Jean Marfan. In 1914, Boerger added ectopia lens to the description. In 1931, Henricus Weve highlighted the autosomal dominant character. In 1938, Marfan published a memoir on 150 observations of dolichostenomelia, defining “Marfan syndrome.” [4]

The diagnostic criteria were first developed in 1986 “Berlin classification”. Then in 1996, these criteria were revised by De Paepe et al, proposing a new classification: The Ghent criteria. The latter were revised by Loeys et al in 2010 with two scenarios depending on the presence or absence of a family history of Marfan syndrome.[1]

Paraclinical investigations essential to the diagnosis include echocardiography, an ECG, imaging of the aorta by CT angiography or MRI, a complete ophthalmological examination, an X-ray of the entire spine and genetic study by searching for the FBN1 (Ch15) gene. Optional tests are a wrist x-ray to assess bone age and a lumbar MRI. [1]

The association of spontaneous pneumothorax and Marfan was studied through two series in 1984 [5]. The first included 100 patients where the frequency of pneumothorax was 11% and the second of 249 patients where the frequency was 4.4%, including 5 recurrences and 2 bilateral pneumothorax. More recently, the Mayo Clinic series included 166 cases where the frequency of pneumothorax was 4.8%. It was also noted that the incidence was not influenced by smoking and that young men were more frequently affected with an average age of 21 years. [6]
The increased risk of pneumothorax during Marfan syndrome is attributed to the presence of apical bullae or blebs, abnormalities of the connective tissue of the lung parenchyma and the greater mechanical stress in the apices linked to the large size of the patients. As for the histological lesions, they are no different from idiopathic spontaneous pneumothorax.
There is nothing special about the management of Marfan syndrome, but some authors suggest surgical intervention from the first episode given the high frequency of relapses after chest drainage. [7]

UNDER PEER REVIEW

Other respiratory manifestations are noted during Marfan syndrome. Obstructive sleep apnea hypopnea syndrome (OSAHS) is explained by the collapsibility of the larynx and associated craniofacial abnormalities. [8], [9]
Parenchymal abnormalities such as emphysema which is explained by the type 1 fibrillin abnormality which increases the risk of spontaneous pneumothorax. [11]
Bronchiectasis is described during Marfan syndrome, it is linked to the abnormality of elastin and collagen. [12]
There are multiple thoracic deformities during Marfan such as pectus carinatum, kyphosis and scoliosis but pectus excavatum remains the main malformation. [13], [14], [15]

Dilation of the aorta is the most serious vascular injury given the risk of aortic dissection. However, other arteries, of large or medium caliber, may be rarely affected. Exceptional cases of giant pulmonary artery aneurysms have been described. Dilatation of the pulmonary artery no longer constitutes a diagnostic criterion given the lack of specificity and the absence of reference data for the measurements. [16], [17], [18]

There is no curative treatment to date. Treatment must be multidisciplinary, based primarily on prevention. The cardiac component is based on the prescription of beta-blockers, calcium channel blockers are off-label and ACE inhibitors are still under evaluation. Anticoagulants are prescribed for people with mechanical valves.
The rheumatological component includes vitamin D and calcium supplementation. Growth inhibitors such as estrogen and depot somatostatin are off-label and analgesics are used in cases of pain.
Dental care and orthodontics are important for quality of life and prevention of endocarditis.
Surgical treatment can be offered, when indicated, either ophthalmological, cardiac, orthopedic or talc treatment.
Psychological support is desirable, particularly among adolescents. [19]

Conclusion

Marfan syndrome is a rare genetic connective tissue disorder. Cardiovascular damage constitutes the vital prognosis and the functional prognosis depends on the ophthalmological and musculoskeletal damage. Lung involvement rarely modifies the respiratory functional prognosis. The occurrence of a pneumothorax is rarely a mode of entry into the disease, hence the interest in discussing the diagnosis in cases of recurrent spontaneous pneumothorax or thoracic deformation.
Early medical and/or surgical treatment and monitoring improve the prognosis.

Consent

As per international standards, parental written consent has been collected and preserved by the author(s).

UNDER PEER REVIEW

References

1- Ho NCY, Tran JR, Bektas A. Marfan's syndrome. Lancet 2005;366:1978—81.
2- Guillermo, S “Marfan syndrome and pregnancy. About 16 cases and review of the literature » Dissertation: Midwife. Nantes:University of Nantes UFR Medicine, 2016 (76 pages)
3- Chan YC, Ting CW, Ho P, Poon JT, Cheung GC, Cheng SW. Ten-year epidemiological review of in-hospital patients with Marfan syndrome. Ann Vasc Surg. 2008 Sep;22(5):608-12
4- Philipon, P “Marfan syndrome” Publication of the French Association of Marfan syndrome, 2019 (64 pages)
5- Hall JR, Pyeritz RE, Dudgeon DL, Haller JA Jr. Pneumothorax in the Marfan syndrome: prevalence and therapy. Ann Thorac Surg. 1984 Jun;37(6):500-4
6- Karpman C, Aughenbaugh GL, Ryu JH. Pneumothorax and bullae in Marfan syndrome. Breathing. 2011;82(3):219-24
7- Suzuki T, Akiba T, Miyake R, Marushima H, Morikawa T. Familial spontaneous pneumothorax in two adult siblings with Marfan syndrome. Ann Thorac Cardiovasc Surg. 2010 Oct;16(5):362-4
8- Cistulli PA, Sullivan CE. Sleep apnea in Marfan's syndrome. Increased upper airway collapse during sleep. Chest. 1995 Sep;108(3):631-5
9- Verbraecken J, Paelinck BP, Willemen M, Van de Heyning P, De Backer W. Aortic root diameter and nasal intermittent positive airway pressure treatment in Marfan's syndrome. Clin Genet. 2003 Feb;63(2):131-4
10- Cistulli PA, Wilcox I, Jeremy R, Sullivan CE. Aortic root dilatation in Marfan's syndrome: a contribution from obstructive sleep apnea? Chest. 1997 Jun;111(6):1763-6
11- Jondeau G, Detaint D, Tubach F, Arnoult F, Milleron O, Raoux F et al. Aortic event rate in the Marfan population: a cohort study. Traffic. 2012 Jan 17;125(2):226-32
12- G Brinchault, V Morel, C Meunier, C Belleguic, P Delaval, Bronchial dilatations, EMC - Medicine, 2004, Volume 1, Issue 2, 131-140
13- Tocchioni F, Ghionzoli M, Messineo A, Romagnoli P. Pectus excavatum and heritable disorders of the connective tissue. Pediatr Rep. 2013 Sep 24;5(3):e15

UNDER PEER REVIEW

14- Stheneur C, Tubach F, Jouneaux M, Roy C, Benoist G, Chevallier B, et al. Study of evolution phenotype during childhood in Marfan syndrome to improve clinical recognition. Genet Med. 2014 Mar;16(3):246-50
15- Kelly RE, Goretsky MJ, Obermeyer R, Kuhn MA, Redlinger R, Haney TS, et al, Twenty-one years of experience with minimally invasive repair of pectus excavatum by the Nuss procedure in 1215 patients. Ann Surg. 2010 Dec;252(6):1072-81.
16- Détaint D, Faivre L, Collod-Beroud G, Child AH, Loeys BL, Binquet C, et al, Cardiovascular manifestations in men and women carrying an FBN1 mutation. Eur Heart J. 2010 Sep;31(18):2223-9
17- Awais M, Williams DM, Deeb GM, Shea MJ. Aneurysms of medium-sized arteries in Marfan syndrome. Ann Vasc Surg. 2013 Nov;27(8):1188.e5-7.
18- Pati PK, George PV, Jose JV. Giant pulmonary artery aneurysm with dissection in a case of Marfan syndrome. J Am Coll Cardiol. 2013 Feb 12;61(6):685.
19- TACQUET Hugo, MARFAN syndrome: pathophysiology, therapeutic management and role of the community pharmacist, Faculty of Pharmacy of Lille, 2021
20- Jaabouti G, Bencchakroun S, Mahraoui C, Hafidi NE. Post-TraumaticPulmonaryPneumatoceles: A Case Report. Asian J. Med. Health. [Internet]. 2023 Jun. 23 [cited 2024 May 30];21(9):95-100. Availablefrom:https://journalajmah.com/index.php/AJMAH/article/view/862

21- Onur B. Analysis of Patients with Emergency Thoracic Trauma. J. Adv. Med. Pharm. Sci. [Internet]. 2022 Dec. 29 [cited 2024 May 30];24(11-12):16-2. Availablefrom:https://journaljamps.com/index.php/JAMPS/article/view/586

22- Gottlieb M, Long B. Managingspontaneous pneumothorax. Annals of Emergency Medicine. 2023 May 1;81(5):568-76.

UNDER PEER REVIEW