

## Case report

### **Inferior dislocation of shoulder joint: Case Report**

#### **Abstract**

Although inferior shoulder dislocations are rare, they can occur due to high-energy trauma and present diagnostic and management challenges. This report describes the case of a 28-year-old male elephant handler who experienced an inferior dislocation of the right shoulder after falling from about 10 feet height while handling an elephant. Upon first inspection, it was seen that the shoulder was obviously distorted, with the arm positioned in a state of hyperabduction and external rotation. The diagnosis was verified by imaging examinations, and a successful closed reduction procedure was performed in the operating room under general anaesthesia. The rehabilitation program after the reduction procedure aims to restore shoulder function and prevent any future occurrences. This example emphasizes the significance of timely diagnosis, interdisciplinary treatment, and customized rehabilitation in attaining positive results in uncommon shoulder dislocations.

**Keywords:** inferior dislocation, shoulder joint, ball and socket joint

#### **Introduction**

Inferior dislocation of the shoulder, also referred to as luxatio erecta, is an uncommon form of shoulder dislocation in which the humeral head is elevated out of its socket and displaced below the glenoid cavity and the arm remains fixed in abduction [1]. Typically, it occurs as a result of a traumatic incident, such as a fall or motor vehicle collision [1]. Confirmation of this condition is typically achieved using imaging techniques like X-rays and CT scans [1]. The treatment for the inferior dislocation of the shoulder usually involves closed reduction under anaesthesia, where the humeral head is repositioned back into the glenoid cavity [1]. In certain cases, open reduction surgery may be necessary to address any associated injuries or bony defects [2].

It is important to understand that the management and outcomes of inferior dislocation of the shoulder can vary depending on the specific circumstances of each case. The success of treatment is influenced by factors such as the severity of the injury, the presence of associated injuries, and the expertise of the surgeon [2].

Various factors can influence the efficacy of therapy for inferior shoulder dislocation. A study revealed that the length of time an injury persists might influence the effectiveness of the reduction process, as a delay in seeking medical attention can make the reduction more challenging.[3] Moreover, the occurrence of concomitant greater tuberosity fractures might potentially impact the efficacy of the therapy.[3] The external rotation approach is considered a secure and dependable strategy for reduction throughout the procedure.[3]It should be emphasized that the effectiveness of treatment may differ based on individual patient characteristics and the proficiency of the treating physician. In this case report, inferior dislocation of shoulder was chosen and due to its unique nature and rare occurrence.

#### **Case Report**

A 28-year-old male who works as elephant handler, arrived at the emergency department with a primary complaint of intense discomfort in his right shoulder after falling from an elephant, approximately 10

feet in height. The patient stated that he was unable to lower his right arm below shoulder level and mentioned feeling significant discomfort in that region. He couldn't remember the exact mechanism of the fall. After the fall, he promptly had limited movement and intense discomfort in his right shoulder. He noticed that his right arm was incapable of descending below shoulder level, causing pain and limiting mobility. The patient denied experiencing any tingling or numbness, but he complained enduring soreness in the shoulder. To alleviate the pain, he provided support to the injured arm by using his other hand and keeping it in an arm raised up position. (Figure 1, 2) He was relatively healthy with no known underlying condition and no known allergy.

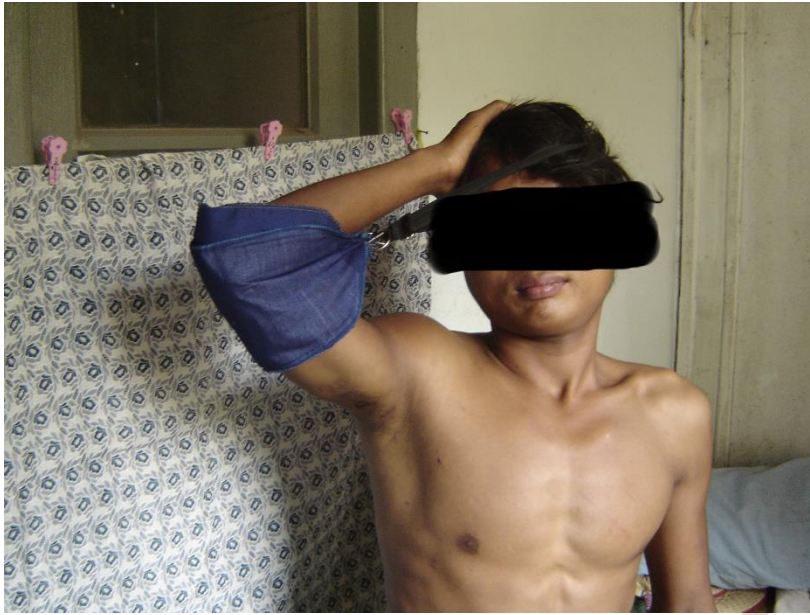Upon inspection, the right shoulder joint displayed limited mobility, with abduction restricted to approximately 130 degrees in the scapular plane. There were no apparent signs of swelling, no open wound in the affected area. Upon palpation, it revealed the presence of the humeral head through the axilla. Neurovascular examination demonstrated intact neurovascular status with no signs of impairment or deficits.

X-ray of right shoulder antero-posterior view was taken and found that right humeral shaft is shown (Figure 3,4) in the abducted position with the head sitting below the glenoid. However, there was no associated fractures of the glenoid or proximal humerus. Thus, the diagnosis of inferior dislocation of right shoulder joint was established and the patient underwent urgent shoulder reduction under general anaesthesia.

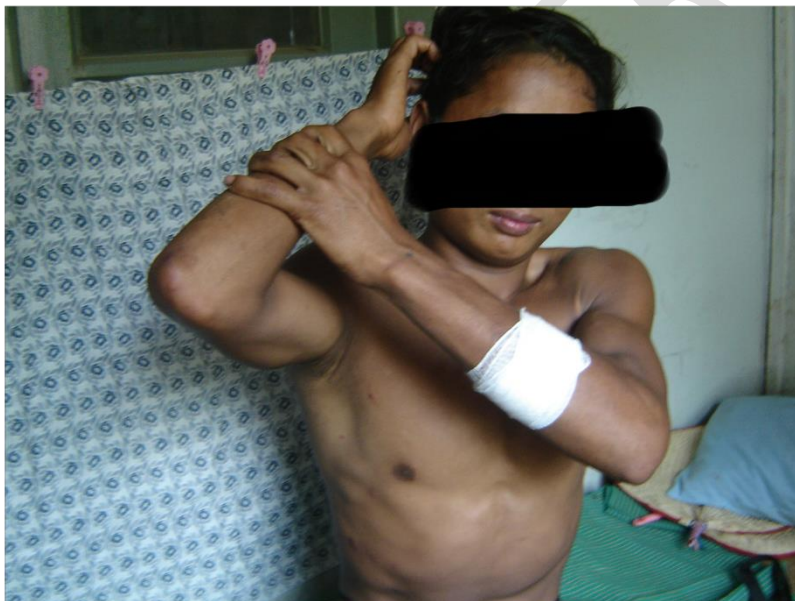Following the successful reduction treatment, the patient's right shoulder was immobilised using a combination of collar, calf, and body bandages. (Figure 5) Post-reduction X-rays antero-posterior view and lateral view (Figure 6) were conducted to evaluate the alignment of the shoulder joint, assuring accurate realignment, and detecting any possible remaining dislocations or fractures. The post-reduction X-ray was confirmed the successful realignment of the shoulder joint. Following the reduction procedure, the patient received a thorough neurovascular examination to determine the blood flow and nerve function to the affected area. Fortunately, all neurovascular measures were observed to be within normal limits and undamaged, suggesting no evident impairment or harm.

After the reduction procedure, the patient was placed in a shoulder sling to immobilise the shoulder. Additionally, a rehabilitation programme was initiated, which emphasised activities to improve the range of motion and strengthen the shoulder. He was released with directions for subsequent sessions to monitor improvement and ensure optimal recovery.

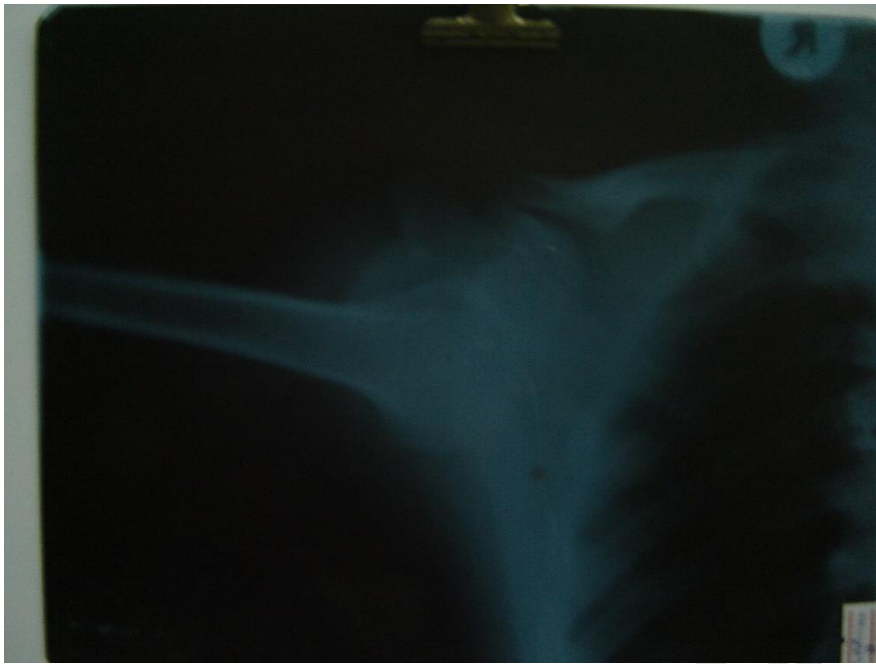**Figure 1 Posture of shoulder after injury**



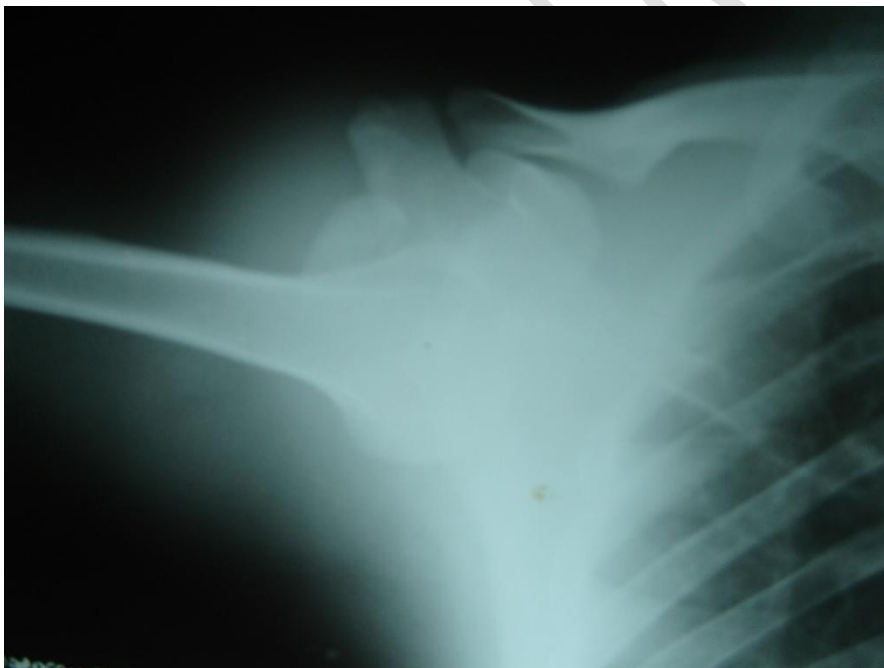
**Figure 2 Posture of shoulder after injury**



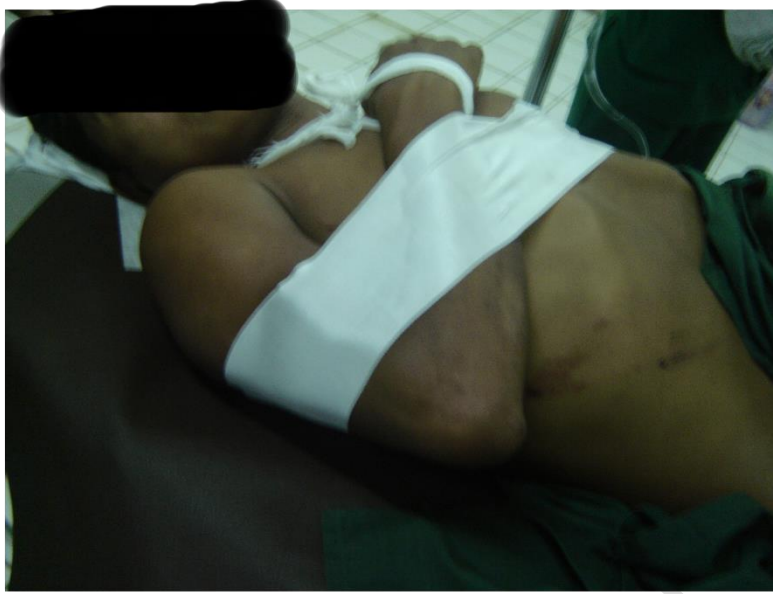**Figure 3 X-ray Antero-posterior view of right shoulder joint before reduction**



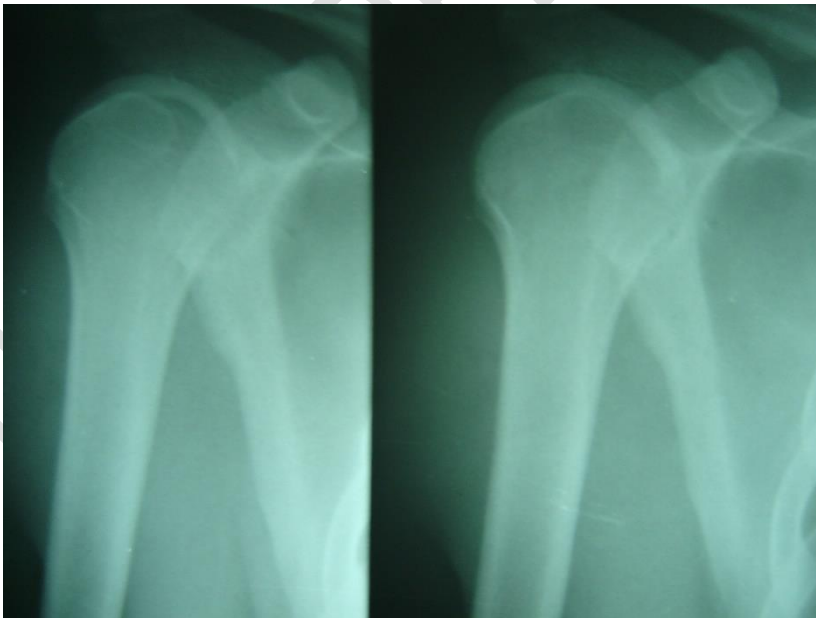
**Figure 4 X-ray Antero-posterior view of right shoulder joint before reduction**



**Figure 5. Post-reduction immobilisation of right shoulder joint**



**Figure 6 Post-reduction X-rays antero-posterior view and lateral view of right shoulder joint**



## **Discussion**

Infrequent occurrences of inferior shoulder dislocations may arise as a result of substantial trauma, such as falls from great heights or violent hyperabduction of the arm.[4] In this case, the patient's employment as an elephant handler is believed to have played a role in causing the injuries. Timely diagnosis by thorough clinical examination and advanced imaging techniques, such as X-rays and CT scans, is essential to provide appropriate treatment.[5]

The decision to perform closed reduction under general anaesthesia was made because to the failure to achieve reduction in the emergency department. Initial attempts at closed reduction are frequently made and might provide positive outcomes in several instances; however, surgical intervention may be required for complex or irreducible dislocations.[6]

The successful reduction of the shoulder in this case is consistent with the findings of this review, Osteoarthritis of the Glenohumeral Joint: A Review of Conservative Management Strategies, which discusses effective procedures for reducing the shoulder.[7]

Rehabilitation is crucial for recovering range of motion, strength, and function after a shoulder dislocation. It is recommended to start a customised physical therapy programme soon after surgery to improve results and avoid repeated dislocations.[8]

In summary, the effective handling of this case emphasises the significance of a multidisciplinary strategy that includes emergency medicine, orthopaedic surgery, and rehabilitation services in the treatment of patients with shoulder dislocations, especially in distinctive work environments where there is a risk of severe injuries.

## **Conclusion**

This case report demonstrates the rare incidence of an inferior shoulder dislocation in a 28-year-old male elephant handler after a fall from a considerable height. By promptly diagnosing and effectively managing the condition, which involved using closed reduction under general anaesthesia, the shoulder joint was successfully realigned.

The integration of emergency medicine, orthopaedic surgery, and rehabilitation services was crucial in providing holistic treatment for the patient. Effective cooperation among healthcare specialists achieved the best possible results and permitted a well-organized rehabilitation programme focused on recovering shoulder function and preventing further dislocations.

This case highlights the significance of comprehensive clinical assessment, imaging examinations, and customised treatment strategies in the management of uncommon shoulder injuries, especially in industrial environments with distinct injury causes. Ongoing research and the exchange of experiences among medical professionals help to advance the comprehension and treatment of intricate orthopaedic problems.

## **Consent and Ethical Approval**

Informed consent was taken from the patient and no ethical clearance is required.

## **Reference**

- [1]. Bawale, R., Soliman, A., Jain, R. and Singh, B., 2021. Bilateral Luxatio Erecta–Etiology, Diagnosis and Management. *Open Science Journal*, 6(2).
- [2]. Kumar, G.R., 2020. Neglected anterior shoulder dislocation managed by open reduction combined with Latarjet procedure. *International Journal of Orthopaedics*, 6(3), pp.909-911.

- [3]. Tamrakar, R., Acharya, B.M., Pradhan, N.M.S. and Shrestha, S.K., 2017. External rotation method for reduction of acute anterior dislocation of shoulder. *Journal of Patan Academy of Health Sciences*, 4(2), pp.39-43.
- [4]. Raiss, P., Lin, A., Mizuno, N., Melis, B. and Walch, G., 2012. Results of the Latarjet procedure for recurrent anterior dislocation of the shoulder in patients with epilepsy. *The Journal of Bone & Joint Surgery British Volume*, 94(9), pp.1260-1264.
- [5]. Murray, J.C., Leclerc, A., Balatri, A. and Pelet, S., 2020. Immobilization in external rotation after primary shoulder dislocation reduces the risk of recurrence in young patients. A randomized controlled trial. *Orthopaedics & Traumatology: Surgery & Research*, 106(2), pp.217-222.
- [6]. Leland, D.P., Bernard, C.D., Keyt, L.K., Krych, A.J., Dahm, D.L., Sanchez-Sotelo, J. and Camp, C.L., 2020. An age-based approach to anterior shoulder instability in patients under 40 years old: analysis of a US population. *The American journal of sports medicine*, 48(1), pp.56-62.
- [7]. van der Meijden, O.A., Gaskill, T.R. and Millett, P.J., 2012. Glenohumeral joint preservation: a review of management options for young, active patients with osteoarthritis. *Advances in orthopedics*, 2012.
- [8]. Skare, Ø., Liavaag, S., Reikerås, O., Mowinckel, P. and Brox, J.I., 2013. Evaluation of Oxford instability shoulder score, Western Ontario shoulder instability index and Euroqol in patients with SLAP (superior labral anterior posterior) lesions or recurrent anterior dislocations of the shoulder. *BMC research notes*, 6, pp.1-10.