

# **Myocardial infarction with non-obstructive coronary arteries (MINOCA) revealing polycythemia Vera :A case report**

## **Abstract**

**Introduction:**acute myocardial infarction typically associated with atherosclerosis and coronary lesions, can occur without significant stenosis, implicating microcirculatory obstruction.

**Case presentation:**We present a case of a 60-year-old woman with hypertension and atrial fibrillation who was admitted with chest pain. Initially diagnosis of high-risk NSTEMI, but coronary angiography showed no significant lesions. Cardiac MRI revealed myocardial necrosis, indicating myocardial infarction with non-obstructive coronary arteries (MINOCA). Further investigation identified polycythemia vera as the cause. The patient was transferred to the hematology department and discharged with DAPT, atorvastatin, and bisoprolol.

**Conclusion:**The case presented illustrates the importance of recognizing polycythemia vera as an important cause of thrombosis, not only of MI with significant coronary lesion, but also of MI with non-obstructive coronary arteries.

## **Keywords :**

MINOCA, Polycythemia Vera, myocardial infarction, Cardiac MRI

## **Introduction**

Acute myocardial infarction (AMI) is usually seen in the context of atherosclerosis and the cardiovascular risk factors, usually with the presence of obstructive coronary lesions. However, a significant number of patients can present a myocardial infarction even in the absence of any significant coronary stenosis, and obstruction of the coronary microcirculation is increasingly implicated as a relevant cause of this AMI. This obstruction may be secondary to certain thrombo-embolic and hypercoagulable conditions such as polycythemia vera [1].

We report the case of a 60-year-old female patient presented with non-obstructive coronary arteries (MINOCA) revealing polycythemia vera as an unusual presentation [11,12]. This association of polycythemia vera and acute myocardial infarction (AMI) has rarely been reported. However, no case associating myocardial infarction with non-obstructive coronary arteries (MINOCA) and polycythemia vera has been reported. In this paper, we illustrate the clinical fact of AMI, specifically MINOCA occurring in a patient with Polycythemia Vera.

### **Case Presentation:**

We report the case of a 60-year-old menopausal woman with a history of arterial hypertension treated with monotherapy for 5 years. She had also been treated with VKAs for atrial fibrillation for 5 years. The patient was admitted to the emergency department with typical angina-like chest pain. The electrocardiogram showed atrial fibrillation at 77 bpm with inferior flat T waves. Admitted biology revealed a positive US troponin of 1600 ng/L (upper limit of normal 15 ng/L). Echocardiography (TTE) showed mild inferior wall hypokinesia with acceptable biventricular function and preserved LVEF (Figure N°1).

The diagnosis of high-risk non-ST-elevation myocardial infarction (NSTEMI) was confirmed. In accordance with the latest European Society of Cardiology (ESC) recommendations, pre-hospital medical treatment was initiated with single antiplatelet therapy with aspirin, anticoagulation with enoxaparin 1 mg/kg and anxiolytic. In addition, coronary angiography performed within 24 hours showed smooth arteries with no significant coronary lesions (Figure N°2).

For further investigations, Cardiac MRI was carried out and revealed focal infero-apical myocardial necrosis estimated at 4.3% of total myocardial mass, with no residual viability in the distal right coronary territory, consistent with coronary artery disease due to microvascular obstruction (Figure N°3). For that the final diagnostic of Myocardial Infarction with No Obstructive Coronary Arteries (MINOCA) was retained.

The medical team conducted a search for the cause of the thromboembolic event. The initial biological assessment upon admission revealed elevated platelet count ( $720 \times 10^3$  platelets/mm<sup>3</sup>), high hemoglobin levels at 17.2 g/dl, and increased white blood cell count at 17000 elements/mm<sup>3</sup> and perturbed lipid levels. Due to these abnormal results, a hematologist was consulted and after further investigation they confirmed the diagnosis of polycythemia vera. Consequently, the patient was transferred to the hematology department for ongoing care. However, there was uncertainty regarding the discharge prescription. After considering the recommendation, it was decided to continue the dual antiplatelet therapy (DAPT) for six months, along with 80 mg of atorvastatin and 5 mg of bisoprolol.

### **Discussion:**

MINOCA, commonly known as myocardial infarction without obstructive coronary stenosis, is a syndrome that has multiple causes. It is marked by clinical signs of myocardial infarction (according to the third universal definition of infarction) and angiographically normal or nearly normal coronary arteries [1]. In the literature, a widely accepted threshold for defining a stenosis as non-obstructive is when the lesions seen on angiography occupy less than or equal to 50% of the vessel's lumen.

Polycythemia vera (PV) is a type of blood cancer that is not commonly found. It was first described by William Dameshek in 1951. PV falls under the category of chronic myeloproliferative neoplasms, which are connected with a genetic abnormality called the Philadelphia chromosome. This condition leads to an unusual increase in the number of blood cells originating from stem cells.[2].

The exact mechanisms that cause blood clots in PV are not fully understood, but there are several factors that contribute to their occurrence. These factors include abnormalities in the clotting process, which suggest an underlying condition of increased blood clotting. This is characterized by higher levels of certain substances in the blood, such as D-dimers and thrombin-anti-thrombin complex, which are markers of blood clotting, as well as thrombomodulin and VWF/factor VIII, which indicate activation of the endothelium. Other factors include higher hematocrit and blood viscosity, which make the blood thicker and more prone to clotting, stimulation of platelet aggregation and formation of clots, and the presence of leukocytosis and intimal proliferation, which can block small blood vessels in the heart. Additionally, there have been observations of high levels of thrombin production and acquired resistance to activated protein C, as well as increased levels of pro-coagulant

microparticles derived from blood cells. These findings have provided valuable information for detecting a prothrombotic state in patients with PV. [3].

The understanding of PV's molecular pathogenesis took place in 2007 when a mutation in exon 12 of the JAK2 (Janus Kinase 2) gene was identified, present in 95% of PV patients. Although the median age of diagnosis is 60, PV can manifest across all age groups, however, advanced age and a history of thrombosis are the two primary risk factors for vascular complications [4].

Polycythemia vera (PV) can be detected incidentally during a routine blood test or may manifest through clinical symptoms primarily associated with thrombosis and/or bleeding. The incidence of thrombo-hemorrhagic complications is substantial, contributing significantly to patient morbidity and mortality, estimated to range from 11% to 39% [5]. Arterial thrombosis represents the predominant form of thrombo-hemorrhagic complications, leading to various conditions such as ischemic stroke, myocardial infarction, and peripheral arterial occlusion [6].

Early detection plays a crucial role in effectively managing acute coronary syndrome (ACS) in patients with polycythemia vera (PV), as it can occasionally serve as a revealing factor for the condition. Although larger studies have provided data on the occurrence of ACS, information regarding the specific characteristics of ACS as a complication of PV is primarily derived from individual case reports. Furthermore, there have been no documented instances of PV leading to myocardial infarction with non-obstructive coronary arteries.

In a comprehensive epidemiological investigation of polycythemia vera, it was revealed that cardiovascular mortality, specifically coronary heart disease and non-hemorrhagic stroke, constituted a significant portion of all fatalities, totaling 41%. Additionally, the presence of atrial fibrillation in PV patients, as demonstrated in our case, presents a formidable obstacle in terms of treatment due to the elevated risk of both thrombosis and bleeding. Recent research indicates that the prevalence of AF in PV patients is 18%, compared to 11% in the general population [8].

In our approach to managing the MINOCA consisted the treatment of the etiology, which in this case was polycythemia vera, as well as managing the associated atrial fibrillation by controlling heart rate and implementing curative anticoagulation using rivaroxaban. Managing polycythemia vera (PV) with concurrent atrial fibrillation presents challenges due to the increased risks of both thrombosis and bleeding. Although there are no established standard recommendations or guidelines, this case highlights that oral anticoagulation therapy specially NOAC's (Non-Vitamin K antagonist oral anticoagulants) can be a safe and convenient option for patients in similar situations [9].

The treatment of PV primarily involved the use of acetylsalicylic acid (ASA) and regular bloodletting to maintain hematocrit levels below 45%. Additionally, the introduction of cyto-reductive therapy with hydroxyurea was recommended as the initial treatment option, while other therapies, such as ruxolitinib (a JAK2 inhibitor), could be considered as subsequent options [10].

### **Conclusion**

The case presented illustrates the importance of recognizing polycythemia vera as an important cause of thrombosis, not only of MI with significant coronary lesion, but also of MI with non-obstructive coronary arteries, which may be a possible consequence of this hematological disease through microvascular obstruction such as PV.

### **ABBREVIATION LIST:**

- MINOCA : Myocardial infarction with non-obstructive coronary arteries
- PV: polycythemia vera
- MI: myocardial infarction
- ACS: Acute coronary syndrome

- NSTEMI: non-ST-elevation myocardial infarction
- TTE: Echocardiography
- JAK2 : gene Janus Kinase 2
- DAPT : dual antiplatelet therapy
- ESC : European Society of Cardiology
- NOAC's : Non-Vitamin K antagonist oral anticoagulants
- **Highlights :**
- 
- Recognize the role of advanced imaging in confirming myocardial infarction without significant coronary blockages (MINOCA) when standard angiography appears normal.
- 
- Understand the contribution of non-atherosclerotic factors, like polycythemia vera, in causing MINOCA, especially in patients with hypertension and atrial fibrillation.
- 
- Evaluate management approaches involving dual antiplatelet therapy and other medications in MINOCA related to polycythemia vera, considering both cardiovascular and hematological aspects.
- 

### **Consent :**

informed written consent has been obtained

### **REFERENCES**

1. Soheila Talebi,Preeti Jadhav, Jacqueline E. Tamis-Holland.Myocardial. Infarction in the Absence of Obstructive Coronary Artery Disease (MINOCA): a Review of the Present and Preview of the Future.Curr Atheroscler Rep. 2021; 23(9): 49. 10.1007/s11883-021-00945-0.

2. Tefferi A. Polycythemia vera and essential thrombocythemia: 2013 update on diagnosis, risk-stratification, and management. *Am J Hematol.* juin 2013;88(6):507- 16.
3. Falanga A, Marchetti M. Thrombosis in Myeloproliferative Neoplasms. *Semin Thromb Hemost.* 9 mars 2014;40(03):348- 58.
4. Hussain Bahbahani,a,Khaled Aljenaee,b and Abdelhaleem Bellac. Polycythemia vera presenting as acute myocardial infarction: An unusual presentation. *J Saudi Heart Assoc.* 2015 Jan; 27(1): 57–60. 10.1016/j.jsha.2014.07.003.
5. Hermanns B, Handt S, Kindler J, Füzesi L. Coronary vasculopathy in polycythemia vera. *Pathol Oncol Res.* 1998;4(1):37- 9.
6. Falanga A, Marchetti M. Thrombotic disease in the myeloproliferative neoplasms. *Hematology Am Soc Hematol Educ Program.* 2012;2012:571- 81.
7. Betul Cengiz , Vedat Aytekin , Ulas Bildirici , ET AL A rare cause of acute coronary syndromes in young adults - myeloproliferative neoplasms: A case series. *Rev Port Cardiol (Engl Ed).* 2019 Sep;38(9): 613-617.10.1016/j.repc.2018.09.014.
8. Abstract 16068: Polycythemia Vera is Associated With Increased Atrial Fibrillation Compared to the General Population: Results From the National Inpatient Sample Database | *Circulation* [Internet]. [cité 5 juin 2023]. Disponible sur: [https://www.ahajournals.org/doi/10.1161/circ.134.suppl\\_1.16068](https://www.ahajournals.org/doi/10.1161/circ.134.suppl_1.16068).
9. Waseem Umer, Naseem Umer, Elrazi A Ali, Polycythemia Vera With Atrial Fibrillation: A Case Report and Review of the Literature.*Cureus.* 2022 Aug; 14(8):e28550. 10.7759/cureus.28550.
10. Aaron T. Gerds, Kim-Hien Dao, Polycythemia Vera Management and Challenges in the Community Health Setting ,*Oncology.* 2017 Apr; 92(4): 179–89. 10.1159/000454953.
11. Shabana, A., Moustafa, M., El-Menyar, A., & Al-Thani, H. (2013). Cardiogenic Shock Complicating Myocardial Infarction: An Updated Review. *Journal of Advances in Medicine and Medical Research*, 3(3), 622–653. <https://doi.org/10.9734/BJMMR/2013/2464>
12. Rahman, M., Rahman, M. M., Ahmed, M., Chowdhury , S. K., Hossan, M. A., Hasan , S., Islam, N., & Rashid , S. (2024). Circadian Variation of Stroke in a Tertiary Level Hospital. *Asian Journal of Medicine and Health*, 22(3), 41–48. <https://doi.org/10.9734/ajmah/2024/v22i3991>

## FIGURES COMMENTS

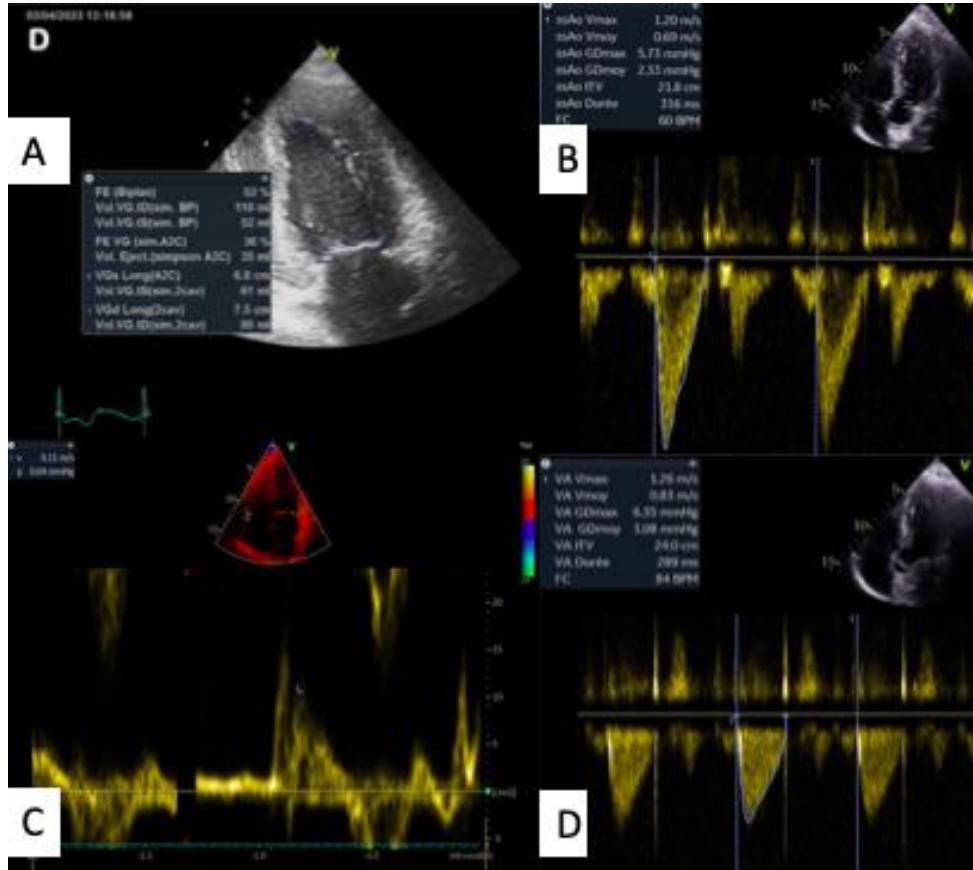


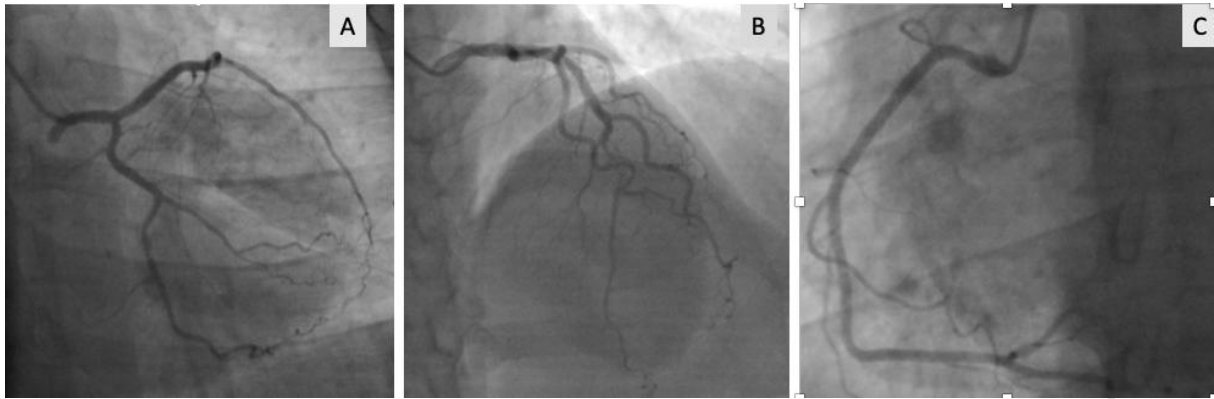
Figure N°1: Different parameters of the echocardiography

A: left ventricle ejection fraction by biplane Simpson of 53%.

B: Pulsed dopplersignal obtained by 2D-5 chambers view shows a normal specter of sub-aortic velocity time integral

C: 2D-4 chambers view shows the peak S wave in pulsed tissue Doppler mode at the tricuspid annulus reflect the normal longitudinal contraction of the VD.

D: continuous Doppler signal obtained by 2D-5 chambers view shows a normal specter of aortic velocity time integral.

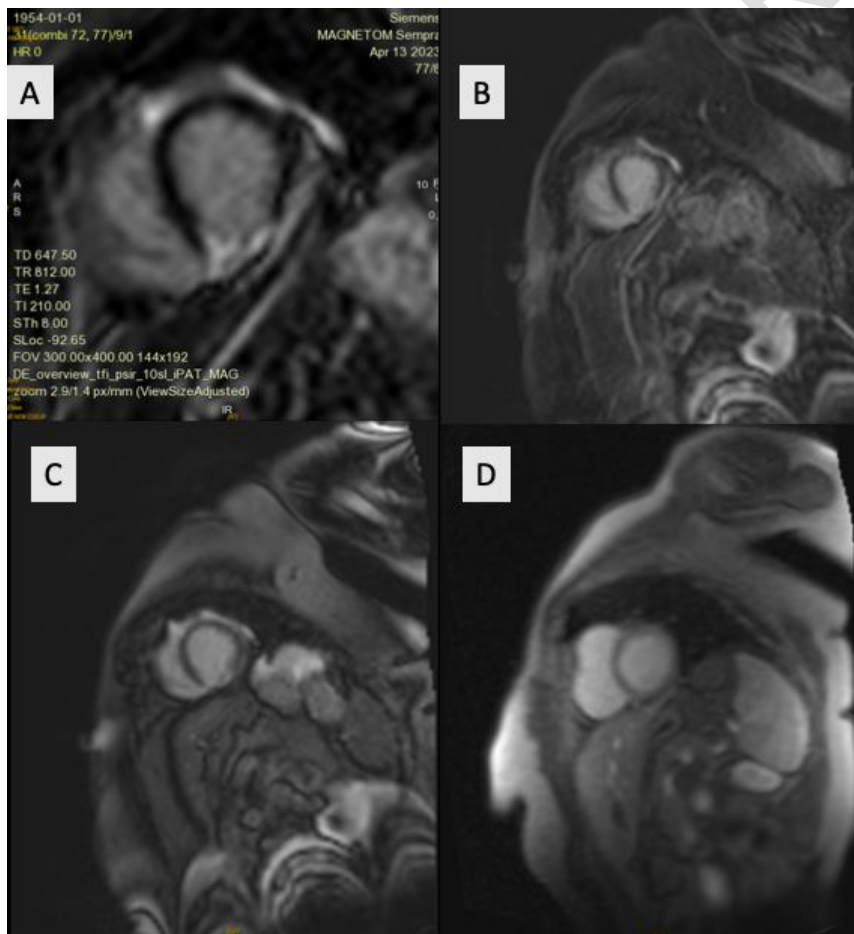


Figures N°2:Coronary angiography that demonstrates the absence of significant coronary lesions:

A: In the caudal view, the coronary angiography revealed a normal circumflex artery (CX).

B: In the cranial view, the coronary angiography showed a normal left descending artery (LAD).

C: LAO view (left anterioroblique) showed an intact right coronary artery (RCA).



Figures N°3: MRI loops indicate the following:

- The patient has ischaemic cardiomyopathy characterized by a dilated left ventricle with non-hypertrophied walls and impaired systolic function.
- The right chambers of the heart are dilated, and the right ventricle demonstrates good overall and segmental systolic function.
- The observed appearance suggests a focal infero-apical myocardial necrosis with no residual viability in the distal right coronary territory.

UNDER PEER REVIEW