

## Sebaceous Carcinoma of the Eyelid; a pseudochalazion entity :A Case Report and Review of the Literature

### ABSTRACT :

Palpebral sebaceous carcinoma (PSC) is a rare malignancy originating from sebaceous glands in the eyelid, often mimicking benign inflammatory conditions such as blepharoconjunctivitis or chalazion, leading to diagnostic delays. This article presents a case of a 42-year-old female with a painless upper eyelid lump diagnosed as sebaceous carcinoma. The lesion was successfully treated, resulting in positive functional and aesthetic outcomes. This case underscores the importance of early biopsy and histological examination to distinguish PSC from benign conditions. Current treatment guidelines emphasize surgical excision with margin assessment, and radiotherapy for advanced cases. Establishing follow-up protocols based on melanoma guidelines is recommended due to similar metastatic patterns.

Keywords: Sebaceous carcinoma, eyelid tumor, early diagnosis, chalazion, female, middle aged

### INTRODUCTION:

Palpebral sebaceous carcinoma (PSC) is an uncommon malignancy<sup>(1)</sup> originating from meibomian or adnexal epithelium of sebaceous glands<sup>(2)</sup>. The tumor can mimic inflammatory conditions like blepharoconjunctivitis, recurrent chalazion, or superior limbic keratoconjunctivitis. (3, 4, 5) leading to frequent delays in diagnosis (6). The clinical presentation of the condition may lack specific characteristics, underscoring the importance of a biopsy for both confirming the diagnosis and distinguishing it from similar-appearing conditions (7).

### CASE REPORT:

A 42-year-old female patient without notable ophthalmological or general medical history was the subject of our observation. She came in with a painless lump on the upper right eyelid that had been developing for more than 8 months. During examination, a 1.8 cm chalazion-like nodular lesion was noted. Eversion of the eyelid revealed a clear tarsus. A clinical examination indicated a clear orbital cavity, and there were no detectable cervical nodes upon palpation. The general examination did not reveal any other noteworthy findings.

The pathology results confirmed the presence of a sebaceous carcinoma measuring 1.8 cm with clear margins.

The patient experienced positive results in terms of functionality, anatomy, and aesthetics.

According to the American Joint Committee on Cancer (AJCC) TNM classification for eyelid tumors in its 7th edition, the tumor was categorized as PT2aN0M0.

### DISCUSSION :

“Diagnosing the condition is frequently challenging, primarily because in the early stages, the external signs are subtle and may resemble benign lesions. In over 50% cases, sebaceous carcinoma (SC) may present as a pseudochalazion or a chronic blepharoconjunctivitis”. (3, 5, 8, 9).

Any chalazion displaying unusual consistency or recurring after incision and curettage on more than three occasions should be subjected to complete thickness resection and histological examination.

“Sebaceous cell carcinoma is much more common in the upper eyelid due to the larger number of meibomian glands being present there, followed by the lower lid”. (10)

“Upper eyelids SC tend to metastasize to preauricular and parotid nodes, which represent the most common sites of metastasis”(11)

“It is important to examine the patient carefully for evidence of pagetoid spread or multicentric origin by double eversion of the eyelids, and any conjunctival alteration such as telangiectasia, papillary change, or a mass. In such an instance, conjunctival punch biopsies should be taken in addition to surgical resection of the lid lesion”(12)

We determined that deep biopsy is frequently necessary. Additionally, specialized histological stains can be employed to eliminate differential diagnoses that imitate the condition.

“For treatment, the recommended first-line therapy is surgical removal, followed by margin assessment of the peripheral and deep tissue edges; conjunctival mapping biopsies can facilitate surgical planning”(13) “Radiotherapy can be considered for cases with nerve or lymph node involvement, and as the primary treatment in patients who are ineligible for surgery”.(13)

Overall, the absence of a dedicated follow-up guideline for sebaceous carcinoma (SC) in existing literature is notable. Considering the infrequency of SC affecting the eyelid, the establishment of surveillance recommendations necessitates a comprehensive literature review on this subject, coupled with deliberations among expert groups.

Due to similar metastizing pattern, the guideline for melanoma follow-up (14) could probably be appropriated. “It includes follow-up visit every 3 months until 2 years have passed from the diagnosis. Thereafter, follow-up is continued every 6 months for 5 years”. [14]

#### **CONCLUSION:**

Sebaceous carcinoma is uncommon but is associated with a serious prognosis. The condition can be easily confused with an inflammatory disorder. Consequently, any nodular or recurring lesions on the eyelid of an elderly individual should undergo histological examination.

#### **Consent**

As per international standards or university standards, patient(s) written consent has been collected and preserved by the author(s).

#### **Ethical Approval:**

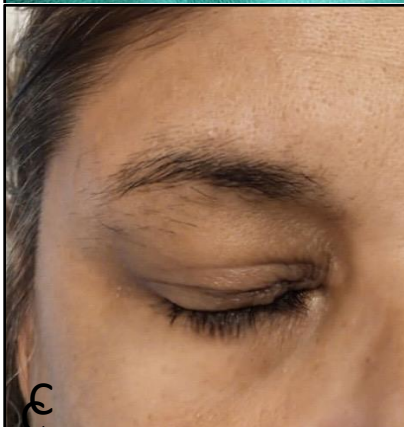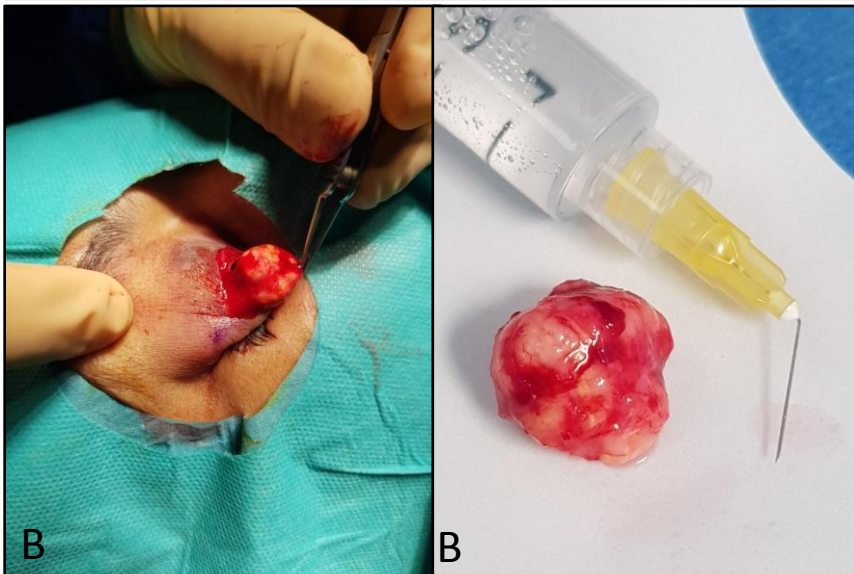
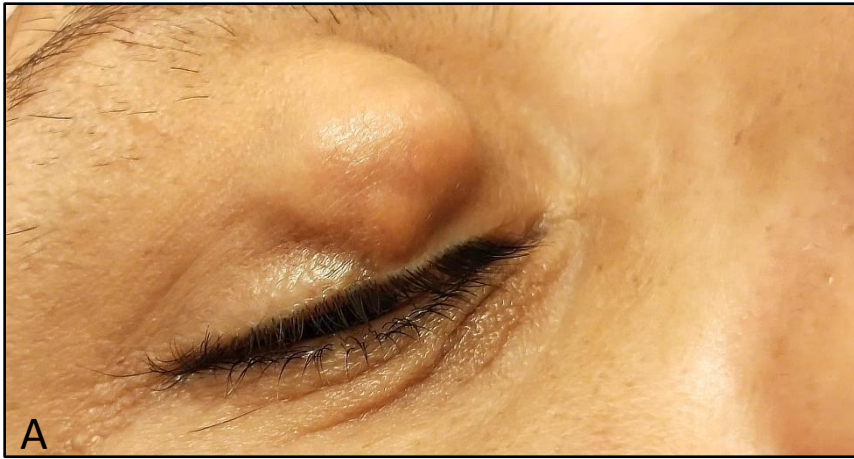As per international standards or university standards written ethical approval has been collected and preserved by the author(s).

**CONFLICT OF INTEREST** :Authors declare that they do not have any conflict of interest.

#### **REFERENCES :**

- (1) UIKadirS,RaniMitraM,RashidR, NuruddinM, KhanKH, et al.Clinicopathological Analysis and Surgical Outcome of Eyelid Malignancies: A Study of 332 Cases. J Skin Cancer. 2022; 18:4075668
- (2) Dowd MB, Kumar RJ, Sharma R, Murali R. Diagnosis and management of sebaceous carcinoma: an Australian experience. ANZ J Surg. 2008;78(3):158-63
- (3) Foster CS, Allansmith MR. Chronic unilateral blepharoconjunctivitis caused by sebaceous carcinoma. Am J Ophthalmol. 1978;86:218–20
- (4) Sweebe EC, Cogan DG. Adenocarcinoma of the meibomian gland; a pseudochalazion entity. Arch Ophthalmol. 1959;61:282–90.
- (5) Condon GP, Brownstein S, Codère F. Sebaceous carcinoma of the eyelid masquerading as superior limbic keratoconjunctivitis. Arch Ophthalmol. 1985;103:1525–9

- (6) Gu X, Xie M, Luo Y, Song X, Xu S, Fan X. Diffuse pattern, orbital invasion, perineural invasion and Ki-67 are associated with nodal metastasis in patients with eyelid sebaceous carcinoma. *Br J Ophthalmol*. 2022
- (7) Knackstedt T, Samie FH. Sebaceous Carcinoma: A Review of the Scientific Literature. *CurrTreat OptionsOncol*.2017;18(8):47
- (8) Scheie HG, Yanoff M, Frayer WC. Carcinoma of Sebaceous glands of the eyelid. *Arch Ophthalmol*. 1964;72:800–3
- (9) Hagedoorn A. Paget's disease of the eyelid associated with carcinoma. *Br J Ophthalmol*. 1937;21:234–41
- (10) Song A, Carter KD, Syed NA, Song J, Nerad JA. Sebaceous cell carcinoma of the ocular adnexa: Clinical presentations, histopathology, and outcomes. *OphthalPlastReconstr Surg*. 2008;24:194–200.
- (11) Shields JA, Demirci H, Marr BP, Eagle RC Jr, Shields CL. Sebaceous carcinoma of the eyelids: personal experience with 60 cases. *Ophthalmology*. 2004;111(12):2151-7.
- (12) Putterman AM. Conjunctival map biopsy to determine pagetoid spread. *Am J Ophthalmol*. 1986;102:87–90.
- (13) Owen JL, Kibbi N, Worley B, Kelm RC, Wang JV, Barker CA, Behshad R, Bichakjian CK, Bolotin D, Bordeaux JS, Bradshaw SH, Cartee TV, Chandra S, Cho NL, Choi JN, Council ML, Demirci H, Eisen DB, Esmaeli B, Golda N, Huang CC, Ibrahim SF, Jiang SB, Kim J, Kuzel TM, Lai SY, Lawrence N, Lee EH, Leitenberger JJ, Maher IA, Mann MW, Minkis K, Mittal BB, Nehal KS, Neuhaus IM, Ozog DM, Petersen B, Rotemberg V, Samant S, Samie FH, Servaes S, Shields CL, Shin TM, Sobanko JF, Somani AK, Stebbins WG, Thomas JR, Thomas VD, Tse DT, Waldman AH, Wong MK, Xu YG, Yu SS, Zeitouni NC, Ramsay T, Reynolds KA, Poon E, Alam M. Sebaceous carcinoma: evidence-based clinical practice guidelines. *Lancet Oncol*. 2019 Dec;20(12):e699-e714. doi: 10.1016/S1470-2045(19)30673-4. PMID: 31797796.
- (14) Finnish Medical Society Duodecim. Skin cancer. In: EBM Guidelines. Evidence-Based Medicine [Internet]. Helsinki, Finland: Wiley Interscience. John Wiley & Sons; 2005.
- (15) Shambharkar, M., Udan, R., Swarkar, A., Khandar, J., Sakharkar, S. and Tembhare, V. (2021) "Case Report on Squamous Cell Carcinoma of the Lip", *Journal of Pharmaceutical Research International*, 33(53B), pp. 182–188. doi: 10.9734/jpri/2021/v33i53B33695.
- (16) Fatima, S., Hosein, M., Butt, S. A., Baig, F. A., Siddiqui, R. A., & Abidi, F. (2020). Squamous Cell Carcinoma of Tongue: Analysis of Clinico Pathological Features. *Journal of Advances in Medicine and Medical Research*, 32(24), 198–203. <https://doi.org/10.9734/jammr/2020/v32i2430767>
- (17) Shields, J. A., Demirci, H., Marr, B. P., Eagle Jr, R. C., & Shields, C. L. (2004). Sebaceous carcinoma of the eyelids: personal experience with 60 cases. *Ophthalmology*, 111(12), 2151-2157.



Figures: A- Clinical presentation reveals a significant mass on the right upper eyelid. The predominant clinical manifestation is a painless, firm, sessile to round. The skin overlaying the lesion typically appears smooth and displays reasonable mobility. B- Perioperative imaging of the removal of a sebaceous carcinoma mass from the upper eyelid C- 2 weeks post-operative and two weeks after surgical resection of the tumor and reconstruction of the eyelid.