

Case report

Cerebral Venous Thrombosis as a complication of Ulcerative Colitis – A case report

ABSTRACT

Chronic inflammatory bowel diseases (IBD), like other systemic inflammatory diseases, are associated with an increased risk of venous and arterial thromboembolic complications. This risk is closely correlated with disease activity. Deep-vein thrombosis and pulmonary embolism are the most common manifestations. A cerebral venous sinus thrombosis may rarely occur identified by cerebral MRI in the presence of suggestive symptoms. Therapeutic management is based on anticoagulant therapy, the duration of which depends on associated venous thromboembolic risk factors, which should be identified in all IBD patients. Thromboembolic events represent a major cause of morbidity and mortality, so the overall management of IBD patients must actively integrate the prevention of these complications. We report the case of a 32 years-old female patient with distal UC on azathioprine, hospitalized with a moderate flare-up of her disease, presenting with intense headache, photophobia, followed by a febrile tonic-clonic convulsive seizure with paresthesia of all 4 limbs and left facial paralysis, revealing on cerebral MRI a venous thrombosis of the superior longitudinal sinus and right lateral sinus responsible for an oedemato-hemorrhagic remodelling. The patient received anticoagulant therapy based on low-molecular-weight heparin followed by **vitamin K antagonists** (VKA). The course was favorable, with complete clinical and radiological remission.

Keywords: distal UC, moderate flare, superior longitudinal sinus venous thrombosis, right lateral sinus venous thrombosis, anticoagulation.

1. INTRODUCTION

Chronic inflammatory bowel diseases (IBD) are associated with an increased risk of venous and arterial thromboembolic events. This risk is higher during periods of disease activity. Indeed, IBD are considered to be a state of hypercoagulability, and patients affected by this disease are three to four times more likely to develop thrombosis than the general population [3]. Deep vein thrombosis or pulmonary embolism are the typical presentations, but rarer manifestations can also occur, such as cerebral venous sinus thrombosis (CVST) [4]. In hospitalized patients, the risk of venous thromboembolism is higher in ulcerative colitis (UC) than in crohn's disease (CD) [1].

This report describes the presentation of a young woman who developed neurological symptoms during a moderate flare-up of her ulcerative colitis. Early imaging revealed CVST and, with prompt treatment, she achieved complete remission.

2. PRESENTATION OF CASE

This is a 32 years-old female patient, followed since 2020 for distal UC, which was diagnosed in the presence of chronic bloody diarrhea associated with rectal syndrome, elevated fecal calprotectin (> 600 µg/g) and ulcero-hemorrhagicrectitis on ileo-colonoscopy, and whose anatomopathological study revealed cryptic abscesses. Radiologically, the abdomino-pelvic CT scan revealed diffuse oedema of the colonic framework, with an additional image on the wall of the sigmoid colon, indicating significant loss of substance due to the deep ulcerations. Therapeutically, the patient was initially treated with topical and oral 5-ASA at a dose of 4gr/day, then changed to azathioprine 150 mg/day due to corticosteroid dependence.

The patient was admitted for a moderate flare-up of her disease, with bloody diarrhoea (4-5 stools/day) associated with rectal syndrome, diffuse abdominal pain and altered general condition, with no other associated digestive or extra-digestive signs. Clinical examination revealed a cutaneous and mucosal pallor, diffuse abdominal tenderness with no defensiveness, and a normal body mass index of 21 kg/m². Biologically, the patient presented with normocytic normochromic anemia with a hemoglobin level of 5.7 g/dl, thrombocytosis of 800,000 elements/mm³ and an elevated CRP of 57.6 g/l. The white blood cell count was correct at 5280 cells/mm³. The fluid and electrolyte balance were without abnormality, the 3 parasitological tests and the stool culture were negative. On admission, an unprepared abdominal X-ray and an abdominal ultrasound were without abnormalities.

During her hospitalization, the patient presented intense headache with photophobia, followed by a febrile tonic-clonic convulsive seizure and sensory deficit in all 4 limbs with paresthesia and left facial paralysis. As part of the etiological assessment of this symptomatology, an injected cerebral CT scan was performed, showing no abnormalities, and a lumbar puncture was performed which returned sterile. We therefore completed with a cerebral MRI, which revealed venous thrombosis of the superior longitudinal sinus and right lateral sinus responsible for an oedemato-haemorrhagic remodelling (Figure 1).

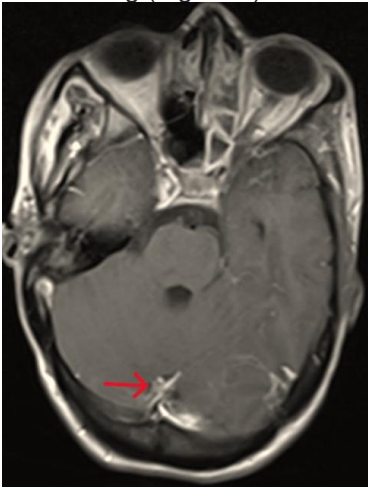
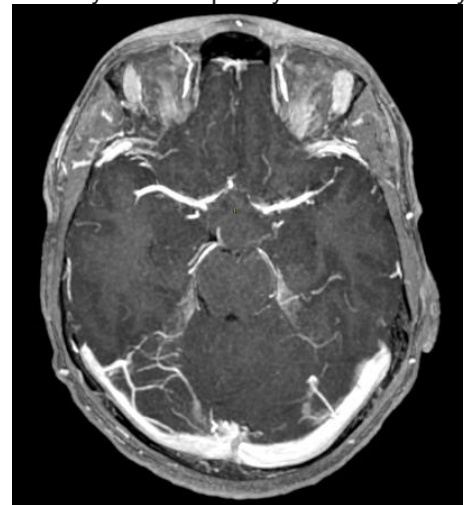

Figure 1 : MRI image 3D T1 sequence after gadolinium injection showing venous thrombosis of the superior longitudinal sinus and the right lateral sinus

In addition, a thrombophilia assessment was negative and no other thrombo-embolic risk factors were identified. Therapeutically, the patient was treated with low-molecular-weight heparin at a curative dose (6,000 IU x 2/d), followed by vitamin k antagonist (VKA) and Levetiracetam. After one week of treatment, the patient showed marked clinical improvement: headache reduction, disappearance of photophobia and complete recovery of facial paralysis and sensory



deficit. A follow-up MRI scan after 9 months showed no abnormalities (Figure 2).

Figure 2: MRI image 3D T1 sequence after gadolinium injection without abnormalities after 9 months of anticoagulant therapy

3. DISCUSSION

UC is an idiopathic IBD secondary to a complex interaction of genetic and environmental risk factors [5]. It can be considered a multi-systemic disorder with diverse extra-intestinal symptoms. Neurological complications are diverse, rare and often severe. Cerebral venous thrombosis (CVT) is a rare cerebrovascular event associated with UC, with a high

mortality risk. It has been reported that 0.5-6.4% of UC patients develop CVT complications at some point during the course of their disease [6,7]. Typically, CVT occurs in young UC patients, with a mean age of less than 29 years [8]. This finding shows that patients with CVT and UC as a comorbidity are significantly younger than those with CVT without UC. The pathophysiology of UC-related CVT is multifactorial and remains unknown. Excessive inflammation during the UC flare is a serious condition that predisposes to thrombosis and greatly increases the risk of venous thromboembolic events [9].

UC-induced hypercoagulability and hypofibrinolysis are key risk factors for CVT. Reduced levels of protein C, protein S and antithrombin, combined with elevated levels of fibrinogen and factor VIII, represent the hypercoagulable state. The hypofibrinolytic state is caused by endothelial dysfunction, platelet abnormalities with increased PAI-1 and lipoproteins [10].

Thrombocytosis and anemia have also been associated with an increased risk of CVT in UC patients. Among these, severe iron-deficiency anemia has been identified as an important risk factor for CVT in a previous study [11], as was the case of our patient who presented with severe anemia at 5.7 g/dl associated with significant thrombocytosis at 800,000 elements/mm³.

Furthermore, hospitalization, corticosteroid therapy and IBD-related surgery have all been identified as significant risk factors for venous thromboembolic events in IBD patients [12].

The clinical symptoms of CVT differ from patient to patient, depending on the site of thrombosis. Clinical manifestations include headache, uni or bilateral paresis, generalized or focal seizures and encephalopathy. Headache is the most common symptom of venous sinus thrombosis, described in 89% of patients [13]. Seizures are also common in CVT patients, reported in around 40% [13]. In addition, focal neurological symptoms may reveal the presence of venous infarction and hemorrhagic complication, which have been reported in over a third of patients [13]. In our patient, CVT was revealed by intense headache, photophobia, a febrile tonic-clonic convulsive seizure, with sensory deficit of all 4 limbs with paresthesia and left facial paralysis.

Neuroimaging is fundamental to the diagnosis of CVT. Although non-contrast cranial CT has relative sensitivity, it remains a useful technique for ruling out other diagnoses such as hemorrhagic or ischemic stroke. MRI and angiography should be performed to provide accurate visualization of the thrombus in order to confirm CVT [14]. The superior sagittal sinus and lateral sinus are the most frequent locations of CVT. In our case, cerebral MRI confirmed the diagnosis of CVT, revealing venous thrombosis of the superior longitudinal sinus and right lateral sinus, responsible for an oedemato-hemorrhagic remodelling.

The management of CVT in UC patients is based on dissolving the thrombus and preventing its spread. A low-molecular-weight anticoagulant or unfractionated heparin is recommended. Anticoagulant therapy in UC patients does not increase mucosal bleeding [15].

Parenteral anticoagulation is continued with oral vitamin K Antagonists (VKA) for 6 months to 1 year [16].

When a venous thromboembolic event is caused by a major transient risk factor, the risk of recurrence is low once the risk factor has disappeared, and long-term anticoagulation is not justified. If a major risk factor persists (e.g. cancer), the risk remains high as long as the factor is present, and anticoagulation should therefore be continued [2].

The efficacy and safety of long-term anticoagulation therapy in CVT with UC remain uncertain. The European Stroke Organization (ESO) recommends continuing anticoagulation for three months if CVT is due to a transient risk factor (e.g. pregnancy, dehydration, mechanical precipitants and medication) and for 6 to 12 months in patients with idiopathic CVT. On the other hand, these ESO guidelines recommend that anticoagulant therapy can be continued indefinitely in patients with recurrent CVT or CVT with severe thrombophilia. This severe thrombophilia is usually associated with homozygous mutations of prothrombin G20210 A; homozygous mutation of factor V Leiden; deficiencies of protein C, protein S or antithrombin; combined thrombophilia defects; or antiphospholipid syndrome [18]

The prognosis of CVT tends to be more critical in patients with UC. This may be due to delayed diagnosis and reluctance to initiate anticoagulant therapy in those at high risk of gastrointestinal bleeding. Patients who did not receive heparin therapy were at highest risk of death [17]. The American College of Gastroenterology recommends preventive anticoagulation for hospitalized patients to avoid venous thromboembolic events in active IBD. According to Olivera PA et al, thromboembolic prevention should be administered to all hospitalized IBD patients, whatever the cause, and maintained throughout hospitalization. Prolonged prevention after hospital discharge should only be considered for patients with major risk factors for venous thromboembolic events. Outpatient prevention should be considered for patients with active disease and risk factors for venous thromboembolism [2]. In addition, they recommend screening for risk factors of venous thromboembolism, investigation and correction of cardiovascular risk factors, smoking cessation, folate supplementation in patients treated with methotrexate to avoid hyperhomocysteinemia, and limiting exposure to corticosteroids [2].

4. CONCLUSION

Cerebral venous sinus thrombosis (CVST) is a rare complication of IBD. The risk is essentially related to disease activity and the presence of risk factors for venous thromboembolism. Its prognosis is **poor**, given the risk of death and neurosensory sequelae. It is therefore crucial that the prevention of these complications be fully integrated into the overall management of these patients, and deep remission should be the therapeutic target in order to minimize the risk of these events.

REFERENCES

1. Fumery M, Xiaocang C, Dauchet L, et al. Thromboembolic events and cardiovascular mortality in inflammatory bowel diseases: a metaanalysis of observational studies. *J Crohns Colitis* 2014;8 : 469-79.
2. Olivera PA, Zuily S, Kotze PG et al. International consensus on the prevention of venous and arterial thrombotic events in patients with inflammatory bowel disease. *Nat Rev Gastroenterol Hepatol*. 2021;27:1-17
3. Andrade AR, Barros LL, Azevedo MF, Carlos AS, Damião AO, Sipahi AM, Leite AZ: Risk of thrombosis and mortality in inflammatory bowel disease. *Clin Transl Gastroenterol*. 2018, 9:142. 10.1038/s41424-018-0013-8
4. Taous A, Berri MA, Lamsiah T, Zainoun B, Ziadi T, Rouimi A: Cerebral venous thrombosis revealing an ulcerative colitis. *Pan Afr Med J*. 2016, 23:120. 10.11604/pamj.2016.23.120.9186
5. C. N. Bernstein, J. F. Blanchard, D. S. Houston, and A. Wajda, "The incidence of deep venous thrombosis and pulmonary embolism among patients with inflammatory bowel disease: a population-based cohort study," *Thrombosis & Haemostasis*, vol. 85, no. 3, pp. 430–434, 2001.
6. S. Standridge and E. de los Reyes, "Inflammatory bowel disease and cerebrovascular arterial and venous thromboembolic events in 4 pediatric patients: a case series and review of the literature," *Journal of Child Neurology*, vol. 23, no. 1, pp. 59–66, 2008.
7. A. Taous, M. A. Berri, T. Lamsiah, B. Zainoun, T. Ziadi, and A. Rouimi, "Cerebral venous thrombosis revealing an ulcerative colitis," *The Pan African medical journal*, vol. 23, Article ID 120, 2016.
8. A. H. Katsanos, K. H. Katsanos, M. Kosmidou, S. Giannopoulos, A. P. Kyritsis, and E. V. Tsianos, "Cerebral sinus venous thrombosis in inflammatory bowel diseases," *QJM*, vol. 106, no. 5, pp. 401–413, 2013.
9. D Kohoutova, P Moravkova, P Kruzliak, J. Bures Thromboembolic complications in inflammatory bowel disease *J Thromb Thrombolysis*, 39 (2015), pp. 489-498, 10.1007/s11239-014-1129-7
10. S Danese, A Papa, S Saibeni, A Repici, A Malesci, M. Vecchi Inflammation and coagulation in inflammatory bowel disease: the clot thickens *Am J Gastroenterol*, 102 (2007), pp. 174-186, 10.1111/j.1572-0241.2006.00943.x
11. E. Stolz, J. M. Valdueza, M. Grebe et al., "Anemia as a risk factor for cerebral venous thrombosis? An old hypothesis revisited," *Journal of Neurology*, vol. 254, no. 6, pp. 729–734, 2007.
12. EM DeFilippis, E Barfield, D Leifer, A Steinlauf, BP Bosworth, EJ Scherl, et al. Cerebral venous thrombosis in inflammatory bowel disease *J Dig Dis*, 16 (2015), pp. 104-108, 10.1111/1751-2980.12212
13. J. M. Ferro, P. Canhao, J. Stam, M.-G. Bousser, and F. Barinagarrementeria, "Prognosis of cerebral vein and dural sinus thrombosis," *Stroke*, vol. 35, no. 3, pp. 664–670, 2004.
14. G Saposnik, F Barinagarrementeria, RD Brown Jr, CD Bushnell, B Cucchiara, M Cushman, et

al.Diagnosis and management of cerebral venous thrombosis: a statement for healthcare professionals from the American Heart Association/American Stroke Association Stroke, 42 (2011), pp. 1158-1192, 10.1161/STR.0b013e31820a8364

15. T Tsujikawa, M Urabe, H Bamba, A Andoh, M Sasaki, S Koyama, et al.Haemorrhagic cerebral sinus thrombosis associated with ulcerative colitis: a case report of successful treatment by anticoagulant therapy J Gastroenterol Hepatol, 15 (2000), pp. 688-692, 10.1046/j.1440-1746.2000.02190.x

16. JM Ferro, MG Bousser, P Canhão, JM Coutinho, I Crassard, F Dentali, et al. European Stroke Organization guideline for the diagnosis and treatment of cerebral venous thrombosis—endorsed by the European Academy of Neurology Eur Stroke J, 2 (2017), pp. 195-221, 10.1177/2396987317719364

17. RJ Nudelman, DG Rosen, E Rouah, G. Verstovsek Cerebral sinus thrombosis: a fatal neurological complication of ulcerative colitis Patholog Res Int, 2010 (2010),

18. J. M. Ferro, M. G. Bousser, P. Canhão et al., “European Stroke Organization guideline for the diagnosis and treatment of cerebral venous thrombosis - endorsed by the European Academy of Neurology,” European Journal of Neurology, vol. 24, no. 10, pp. 1203–1213, 2017.

UNDER PEER REVIEW