

# Expert perspectives on the clinical use of steroids for various ocular inflammatory conditions in Indian settings

## ABSTRACT

**Background:** Although there were clinical studies available regarding the usage of steroids, there were lack of data from clinician's perspectives. This survey was intended to gather expert perspectives regarding the prescription practice and clinical use of steroids, including specific types and their applications in various inflammatory ocular conditions, as well as in post-cataract surgeries.

**Methods:** This cross-sectional study comprised of 26 multiple-response questionnaires about expert perspectives on steroid prescription practices for ocular conditions and post-cataract surgeries. The survey also collected data on cataract surgery frequency, geographic distribution of cataract development, gender prevalence, and awareness of ocular health in rural and urban populations. Data analysis was conducted using descriptive statistics.

**Results:** The study involved 103 ophthalmic experts in India and majority of the clinicians (36.89%) conducted over 50 cataract surgeries per month, with cataract development reported as most prevalent in suburban (37%) and urban (35%) areas. Most respondents (82.52%) indicated equal prevalence of cataract in both genders, with a higher occurrence observed in patients aged 51-60 years (49.51%). Prednisolone was the preferred steroid after cataract surgery among 64% of the clinicians and for treating anterior (53%) and posterior (64%) segment inflammatory conditions. A substantial proportion of clinicians (46.6%) reported starting non-steroidal anti-inflammatory (NSAID) therapy along with steroids in 21-30% of their patients for managing post-operative inflammation. Most of the experts recommended nepafenac (85%) as the most effective medication for controlling cystoid macular edema (CME).

**Conclusion:** The study highlighted the use of prednisolone as the preferred steroid after cataract surgery and for various inflammatory conditions. Loteprednol emerged as a favored choice for ocular surface inflammation and allergy-associated conditions, while nepafenac was recommended for controlling CME.

*Keywords: Steroids, prednisolone, cataract surgery, cystoid macular edema*

## 1. INTRODUCTION

Cataract is a significant cause of global blindness [1]. The impact of cataract extends beyond visual impairment, contributing to increased risks of dementia, falls, road accidents, reduced quality of life, and increased mortality rates, especially in elderly. The age-standardized prevalence and disability-adjusted life years (DALYs) peaked in 2017 and 2000, with prevalence at 1283.53 and DALYs at 94.52 per 100,000 populations. In 2019, Southeast Asia exhibited the highest age-standardized DALY rates due to cataract-related blindness [2].

The prevalence of unoperated cataracts among individuals aged 60 years and older was estimated to be 58% in North India and 53% in South India (P=0.01) [3]. Ophthalmologists reported conducting between 0 to 5000 cataract surgeries in a typical year before the

lockdown, with an average of 739.77 procedures in Indian settings [4]. However, with regard to the impact of inflammatory eye diseases on visual impairment and blindness, there was no adequate data from current global prevalence studies [5].

Due to the anti-edematous, anti-inflammatory, and anti-neovascularization characteristics, corticosteroids are considered as the mainstay of treatment for diverse ocular conditions, including those affecting the ocular surface, anterior segment, and posterior segment. Prednisolone, prednisolone acetate, dexamethasone, triamcinolone acetonide, fluocinolone acetonide, and loteprednol etabonate are among the most commonly used ophthalmic corticosteroids [6].

Corticosteroids are considered essential agents following cataract surgery due to their potent and broad spectrum of action. They effectively suppress the inflammatory response and help prevent complications by acting as potent inhibitors of the phospholipase A2 enzyme, which regulates the synthesis of arachidonic acid, a precursor to various inflammatory mediators. Prednisolone acetate is a commonly prescribed corticosteroid for the management of ophthalmic conditions. It can suppress the migration of inflammatory cells into the site of inflammation and inhibit the production of cytokines involved in the inflammatory process. These mechanisms collectively reduce inflammation, swelling, and redness associated with various ocular conditions [7]. Although there were clinical studies available, there were lack of data from clinician's perspectives. So, the current cross-sectional survey aims to collect expert opinion on steroid prescription practices and their clinical applications in treating various inflammatory ocular conditions, along with their use in post-cataract surgery care.

## **2. MATERIALS AND METHODS**

A cross sectional, multiple-response questionnaire based survey was carried out among ophthalmologists specialized in treating various inflammatory ocular conditions, and post-cataract surgeries in the major Indian cities from June 2023 to December 2023.

### **2.1 Questionnaire**

The questionnaire booklet titled IDEA (Inflammatory Disorders in Eye: An Indian Perspective Study) study was sent to the ophthalmologists who were interested to participate. The IDEA study questionnaire consisted of 26 questions addressing current feedback, clinical observations, and specialists' experiences related to prescription practices and the clinical use of steroids, including specific types, their applications in various inflammatory ocular conditions, and post-cataract surgeries.

### **2.2 Participants**

An invitation was sent to leading ophthalmologists in managing various inflammatory ocular conditions, and post-cataract surgeries in the month of March 2023 for participation in this Indian survey. About 103 ophthalmologists from major cities of all Indian states representing the geographical distribution shared their willingness to participate and provide necessary data. Ophthalmologists were requested to complete the questionnaire without discussing with peers.

### **2.3 Statistical Methods**

Descriptive statistics were employed for data analysis. Categorical variables were presented as percentages to offer a clear understanding of their distribution. The frequency and corresponding percentage of each variable were used to depict their distribution. Microsoft

Excel 2013 (version 16.0.13901.20400) was utilized to create graphs and pie charts, aiding in visualizing the distribution of categorical variables.

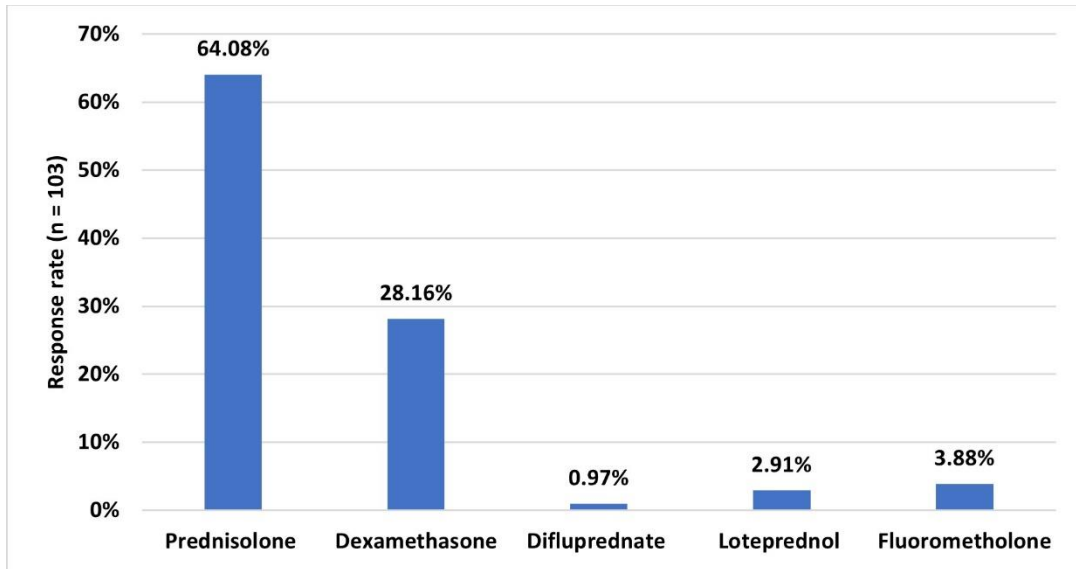
### 3. RESULTS

The survey involved 103 experts, with the majority (36.89%) reporting conducting >50 cataract surgeries per month on average in routine clinical practice. Approximately 37% and 35% of the clinicians reported cataract development as most prevalent in suburban and urban areas, respectively. Majority of the respondents (82.52%) indicated that cataract affects both men and women equally in their clinical practice. Nearly half of the experts stated that cataract was more common in patients aged 51-60 years in routine settings (49.51%). Majority of the clinicians (85.44%) opined that cataract development was most prevalent among individuals with no specific predisposing factors. Approximately 51% of the clinicians reported moderate awareness among rural populations regarding cataract, whereas 52% reported that urban populations were mostly aware of the condition.

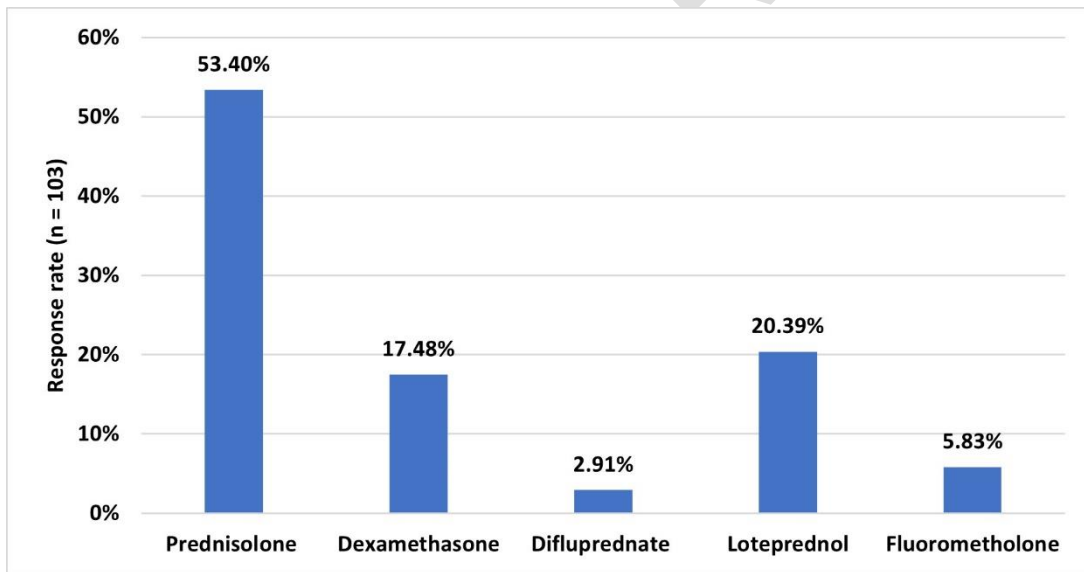
Approximately 34% of the clinicians reported prescribing steroids to manage ocular inflammatory conditions in 31-40% of their patients, while a similar proportion of experts (33.01%) reported prescribing to 21-30% of patients in routine settings (Table 1). According to 64% of clinicians, prednisolone was the preferred steroid after cataract surgery (Fig. 1). Approximately 53% of clinicians indicated prednisolone as the preferred steroid for anterior segment inflammatory conditions, and nearly 64% reported prednisolone as the top choice for posterior segment inflammatory conditions (Fig. 2 and 3).

**Table 1: Distribution of response to proportion of patients prescribing steroids to manage ocular inflammatory conditions in routine settings**

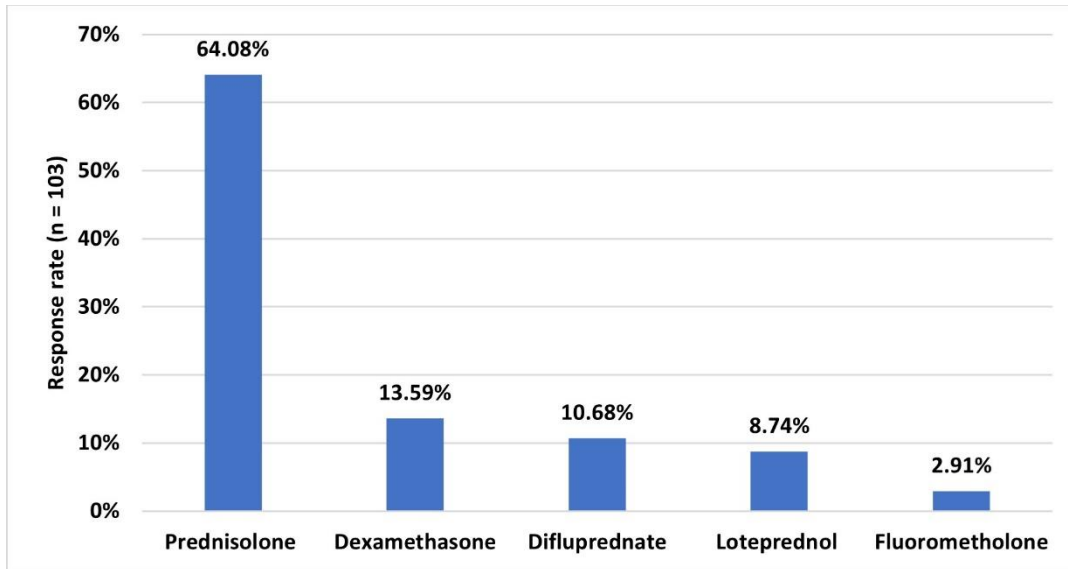
Percentage of patients	Response (n = 103)
<10%	7 (6.8%)
11-20%	25 (24.27%)
21-30%	34 (33.01%)
31-40%	35 (33.98%)
70%	1 (0.97%)
>70-80%	1 (0.97%)



**Fig. 1: Distribution of response to preferred steroid after cataract surgery in routine clinical settings**



**Fig. 2: Distribution of response to preferred steroid for anterior segment inflammatory condition**



**Fig. 3: Distribution of response to preferred steroid for posterior segment inflammatory condition**

According to 39% of the respondents, loteprednol was the preferred choice for ocular surface inflammatory conditions (Table 2). Approximately 42% cited transient burning and stinging upon instillation as the most common ocular side effect of prednisolone acetate ophthalmic suspension. Majority of clinicians (68.93%) believed that particle size affects the efficacy of prednisolone acetate.

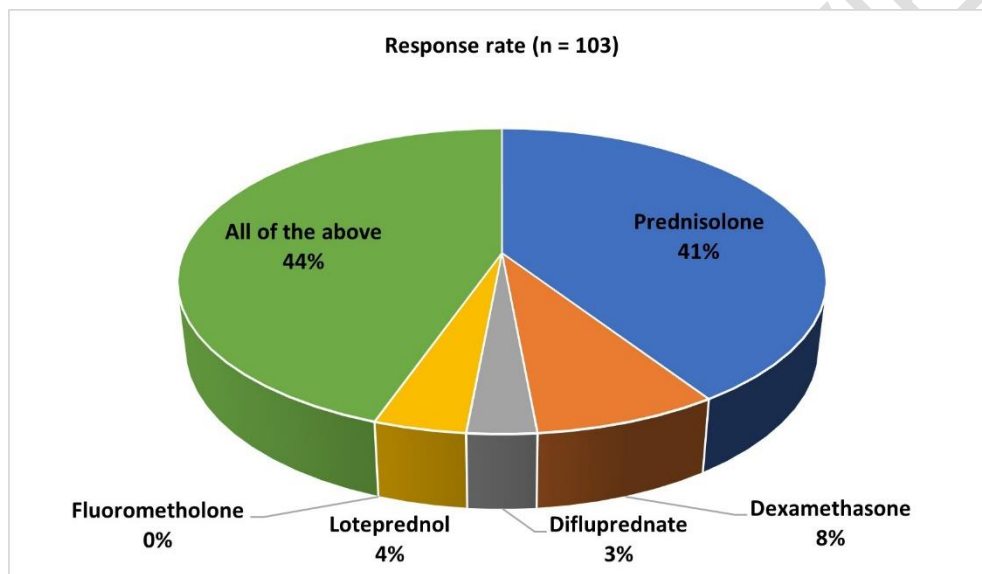
**Table 2: Distribution of response to preferred steroid for managing ocular surface inflammatory condition in routine settings**

Preferred steroid	Response (n = 103)
Prednisolone	20 (19.42%)
Dexamethasone	17 (16.5%)
Difluprednate	1 (0.97%)
Loteprednol	40 (38.83%)
Fluorometholone	25 (24.27%)

According to 41% of the respondents, prednisolone was ranked highest in terms of potency (Table 3). A significant percentage of clinicians (49.51%) reported prescribing steroids to <10% of dry eye patients, and majority of the clinicians (43.69%) reported <10% of patients as steroid responders to prednisolone acetate. Around 51% preferred using a steroid and antibiotic fixed-dose combination after cataract surgery. Majority of the experts favored the use of moxifloxacin + dexamethasone (69.9%) in routine practice. Approximately 48% stated loteprednol as the preferred steroid for treating inflammation associated with allergy (Fig. 4).

**Table 3: Distribution of response to ranking of steroids in terms of potency**

Ranking of steroid potency	Response (n = 103)
Prednisolone	42 (40.78%)
Dexamethasone	8 (7.77%)
Difluprednate	3 (2.91%)
Loteprednol	4 (3.88%)
Fluorometholone	0 (0%)
All of the above	46 (44.66%)



**Fig. 4: Distribution of response to preferred steroid for allergy-associated inflammation**

Majority of the clinicians (59.22%) preferred steroid therapy for >15 days after cataract surgery. A substantial proportion of clinicians (46.6%) reported starting non-steroidal anti-inflammatory (NSAID) therapy along with steroids in 21-30% of their patients for managing post-operative inflammation. Most of the experts recommended nepafenac (85%) as the most effective medication for controlling cystoid macular edema (CME) (Table 4). Majority of the clinicians (60.19%) preferred using steroids with anti-infective agents in the management of inflammation associated with allergies.

**Table 4: Distribution of response to the most effective medication for controlling cystoid macular edema**

Medications	Response (n = 103)
Nepafenac	88 (85.44%)

<b>Bromfenac</b>	10 (9.71%)
<b>Flurbiprofen</b>	5 (4.85%)

#### 4. DISCUSSION

The current survey provides valuable real-world data on prescription practices and clinical use of steroids for post-cataract surgery care and ocular inflammation conditions in Indian settings. This information may contribute to enhancing patient care and advancing ophthalmic practice. The survey indicated that cataract surgeries are performed at a high volume, with most clinicians conducting over 50 surgeries per month. This highlights the significant burden of cataract-related visual impairment in the Indian population.

A cross-sectional study by Sobti et al., conducted in a rural area of North India, concluded that despite the availability of safe and effective cataract surgical techniques, current surgical capacities are insufficient to meet the existing needs for cataract surgery. The burden of cataract continues to rise annually due to a backlog of patients awaiting surgery and an increasing number of cases attributed to longer life expectancy. The researchers noted that the cataract surgical coverage was 43.20%, with 29.31% coverage for those with unilateral cataract and 50.45% for those with bilateral cataract. Approximately half of the cataract surgeries were performed in private facilities, 41.35% in government facilities, and the remaining 8.65% in eye camps [8]. Dandona et al. also emphasized that only a small fraction of individuals benefits from cataract surgery in India. With the current surgical capacity and improved attention to the quality of eye care, it should be possible to triple the number of individuals who can have their blindness averted through cataract surgery in India [9].

The current survey revealed a relatively equal prevalence of cataract between suburban and urban areas, as well as between genders. The observation that cataracts were more common in patients aged 51-60 years was noteworthy, highlighting the age-related nature of this condition. In line with these findings, Singh et al. noted that there was no significant difference in the prevalence of cataract between men and women. The researchers identified increasing age and HbA1c as risk factors for any cataract in the older rural population. In the urban group, age and lower socioeconomic status were identified as risk factors. However, a statistically significant difference was observed when comparing the prevalence of cataract and its subtypes between rural and urban populations [10].

Prednisolone emerged as the preferred steroid post-cataract surgery and for managing both anterior and posterior segment inflammatory conditions. This reflects a consensus among clinicians on the efficacy and safety profile of prednisolone in these settings. Malik et al. compared different topical NSAIDs with steroid drops for managing post-cataract surgery inflammation. Prednisolone 1% was found to be more effective than NSAIDs in reducing intraocular inflammation, as indicated by decreased anterior chamber cells and flare [11]. An optical coherence tomography-based study by Panda et al. compared the therapeutic efficacy of difluprednate 0.05% versus prednisolone acetate 1% in controlling inflammation and macular edema following phacoemulsification. Both treatment groups showed comparable efficacy, with no significant differences observed between the groups in terms of pain score, conjunctival hyperemia, anterior chamber inflammation, central retinal thickness, cystoid macular edema, intraocular pressure, and best-corrected visual acuity after six weeks [12].

Robin G Stanley reported that 1% prednisolone acetate exhibits superior intraocular anti-inflammatory effects compared to other preparations. It has enhanced corneal penetration

and prolonged persistence in both the cornea and aqueous humor, leading to the attainment of high intraocular concentrations. This medication was preferred for treating uveitis, which involves inflammation inside the eye. Typically, it was administered 1–10 times daily into the affected eye, with dosing frequency adjusted based on the severity of the inflammatory condition [13].

Loteprednol was favored by the majority of respondents for managing ocular surface inflammatory conditions and allergy-associated inflammation, likely due to its lower propensity to cause side effects such as elevated intraocular pressure. Comstock and Sheppard reviewed twenty years of clinical experience in the use of loteprednol etabonate for inflammatory conditions of the anterior segment of the eye. The researchers concluded that loteprednol etabonate was recommended as a mainstay for topical therapy of a wide variety of ophthalmic conditions, including in post-operative patients during healing. It was recommended for both acute induction and chronic maintenance therapy with appropriate follow-up due to its versatility and safety [14].

The preference for steroid and antibiotic fixed-dose combinations after cataract surgery in the present survey reflected the standard practice of preventing post-operative infection and inflammation. A prospective interventional study by Vidyadevi et al. has corroborated the safety of fixed drug combinations of antibiotics and steroids. The study demonstrated that they do not cause raised intraocular pressure in approximately 97% of cases of small incision cataract surgery in the post-operative period and the treatment approach also improved patient compliance [15]. The use of NSAIDs alongside steroids for managing post-operative inflammation further underscores the comprehensive approach to optimizing patient outcomes. A systematic review and meta-analysis, based on 19 studies featuring a total of 3374 patients (3638 eyes), concluded that NSAIDs and the combination of NSAIDs with corticosteroids were both more effective in controlling inflammation compared to corticosteroids alone [16].

The increased preference noted in the current survey for nepafenac in managing CME highlights its efficacy and acceptance among clinicians as a first-line treatment option. A retrospective review of 22 eyes with cystoid macular edema, treated over six weeks to six months with nepafenac, showed significant improvements in various subtypes. Among eyes with uveitic CME, there was a notable mean reduction in retinal thickness of 227  $\mu\text{m}$  and an improvement in best-corrected visual acuity by 0.36 logMAR. Acute cases of pseudophakic CME responded well to nepafenac treatment, showing a mean reduction in retinal thickness of 134  $\mu\text{m}$  along with BCVA improvements in most cases [17]. A comparative prospective interventional randomized study El Gharbawy et al. demonstrated that the addition of topical nepafenac eye drops to topical steroid drops resulted in a significant reduction in pseudophakic macular edema following cataract surgery in high-risk eyes [18].

The current survey holds significant relevance as there was very limited real-world evidence from Indian settings on steroid use for managing inflammatory conditions and post-cataract surgery care. This survey provided crucial insights into prescription practices and clinical outcomes, which were essential for guiding treatment decisions and optimizing patient care. The primary strength of the study was the utilization of a carefully crafted and validated questionnaire to gather expert data. However, it was important to recognize that personal perspectives and preferences could have influenced the conclusions, potentially introducing bias. Therefore, it was critical to interpret the results while keeping these limitations in mind. Furthermore, further research was necessary to confirm and broaden the scope of the current survey findings.

## 4. CONCLUSION

This study underscored the widespread clinical use of prednisolone for post-cataract surgery and inflammatory conditions, and the preference for loteprednol for managing ocular surface inflammation and allergies. Additionally, most clinicians recommended nepafenac for managing CME, highlighting the diversity in prescription practices and preferences within Indian ophthalmic settings.

### Ethical Approval

The study was conducted after getting approval from Bangalore Ethics, an Independent Ethics Committee which was recognized by the Indian Regulatory Authority, Drug Controller General of India.

### Consent

A written informed consent was obtained from each clinicians before initiation of the study.

## REFERENCES

1. Lee CM, Afshari NA. The global state of cataract blindness. *Current Opinion in Ophthalmology*. 2017 Jan;28(1):98.
2. Fang R, Yu YF, Li EJ, Lv NX, Liu ZC, Zhou HG, et al. Global, regional, national burden and gender disparity of cataract: findings from the global burden of disease study 2019. *BMC Public Health*. 2022 Nov 12;22(1):2068.
3. Vashist P, Talwar B, Gogoi M, Maraini G, Camparini M, Ravilla R, et al. Prevalence of Cataract in an Older Population in India The India Study of Age-related Eye Disease. *Ophthalmology*. 2011 Feb 1;118:272-8.e1.
4. Bali J, Bali O, Sahu A, Boramani J, Senthil T, Deori N. State of the nation survey on cataract surgery in India. *Indian J Ophthalmol*. 2022 Nov;70(11):3812–7.
5. Clare G, Kempen JH, Pavésio C. Infectious eye disease in the 21st century-an overview. *Eye (Lond)*. 2024 Feb 14. Epub ahead of print. PMID: 38355671.
6. Gaballa SA, Kompella UB, Elgarhy O, Alqahtani AM, Pierscionek B, Alany RG, et al. Corticosteroids in ophthalmology: drug delivery innovations, pharmacology, clinical applications, and future perspectives. *Drug Deliv Transl Res*. 2021 Jun;11(3):866–93.
7. Puckett Y, Gabbar A, Bokhari AA. Prednisone. In: StatPearls [Internet]. Treasure Island (FL): StatPearls Publishing; 2024 [cited 2024 May 16]. Available from: <http://www.ncbi.nlm.nih.gov/books/NBK534809/>
8. Sobti S, Sahn B, Bala K. Surgical coverage of cataract in a rural area of north India: A cross-sectional study. *J Family Med Prim Care*. 2020 Aug 25;9(8):4112–7.

9. Dandona L, Dandona R, Anand R, Srinivas M, Rajashekar V. Outcome and number of cataract surgeries in India: policy issues for blindness control. *Clin Exp Ophthalmol*. 2003 Feb;31(1):23–31.
10. Singh S, Pardhan S, Kulothungan V, Swaminathan G, Ravichandran JS, Ganesan S, et al. The prevalence and risk factors for cataract in rural and urban India. *Indian Journal of Ophthalmology*. 2019 Apr;67(4):477.
11. Malik A, Sadafale A, Gupta YK, Gupta A. A comparative study of various topical nonsteroidal anti-inflammatory drugs to steroid drops for control of post cataract surgery inflammation. *Oman J Ophthalmol*. 2016;9(3):150–6.
12. Panda B, Nanda A, Swain S. Therapeutic Efficacy of Difluprednate 0.05% Versus Prednisolone Acetate 1% in Controlling Inflammation and Macular Oedema Following Phacoemulsification: An Optical Coherence Tomography-Based Study. *Cureus*. 2021 Apr 25;13:e14673.
13. Prednisolone Acetate - an overview. ScienceDirect Topics [Internet]. Available from: <https://www.sciencedirect.com/topics/medicine-and-dentistry/prednisolone-acetate> [cited on May 16, 2024].
14. Comstock TL, Sheppard JD. Loteprednol etabonate for inflammatory conditions of the anterior segment of the eye: twenty years of clinical experience with a retrometabolically designed corticosteroid. *Expert Opinion on Pharmacotherapy*. 2018 Mar 4;19(4):337–53.
15. Vidyadevi M, Anuradha A, Rashmi G, Shilpa R, Nishath S. Safety of Fixed drug Combination in Post –Operative Cataract Patients, at Tertiary Care Centre – In South India. *Nepalese Journal of Ophthalmology*. 2017 Jun 20;9:24.
16. Haddad JE, Sabbakh NA, Macaron MM, Shaaban H, Bourdakos NE, Shi A, et al. NSAIDs and Corticosteroids for the Postoperative Management of Age-Related Cataract Surgery: A Systematic Review and Meta-analysis. *American Journal of Ophthalmology*. 2024 Apr 1;260:1–13.
17. Hariprasad SM, Akduman L, Clever JA, Ober M, Recchia FM, Mieler WF. Treatment of cystoid macular edema with the new-generation NSAID nepafenac 0.1%. *Clin Ophthalmol*. 2009;3:147–54.
18. El Gharbawy SA, Darwish EA, Abu Eleinen KG, Osman MH. Efficacy of addition of nepafenac 0.1% to steroid eye drops in prevention of post-phaco macular edema in high-risk eyes. *European Journal of Ophthalmology*. 2019 Jul 1;29(4):453–7.
19. Mohamed AI, Nassar E-SA, Elsoht RM, Shaheen MA. Ocular Surface Alterations Related to Cataract Surgery. *J. Adv. Med. Med. Res.* [Internet]. 2023 Feb. 2 [cited 2024 May 18];35(2):50-6. Available from: <https://journaljamr.com/index.php/JAMMR/article/view/4944>
20. Jeneral AR. Clinical Outcomes of Surgery for Age-related Cataract with Intraocular Lens Implantation in Two Hospitals in North-Central Nigeria. *Ophthalmol. Res. Int. J.*

[Internet]. 2023 Jun. 27 [cited 2024 May 18];18(4):1-10. Available from:  
<https://journalor.com/index.php/OR/article/view/390>

21. Abdalla Elsayed ME, Ahmad K, Al-Abdullah AA, Malik R, Khandekar R, Martinez-Osorio H, Mura M, Schatz P. Incidence of intraocular lens exchange after cataract surgery. Scientific reports. 2019 Sep 9;9(1):12877.

UNDER PEER REVIEW