

**INSIGHTS INTO MALE BREAST CANCER: A CLINICOPATHOLOGICAL STUDY OF CASES IN
ASSAM**

ABSTRACT

BACKGROUND

Male Breast Cancer is a rare disease, which accounts for less than 1% of breast cancer. Common risk factors are radiation exposure and estrogen therapy whereas the commonest presentation is palpable breast lump. Triple assessment forms the basis of diagnosis. Modified Radical Mastectomy is the treatment of choice usually followed by adjuvant chemotherapy.

AIMS: To evaluate the clinico-pathological and immunohistochemical characteristics of Male Breast Carcinoma

STUDY DESIGN: A retrospective multicentric observational study

PLACE AND DURATION OF STUDY: A duration of 18 months from January 2022 to June 2023 in two tertiary level hospitals of Assam

METHODOLOGY

A retrospective multicentric observational study is performed in Assam. The patients are ascertained from hospital admission register over a period of 18 months from January 2022 to June 2023. The patients contact numbers are retrieved and data are collected along with details of recurrence and death. The associations between clinical factors, pathological status and treatment choice are reviewed in cross-tabulation form.

RESULTS

Nine patients of MBC are studied over a period of 18 months. The median age of presentation is 45 years. The most common presentation is palpable lump around nipple areolar complex. Cases of fungating mass are also seen. On USG analysis, 66% patients have BIRADS IV lesion with axillary lymphadenopathy in 89% patients. HPE reports suggested Invasive Ductal Carcinoma in 89% cases. ER positivity is observed in 80%, PR positivity 70% and Her2 neu positivity in 20% cases. Treatment options include modified radical mastectomy along with chemotherapy and radiotherapy. Overall mortality is found to be 20%.

CONCLUSION

Male Breast Cancer is found to be more aggressive than Female Breast Cancer. The important prognostic factors are tumour size, nodal involvement, histological grade and hormone receptor status which is similar to female breast cancer. Treatment options are similar to that of FBC. Breast carcinoma awareness in the community, early detection and timely management of the disease are the keys for improvement of its prognosis.

KEY WORDS

Male breast cancer, Clinico-pathological, Immuno-histopathological, BIRADS, Modified radical mastectomy

INTRODUCTION:

Fewer than 1% of all breast cancer occur in men and 0.2% of cancer deaths in men¹⁻⁶. In adult males, breast tissue is rudimentary, 2 cm in diameter lying deep to areola and extending to the areolar edges².

Common risk factors associated with development of breast cancer in males are increasing age, family history, genetic predisposition (BRCA 2 mutation), radiation exposure and estrogen therapy¹⁻⁸. Others are testicular feminising syndrome, Klinefelter's syndrome (XXY), infertility, obesity, cryptorchidism and epididymorchitis¹⁻¹⁰. The role of interleukins in the proliferation and migration of breast cancer along with induction of angiogenesis and tumour growth have been established and are being meticulously studied over the recent years¹¹⁻¹⁵. The commonest clinical presentation of breast cancer is a palpable breast lump with or without pain with no gender variation¹⁻¹⁰. Other presentations are axillary swelling, nipple retraction, breast ulceration, fungating mass, bleeding from nipple and nipple discharge¹⁻¹². Breast cancer can also emerge as a cutaneous manifestation either as skin metastases or as a direct extension of the tumour or indirectly as a paraneoplastic disease¹⁶⁻¹⁹. Nodules are the most common presentation whereas erythema gyratum repens, acquired ichthyosis, dermatomyositis (DM), multicentric reticulohistiocytosis and acquired hypertrichosis lanuginosa have been identified as paraneoplastic cutaneous dermatoses¹⁶⁻¹⁹. Cutaneous metastases made a presenting symptom in 3% of the male breast carcinoma cases and the most prevalent location is the pectoral wall as studied by Mihailov R, Tatu AL, Niculet E, et al in A narrative review of cutaneous manifestations and imaging landmarks of breast cancer

Male breast cancer shares the same staging and same prognosis as female breast cancer^{2-8, 11-14}. Triple assessment forms the basis of diagnosis in male breast cancer also. Modified Radical Mastectomy is the treatment of choice¹⁻⁹ and with the aid of chemotherapy, the prognosis shifts to a better side in multiple fold. Adjuvant Tamoxifen is considered for hormone receptor positive male breast cancer¹⁻⁴

MATERIALS AND METHODS:

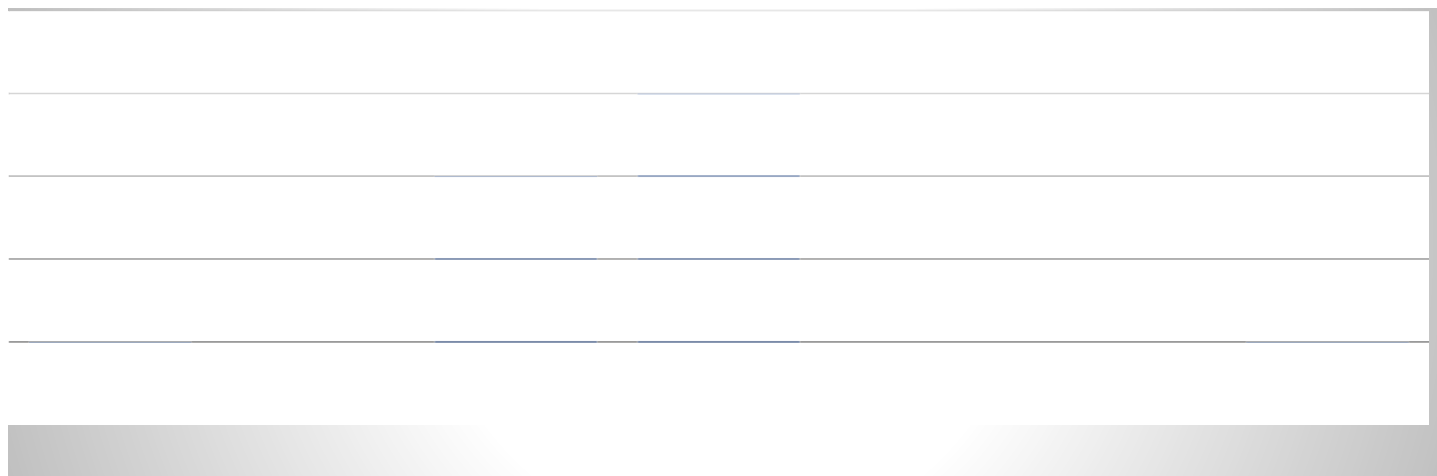
The objective of the study is to evaluate the clinicopathological and immunohistochemical characteristics of breast carcinoma in males. Two tertiary level hospitals of Assam are chosen for data collection (Assam Medical College and the Gauhati Medical College representing Upper Assam and Lower Assam respectively). All clinically suspected and histopathologically confirmed cases of male breast carcinoma are included in this study.

Since male breast carcinoma constitutes <1% of all breast carcinoma, a multicentric retrospective observational study is performed to understand the clinico-pathological and immuno-histochemical scenario of the disease in men. The patients are ascertained from hospital admission registration records over a period of 18 months from January 2022 to June 2023. Data regarding patient history, presenting signs and symptoms, risk factors, family history, primary tumour pathology, treatment options, surgical treatment, pre and post-surgical treatment along with the details of recurrences are ascertained from the master ticket recovered from the MRD Office. The patients contact numbers are retrieved and they are enquired about their current difficulties and disease status and informed consent taken during their follow up.

RESULTS AND DISCUSSION:

In the present study, patient age ranges from 18 to 84 years and the median age of presentation is 45 years. Age distribution is depicted in chart form in Figure 1.

FIGURE 1 : Table showing age distribution of patients



8 men are married at the time of presentation and all of them have offsprings. Clinical gynaecomastia is evidenced in 2 cases out of which 1 patient reported bilateral gynaecomastia. No features of hypoandrogenism or hyperestrogenism or infertility is elicited by any of the cases. 2 patients gave history of trauma to the chest and breast tissue. There is occupational exposure to chemicals in 33% cases (petroleum products) but no history of radiation exposure found. There is no past history of radiotherapy or chemotherapy. Family history remains insignificant in all of the cases.

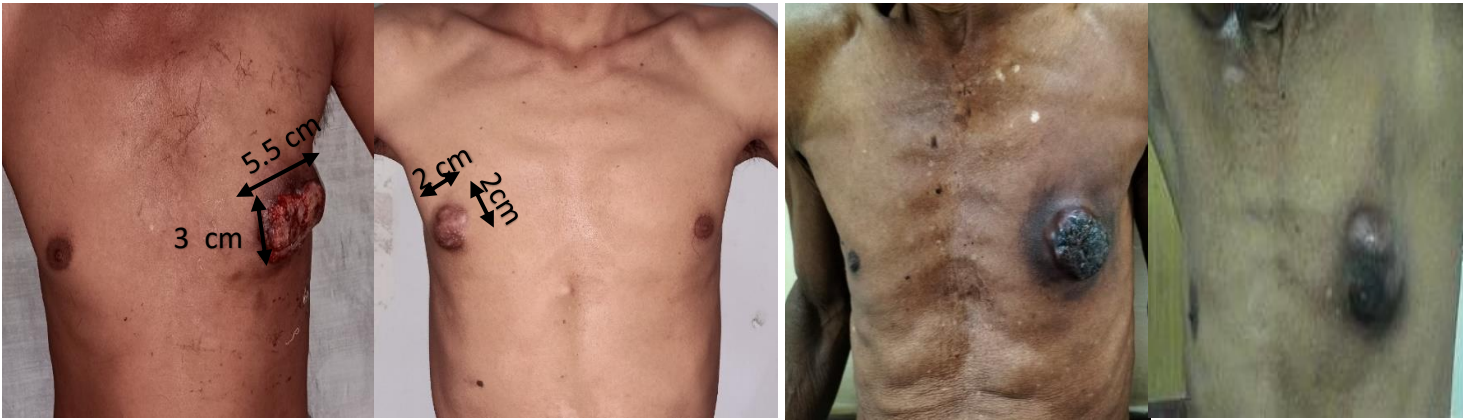In the study, four out of nine cases presented with palpable swelling around the nipple areolar complex which was associated with pain whereas one patient present with swelling without pain or discharge. Three cases presented with a fungating mass of breast. One patient presented with axillary swelling as the chief complaint. There were no asymptomatic patients or patients presenting with only pain of the breast or any precancerous changes. There are also no cases of breast cancer in the form of cutaneous manifestation. Right sided breast involvement is evidenced in 67% cases (n=6). Clinical presentation is depicted in table form in Figure 2.

Fungating Mass with bleeding	2	22%
Axillary Swelling	1	11%
Ulcerated lesion	0	0%

NAC : Nipple Areolar Complex

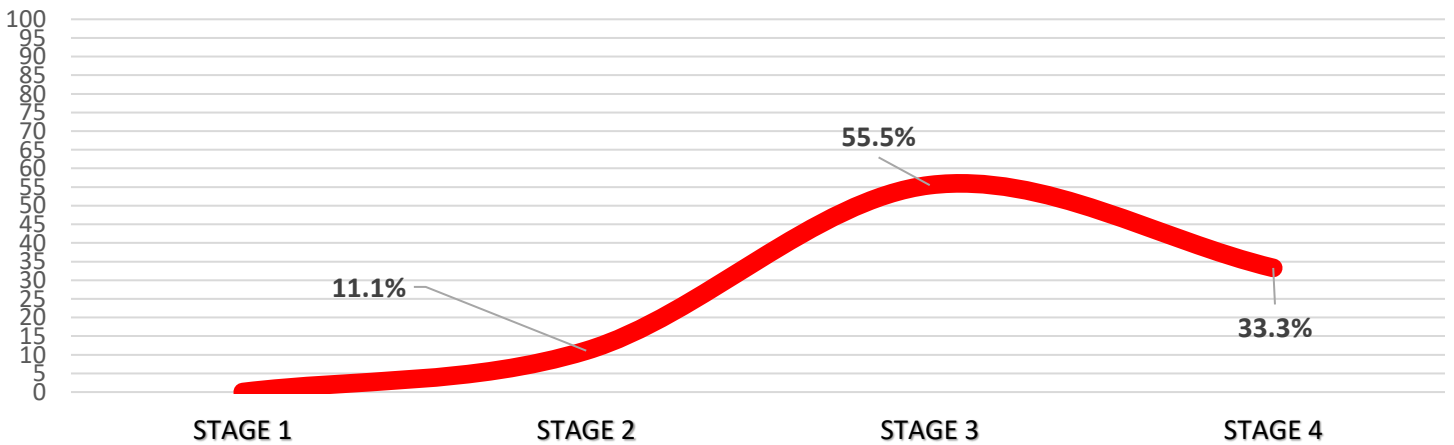
FIGURE 2 : Table showing various clinical presentation of the patients under study

FIGURE 3: Pictures of the patients with male breast carcinoma under study



On preoperative clinical staging, 5 out of 9 patients presented in stage 3 of the disease. 3 patients, who were in stage 4, have already presented with metastasis on their first pursuit of medical care. Only one patient presented early with stage 2 disease. Clinical staging is depicted in chart form in Figure 4.

FIGURE 4: Chart showing clinical staging of the patients



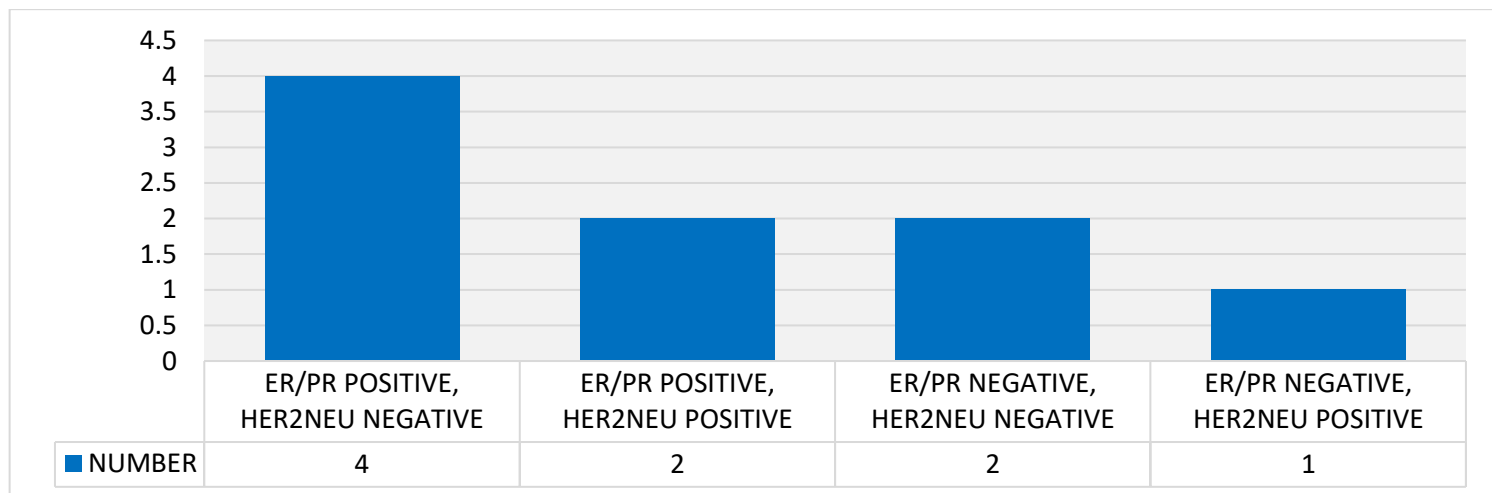
On analysis of USG reports, it is seen that 6 patients have BIRADS IV primary lesion. 2 patients presented with BIRADS score 3 who were under evaluation and later surgery was done after proper assessment. 1 patient presented with BIRADS V primary lesion. Axillary lymphadenopathy is evidenced in 88.88% patients(n=8) sonographically suggesting a high lymphovascular invasion of the disease. BIRADS scoring of the patients is depicted in table form in Figure 5.

FIGURE 5: Table showing BIRADS scoring of patients

	Number	Percentage
BIRADS 1	0	0.0
BIRADS 2	0	0.0
BIRADS 3	2	22.2%
BIRADS 4	6	66.6%
BIRADS 5	1	11.1%
BIRADS 6	0	0.0

Histopathological analysis suggested Invasive Ductal Carcinoma to be the most prevalent type seen in 8 out of 9 cases and 1 case presented as an Invasive Papillary Carcinoma. On immunohistochemical analysis, 4 subtypes are mainly encountered as depicted in chart, figure 6. It is seen that ER/PR positivity with Her2neu negative is the most common subtype and have a good prognosis until not metastasised. 2 patients have ER/PR/ Her2neu positive and 1 patient is her2neu enriched whereas 2 patients have a triple negative hormone receptor status. Immunohistochemistry is depicted in chart form in Figure 6.

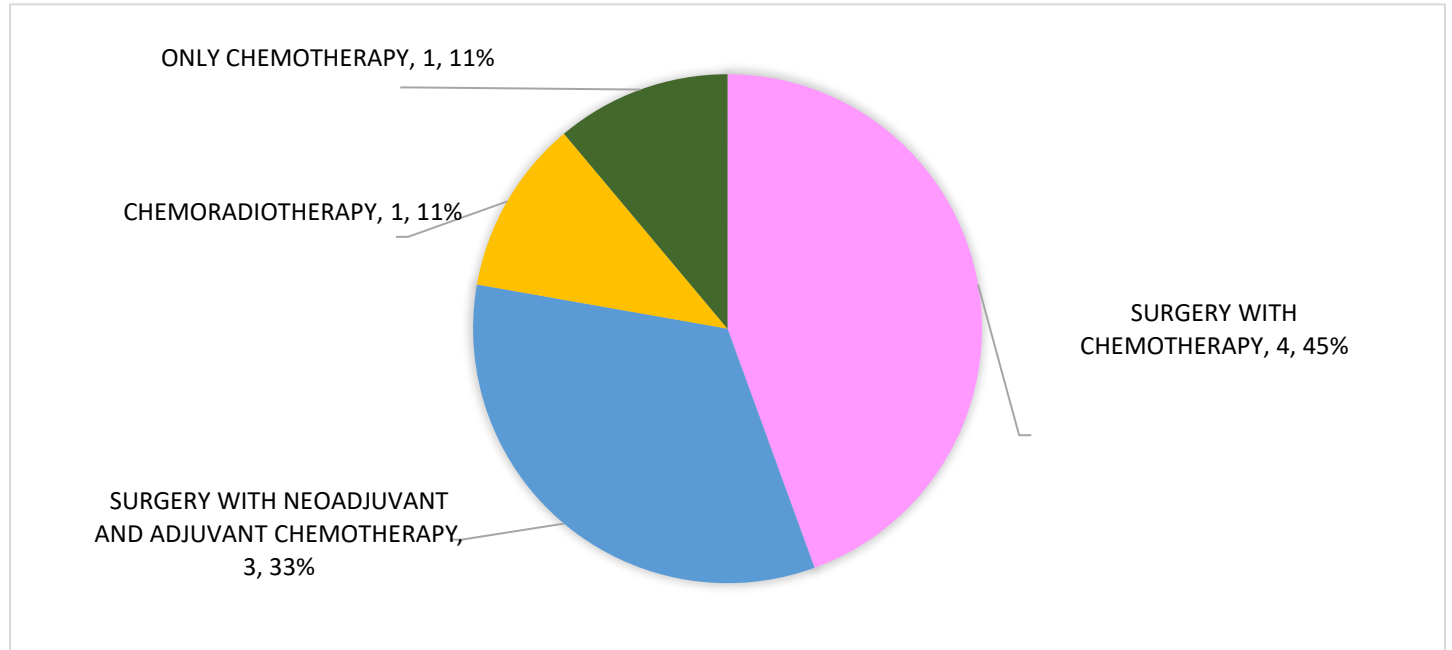
FIGURE 6: Chart depicting the 4 types of immunohistochemistry evidenced in the patients



In the present study, seven out of nine patients have undergone curative treatment in the form of Surgery. Six patients underwent Modified Radical Mastectomy and simple mastectomy was done on the youngest patient who presented in stage

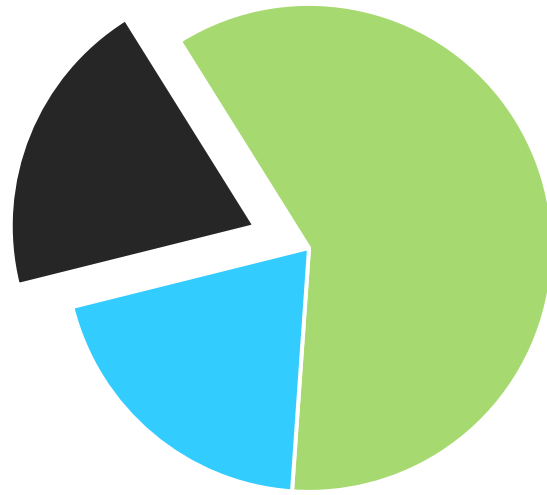2 of the disease. Surgery was followed by chemotherapy in four patients as the primary mode of treatment. Three other patients have received neoadjuvant chemotherapy followed by post-surgical chemotherapy. Two patients, who presented as a stage 4 breast cancer, have been receiving palliative treatment, one in the form of chemoradiation and another with chemotherapy only (without surgery). Modified Radical Mastectomy is performed in 88% cases with chemotherapy (CAF regimen) given in post-operative period of all cases. The treatment options are depicted in the form of pie chart in Figure 7.

FIGURE 7: Pie diagram showing treatment options received by the patients



Two patients out of nine (22.22%), have died within a period of 8 months of diagnosis who did not undergo surgical intervention. One patient is undergoing palliative treatment. Rest of the six patients are on regular follow ups after curative therapy. No recurrences or complications have been reported till date.

FIGURE 8: Pie chart depicting the outcome of patients



■ Patients died

■ Patients undergoing curative treatment

■ Patients undergoing palliative treatment

DISCUSSION:

Due to the rarity of the disease, information regarding etiology, risk factors, diagnosis, management and prognosis of male breast cancer are usually extrapolated from our knowledge of female breast cancer. In our study, majority of the cases lie within the range 46 to 55 years in contrast to the literature which states that incidence peaks in 6th decade of life ¹⁻⁸. In the current study, two patients have gynaecomastia out of which one of them had bilateral gynaecomastia and has given history of regular consumption of unspecified hormonal tablets for the last 3 years. Gynaecomastia may precede male breast cancer in 20%¹ of men but is not a risk factor of it ². Obesity is associated with higher levels of estrogen in the body, which increases the risk of male breast cancer.¹¹⁻¹⁴ In the present study, exposure to chemicals in the form of petroleum products have been evidenced in 33% cases but no literature till date have mentioned its significance.

Majority of patients presented with palpable breast lump with or without pain which parallels the study of Male Breast Carcinoma: A Clinical and Pathological Review in 2016 (Sara Javidiparsijani, Lauren E. Rosen, and Paolo Gattuso). Presentation of majority of the cases in Stage 3 of the disease emphasises that male breast cancer, for any reason, is diagnosed at a later stage than Female breast cancer. Infiltrating ductal carcinoma accounts to 89% of all cases which parallels to the same study and other similar studies done at Marshal University of California,2021; in Istanbul in 2023 and by Deepak Sundriyal & et al in New Delhi in 2015. In this study, two patients who have expired during the study period have a triple negative hormonal receptor status which suggests the poor outcome of the disease with triple negative status. This result is consistent with the study of QI Wu, Shan Zhu and et al of Poorer breast cancer survival outcomes in males than females in 2016 done in Wuhan university, China.

CONCLUSION :

The median age of presentation of the disease have shifted to the younger age zone. Stage 3 is most commonly encountered in males. The exposure to petroleum products may be a risk factor which needs further evaluation. Male Breast Carcinoma are more likely to be node positive and have high propensity of lympho-vascular invasion. Majority of the male breast carcinoma patients have shown to be ER/PR positive with Her2 Neu negative which have also shown to have a good prognosis following treatment. The hormone receptor negatives status is associated with higher mortality of the patients. It is high time for aggressive awareness, attention and support for men with breast carcinoma who experience unique emotional challenges with feelings of isolation, confusion, fear, and anxiety.

LIMITATIONS OF THE STUDY:

- There exist limited data on transgender patients with breast carcinoma.
- Genetic predisposing factors including BRCA1 and BRCA2 have not been studied.

- Hormone levels of the patients are not measured pre operatively or post operatively.
- The role of interleukins has not been studied
- Finally, due to the rarity of the disease, the small number of cases in our study may affect the validation of its conclusion. Additional studies with larger numbers of patients are needed to achieve sufficient statistical power.

ACKNOWLEDGEMENT:

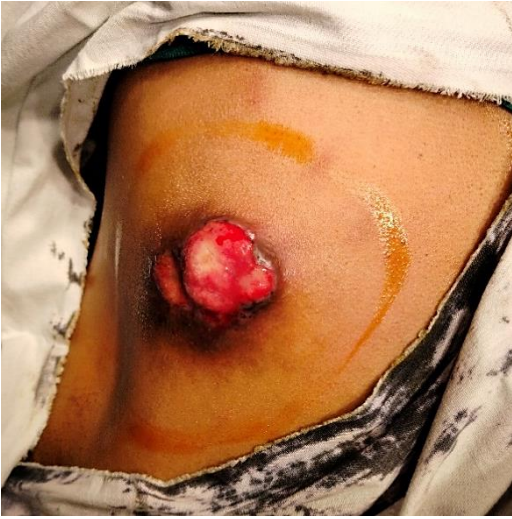I extend my heartfelt gratitude to my mentors Dr. Diganta Borgohain, Dr. Uttam Konwar and Dr. Razvi Das for their unbound guidance and expertise in the preparation and fruitful completion of the study. I would like to thank the registrars Dr. Deeparani Pegu and Dr. Surya Kumar Saikia who have helped me to shape this study into a beautiful outcome. I shall always be indebted to Rajnish Baruah who have contributed endlessly in searching and researching of such rare cases and for all his time, goodwill, kindness and support that have brought the study to this humble platform of publication. Finally, I would like to thank Naveen, Rohit, Shahid and Maya who have been a great source of help and pleasure during the study.

No potential conflict of interest

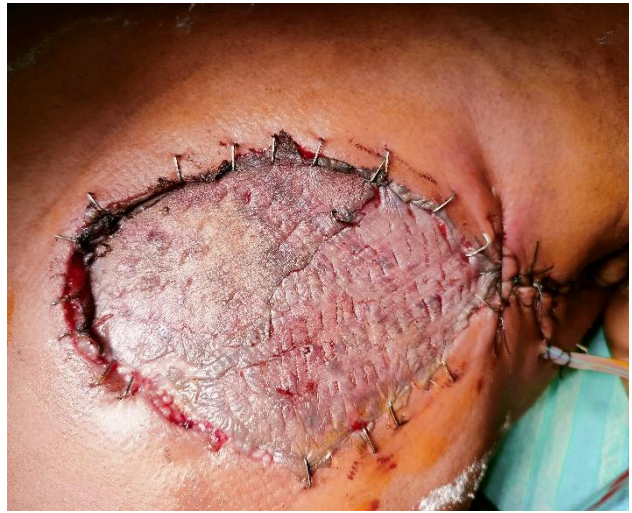Ethical clearance taken

Consent for publication is taken from their next of kin in case of the deceased patients.

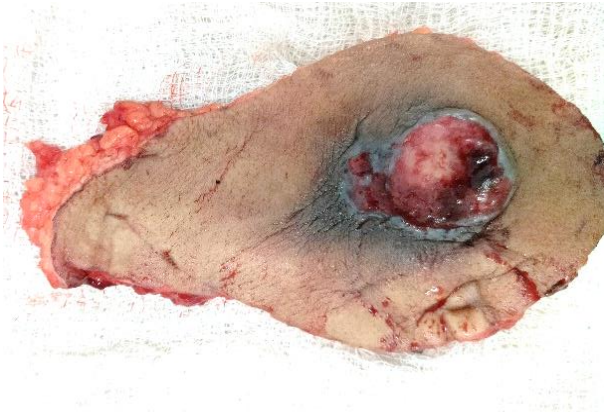Informed consent taken and protection of privacy is ascertained.



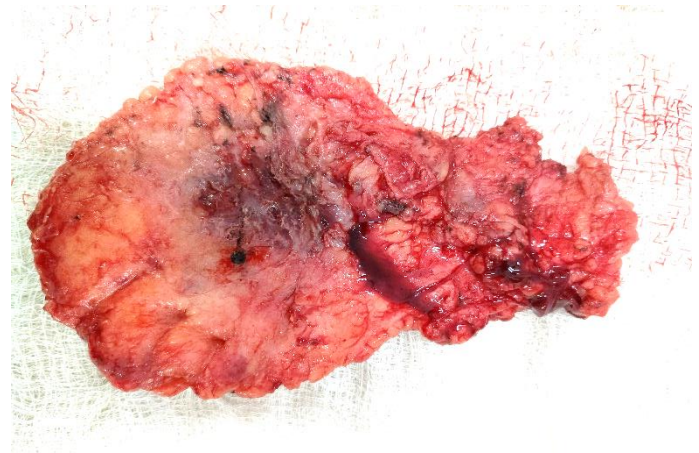
Preoperative breast lesion planned for modified radical mastectomy



Post-mastectomy with split skin grafting



Cutaneous surface of the excised specimen



Undersurface of the excised specimen containing the tumour

REFERENCES OF THE STUDY

1.	Schwartz's textbook of Surgery 11th edition
2.	Sabiston textbook of Surgery 20th edition
3.	Bailey and Love's short practice of Surgery 28th edition
4.	Male Breast Carcinoma: A Clinical and Pathological Review: Sara Javidiparsijani, MD1, Lauren E. Rosen, MD2 and Paolo Gattuso, MD1, 2016
5.	Unraveling Stigmas of Male Breast Carcinoma: A Singular Case of Advanced Metaplastic Breast Carcinoma in a Young Male. Muhammad Awais Kanwal, Umaisa Khalid, and et al. 2023
6.	Hereditary breast cancer: syndromes, tumour pathology and molecular testing, A Sokolova,K J Johnstone,A E McCart Reed,P T Simpson,S R Lakhani 05 December 2022
7.	Targeting signalling pathways and the immune microenvironment of cancer stem cells—A clinical update JA Clara, C Monge, Y Yang, N Takebe, nature.com 2020
9.	Male breast cancer risk associated with pathogenic variants in genes other than <i>BRCA1/2</i> : an Italian case-control study by Agostino Bucalo, Giulia Conti, Virginia Valentini, Carlo Capalbo, doi.org/10.1016/j.ejca.2023.04.022
10.	Epidemiology of male breast cancer by Santhi Konduri, Maharaj Singh, George Bobustuc, Richard Rovin, Amin Kassam February 2020
11.	Fasoulakis Z, Kolios G, Papamanolis V, Kontomanolis EN. Interleukins Associated with Breast Cancer. <i>Cureus</i> . 2018 Nov 5;10(11):e3549. doi: 10.7759/cureus.3549. PMID: 30648081; PMCID: PMC6324869.
12.	Yildiz S, Bayil Oguzkan S, Ozaslan M, Kizikli A, Halil Kilic I, Yilmaz M. Interleukin-6 And Interleukin-10 Polymorphisms In Chronic Lymphoid Leukemia Patients. <i>Asian Pacific Journal of Cancer Prevention</i> . 2024 Feb
13.	Niculet E, Chioncel V, Elisei AM, Miulescu M, Buzia OD, Nwabudike LC, Craescu M, Draganescu M, Bujoreanu F, Marinescu E, Arbune M, Radaschin DS, Bobeica C, Nechita A, Tatu AL. Multifactorial expression of IL-6 with update on COVID-19 and the therapeutic strategies of its blockade (Review). <i>Exp Ther Med</i> . 2021 Mar;
14.	Multifactorial expression of IL-6 with update on COVID-19 and the therapeutic strategies of its blockade (Review). <i>Exp Ther Med</i> . 2021 Mar
15.	Sequencing of Interleukins4, 13, 31, and 33 - An Integrated Systematic Review: Dermatological and Multidisciplinary Perspectives. <i>J Inflamm Res</i> . 2022 Sep 8
16.	Mihailov R, Tatu AL, Niculet E, et al. A narrative review of cutaneous manifestations and imaging landmarks of breast cancer, 2024
17.	Cutaneous lesions as the first manifestation of breast cancer: a rare case. Harwin Prestasia Putra, Khairuddin Diawad, Airin Riskianty Nurdin. Dec 2020
18.	Pleomorphic Appearance of Breast Cancer Cutaneous Metastases, Alexander Muacevic and John R Adler Philip R Cohen, 2021 December
19.	An unusual cutaneous manifestation of inflammatory breast carcinoma, Sherin Jose, Anila Nitin and et al, Government Medical College, Kottayam, Kerala, 2020
20.	A review of the management of the male breast carcinoma based on an analysis of 420 treated cases : G. G. Ribeiro, R. Swindell, M. Harris, S. S. Banerjeet and A. Cramert The Christie Hospital Trust, Manchester, UK

ACRONYMS USED:

MBC : Male Breast Carcinoma

FBC : Female Breast Carcinoma

MRD : Medical Records Department

MRM : Modified Radical Mastectomy

HPE : Histopathological Examination

ER : Estrogen Receptor

PR : Progesterone Receptor

Her 2 Neu : Human Epidermal Growth Factor Receptor 2

