

## **A Rare Case Report of Intrabdominal fibrosarcoma in a German Shepherd Dog**

### **Abstract**

The purpose of this study is to present an intra-abdominal fibrosarcoma in a canine and its histopathological findings. An eight years old female German Shepherd was brought to department of Veterinary Clinical Complex, LUVAS, Hisar. The dog was anorectic with dull and depressed condition. Physical examination showed pale mucous membranes and distended abdomen. The haemoglobin was decreased progressively. On Palpation of the abdomen a painless mass of hard consistency and irregular surface was felt. Serum biochemical abnormalities included increased SGOT, SGPT and alkaline phosphatase but plasma total protein, globulin and albumin was within normal range. The case was diagnosed with the help of radiography and ultrasonography. Thus, an exploratory laparotomy was performed, identifying a multinodular mass in the omentum and mesentery attached to a portion of the stomach and small intestine. A eight kilogram firm mass with irregular surface and great vascularisation was excised. On histopathology, the tumorous mass was found to be fibrosarcoma characterized by spindle shaped neoplastic cells arranged in interwoven pattern and presence of mitotic figures.

Keywords: Digestive system, dog, gastrointestinal, neoplasms, tumors.

### **Introduction**

Fibrosarcoma is a malignant tumor that is usually seen in elderly dogs and originates from fibroblasts in connective tissue (Atalan *et al.*, 2009). Genetic susceptibility, various chemical substances (Cullen *et al.*, 2002), subcutaneous vaccine injections (Madewell *et al.*, 2001), subcutaneous microchips implants (Vascellari *et al.*, 2006), parasitic infections, chronic inflammations (Doddy *et al.*, 1996), and operation material forgotten in the abdominal region (Rayner *et al.*, 2010) are among the causes of fibrosarcomas in dogs and other animal species. It is thought that in this case the intestinal content induced an inflammatory reaction, which in turn led to stimulated neoplastic transformation, resulting in a fibrosarcoma, as reported in the literature (Madewell *et al.*, 2001). Fibrosarcoma is a common neoplasm that occurs in dogs, cats and other domestic animals. The skin subcutis and the oral cavity are the primary sites of occurrence of fibrosarcomas in dogs and other domestic animals (Goldschmidt and

Hendrick 2002), but these can develop anywhere in the body such as the the heart (Speltz *et al.*, 2007), urinary bladder (Olausson *et al.*, 2005), uterus (Govaereet *et al.*, 2010) andomentum (Rayner *et al.*, 2010).Treatmentin the veterinary literature has included surgery alone, chemotherapy, radiation therapy or combination therapies (Tanriseveret *et al.*, 2020). The aim of this case report was to evaluate the results of the combination of surgery and chemotherapy in this case.

### **History and diagnosis**

An eight years old female German Shepherd was brought to Department of Veterinary Clinical Complex, LUVAS, Hisar. The dog was anorectic with dull and depressed condition. Physical examination showed pale mucous membranes and distended abdomen. The haemoglobin was decreased progressively from 18 to 10.2 gm/dl with in 45 days. The value of TLC was  $32.2 \times 10^3 / \mu\text{l}$  with lymphocytosis. The value of PCV was 54.3 %. On Palpation of the abdomen a painless mass of hard consistency and irregular surface was felt. Serum biochemical abnormalities included increased SGOT (520.7 IU/L), SGPT (691.3 IU/L) and alkaline phosphatase (462.6 IU/L) but serum creatinine, Blood urinary nitrogen, total protein, globulin and albumin were with in normal range. Radiographic examination showed a large sized round radiopaque mass was seen which occupied the whole abdominal cavity (Fig.1). After radiography, ultrasonography was performed in later recumbancy. Ultrasonogram showed multiple number of tumorous masses with mixed echogenicity having anechoic pockets in the centre (Fig. 2).

### **Surgical procedure**

The ventral abdomen of dogs was prepared for aseptic surgery. The dog was anaesthetized with balanced anaesthetic protocol using atropine @ 0.04 mg/kg i.m. for premedication and xylazine @ 1mg/kg i.m. for sedation. Induction was done with propofol @ 4mg/kg i.v. Maintenance of anaesthesia was done with Isoflurane @ 1-2 % with oxygen with flow rate of 50 ml/kg. The abdomen was entered through mid -ventral laparotomy incision. The tumor was removed surgically which was attached with stomach and the mesentery of the small intestine (Fig. 3). The abdominal cavity was flushed with NSS. The abdominal incision was closed in routine manner. The weight of the tumor mass was around eight kilograms. Histopathological samples were collected from the tumor and as well as from the ovarian mass. Post-operatively dog was given Dextrose normal saline @ 60-80 mg/kg i.v.o.d., Ceftriaxone with Tazobactam (IntacefTazo) @ 20 mg/kg i.m.b.d., Metrogyl @ 20 mg/kg

i.v.o.d, Aciloc @ 2mg/kg i.m.o.d. Analgesic Meloxicam was given @ 0.2mg/kg i.m.o.d. for five days. Antiseptic dressing of surgical wound was done for 12 days till removal of skin sutures. After two days of surgery feeding of dog was started using liquid and semisolid diet in small quantity 5-6 times a day. The normal diet was given from 10<sup>th</sup> day post operatively. One week after the operation, the chemotherapy application was started with using vincristine sulphate. Intravenous administration of vincristine sulphate @0.025mg/kg (0.5-0.7 mg/m<sup>2</sup>, maximum 1 mg) in 500 mL isotonic serum with slow infusion at 3 times per week, but recurrence started in the same area and bilateral region about two weeks after the last chemotherapy.

After 40 days reoccurrence of tumor was seen. Owner was told about the prognosis but surgery was repeated on owner's request. On ultrasonography similar multiple nodules having mixed echogenicity occupying the abdominal cavity were found. On laprotomy the tumor was attached with liver, spleen and stomach this time. The weight of the tumor was around five kilogram this time. Unfortunately dog died on the next day.

### **Histopathology**

Tissue samples were fixed in 10% buffered formalin for histopathological analysis. On histopathology, the tumorous mass was found to be fibrosarcoma characterized by spindle shaped neoplastic cells arranged in interwoven pattern and presence of numerous mitotic figures. (Fig. 4 and 5).

### **Discussion**

In dogs, oral FSA tends to occur in large breed dogs (Sarowitz *et al.*, 2017). The median age at diagnosis is 7.3 to 8.6 years and there may be a male predisposition (Gardner *et al.*, 2013). We found the intraabdominal tumor in eight years old male German Shepherd dog. In accordance with Jeewanet *et al.* (2015) malignant soft tissue tumours of the abdominal wall consist of desmoid and non-desmoid soft tissue sarcomas. They tend to invade adjacent musculo-aponeurotic and bony structures, Transperitoneal organ invasion can also occur with devastating sequelae, especially after an incomplete excision. Valenti *et al.* (2021) studied the diagnosis and tissue distribution of abdominal masses in a canine population and they found that frequency of malignant lesions was higher in the gastrointestinal masses as compared to other sites. They found that gastrointestinal masses (12 out of 15) were not associated with any organ as also seen in present case. Interestingly, the majority of the gastrointestinal masses were malignant spindle cell tumors (8 out of 15). This finding was surprising since, in

the gastrointestinal tract of the dog, the most frequently reported tumors are adenocarcinomas and lymphomas. Although radiation, chemotherapy and surgical excision treatments were reported to be safe and effective in the treatment of fibrosarcomas (Tanrisever *et al.*, 2020).

## Conclusion

Thus, it was concluded that the desired result could not be obtained in this case due to the large size of the mass, poor prognosis and the age of the patient. Prognosis of the tumor is dependent on histological grade, tumor size and adequate surgical treatment with tumor cells free margins (Maliki *et al.*, 2014).

## References

Atalan G, Atasever A, Yavuz Ü, Güneş V, Onmaz AC. Kangal, IBK (2009). Oral fibrosarkom olgusu. *FU Sag Bil. Vet. Derg.*, 23: 167-169

Cullen JM, Page R, Misdorp W (2002): An overview of cancer pathogenesis, diagnosis, and management. In: Meuten DJ (ed.): *Tumors in Domestic Animals*. 4<sup>th</sup> ed. Iowa State Press, Iowa. 03–44.

Doddy FD, Glickman LT, Glickman NW, Janovitz EB (1996): Feline fibrosarcomas at vaccination sites and non-vaccination sites. *Journal of Comparative Pathology*, 114, 165–174.

Gardner H, Fidel J, Halderson G, *et al.* (2013). Canine oral fibrosarcomas: a retrospective analysis of 65 cases (1998–2010), *Vet Comp Oncol*. 13:40–47.

Goldschmidt MH and Hendrick MJ (2002): Tumors of the skin and soft tissues. In: Meuten DJ (ed.): *Tumors in Domestic Animals*. 4<sup>th</sup> ed. Iowa State University Press, Iowa. 45–117.

Govaere, J., Maes, S., Saey, V., Blancke W, Hoogewijs M, Deschauer C, Smits K, Roels K, Vercauteren G and Kruif AD (2010). Uterine fibrosarcoma in a warmblood mare. *Reproduction in Domestic Animals*, 46: 564–566.

Jeewan R. V., Channabasappa K., Saumya, S., Sameer, G., Vijay K. and Shiv R. (2015). Giant fibrosarcoma of anterior abdominal wall: a rare case report and review literature. *International Journal of Research in Medical Sciences*, 3(9):2488-2491

Madewell, B. R., Griffey, S.M., McEntee, M. C, Leppert, V. J. and Munn, RJ (2001). Feline vaccine-associated fibrosarcoma: an ultrastructural study of 20 tumors (1996– 1999). *Veterinary Pathology*, 38: 196–202.

Maliki, O., Aleksandrov, O., Carler, P., Planquarta, X., Vazb, E., Bertrandb, C. and Rosikon, A.(2014). Fibrosarcoma ofthe nasal cavity: A case report. *EJENTAS.EgyptianJournalofEar,Nose,ThroatandAlliedSciences*, 15: 275-277.

Olausson, A., Stieger, S.M., Lofgren, S. and Gillingstam, M. (2005).A urinary bladder fibrosarcoma in a young dog. *Veterinary Radiology and Ultrasound*, 46: 135–138.

Rayner EL, Scudamore CL, Francis I and Schoeniger S (2010). Abdominal fibrosarcoma associated with a retained surgical swab in a dog. *Journal of Comparative Pathology*, 143: 81–85.

Sarowitz, BN, Davis, GJ and Kim, S. (2017). Outcome and prognostic factors following curative-intent surgery for oral tumours in dogs: 234 cases (2004 to 2014). *J Small Anim Pract.*, 58:146–153.

Speltz, MC, Manivel, JC, Tobias, AH and Hayden, DW (2007). Primary cardiac fibrosarcoma with pulmonary metastasis in a labrador retriever. *Veterinary Pathology*, 44: 403–407.

Tanrisever M., Karabulut, B. and Cevik, A. (2020). A Fibrosarcoma Case with Poor Prognosis in a Golden Retriever Breed Dog. *F.U. Vet. J. Health Sci.* 34 (2): 115 - 118

Valenti, P., Pellegrino, V., Muscatello, L.V., Brunetti, B., Zambon, E., Gerboni, G.M., Alberti, M. and Avallone, G. (2021). The Site of Origin of Canine Abdominal Masses Correlates with the Risk of Malignancy: Retrospective Study of 123 Cases. 11: 962.

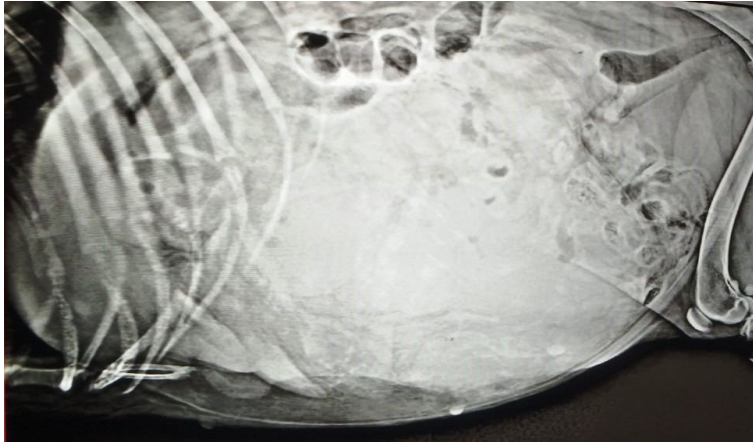


Fig.1: Radiograph showing the large size radiopaque round mass (white arrow).

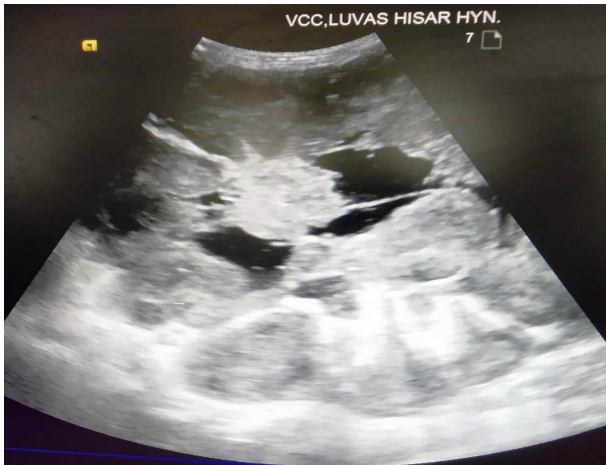

Fig.2: Ultrasonogram showing tumorous mass with mixed echogenicity having anechoic pockets (white arrow) in the centre.

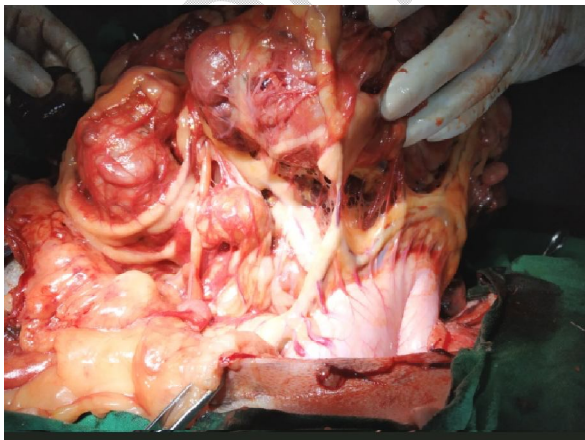


Fig. 3: Photograph showing attachment of tumorous mass with stomach

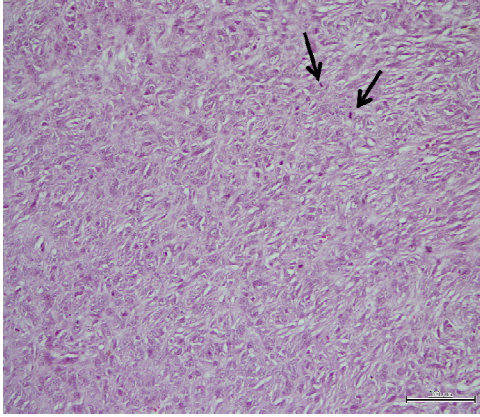


Fig. 4: Photomicrograph showing fibrosarcoma characterized by spindle shaped neoplastic cells arranged in interwoven pattern and presence of mitotic figures (arrows). H&E×100

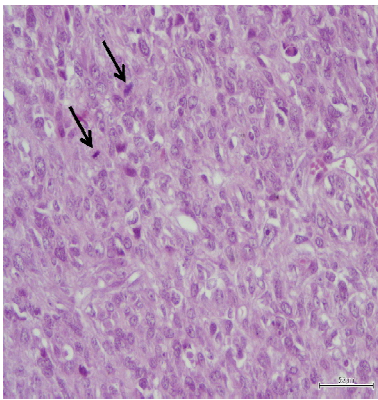


Fig. 5: Photomicrograph showing neoplastic cells characterized by pleomorphic elongated, round to oval nuclei with prominent nucleoli and mitotic figures (arrows). H&E×400