

Intra- and extraconical cavernous hemangiomas in children: the difficulty of therapeutic management

Abstract

This article describes the case of a 10-year-old girl with a rare presentation of extra- and intra-conical cavernous hemangioma in children. After undergoing complete surgical excision, the exophthalmos completely regressed, and no recurrence was observed during the two-year follow-up period. The treatment options discussed included intratumoral corticosteroid injection, oral corticosteroid therapy, and surgical excision.

Keywords : hemangioma, children, cavernous

Introduction

Cavernous hemangiomas are benign tumors that primarily affect the orbit and are more commonly found in young adults. However, they are quite rare in children. In children, capillary hemangiomas are the more prevalent type of vascular tumors. These tumors are usually found on one side and can differ in both location and size. Surgical intervention is typically recommended for treatment, but it can be quite challenging due to the tumor's location and its proximity to important vascular and nerve structures within the orbit.

We present a unique and uncommon case of a 10-year-old girl who was diagnosed with an extra- and intra-conical cavernous hemangioma.

Case report

The case involved a 10-year-old girl with no significant medical history. At the age of 6, she developed progressive unilateral left exophthalmos, along with a bright-red mass in the medial canthus. There were no other associated signs. Ophthalmologic examination revealed an irreducible, painless, non-pulsating, and non-puffing left axial exophthalmos without any signs of inflammation and a bright pink-red lesion in the medial canthus (figure 1). Her visual acuity was estimated at 9/10 in the left eye and 10/10 in the right eye. Her ocular motility was preserved, and fundus examination showed no abnormalities. An MRI was performed, which revealed a left orbital lesional process. The

lesion appeared heterogeneous on the MRI, with isosignal T1 and hypersignal T2. It showed moderate contrast enhancement and measured 44 mm anteroposteriorly, 30 mm in width, and 36 mm in height. The lesion infiltrated the intra- and extraconal fat and involved the optic nerve, although the nerve remained well individualized. The lesion predominantly affected the internal angle of the orbit, resulting in grade III exophthalmos (figure 2). The patient was referred to the neurosurgical department for management. She underwent complete en bloc excision of the left intraorbital lesion using a high endocranial approach. The lesion was encapsulated and had a hard consistency. Histological examination of the excised specimen confirmed the diagnosis of intra-orbital cavernous hemangioma. The immediate post-operative course was uneventful, with complete regression of the left exophthalmos. Palpebral ecchymosis and left chemosis appeared after the surgery but resolved completely within a few days. After a two-year follow-up, the patient showed no signs of local recurrence.

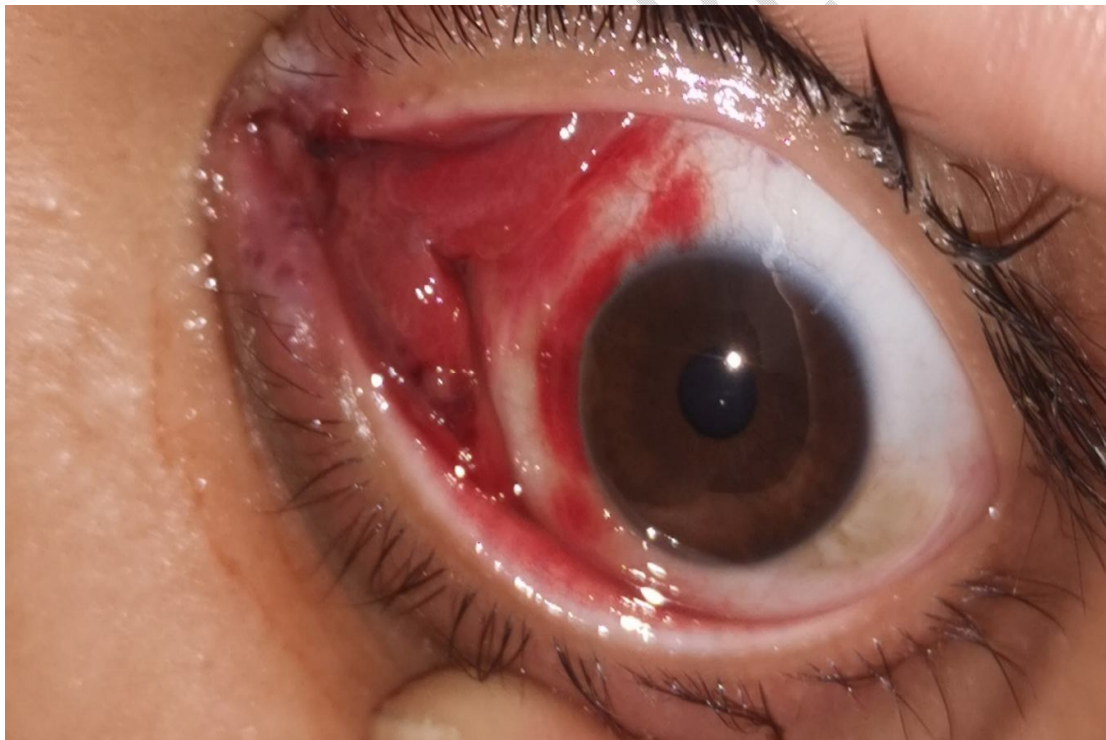

Figure 1 : A bright pink-red lesion in the medial canthus

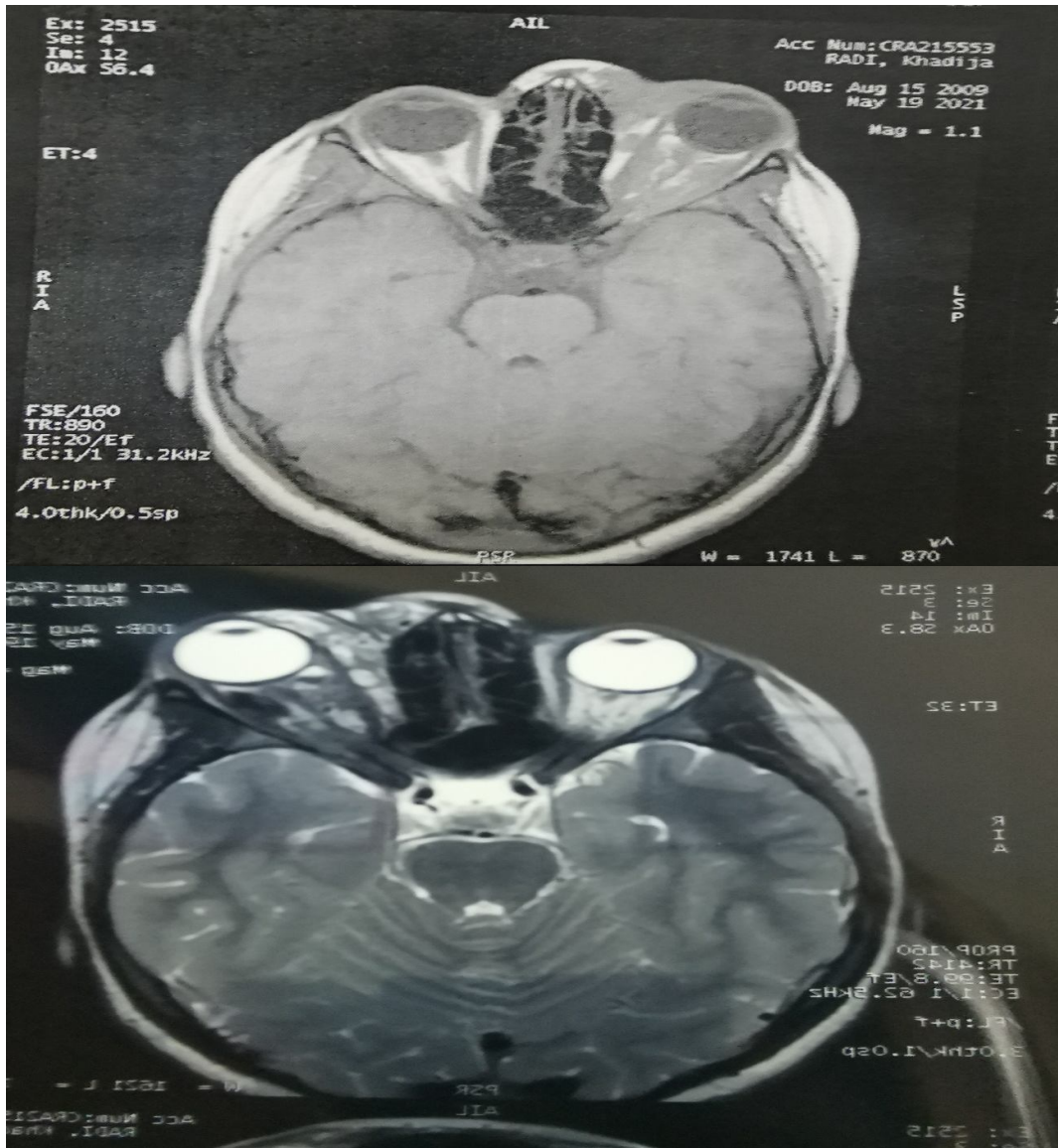


Figure 2 :MRI appearance consistent with left intra- and extra-orbital conical hemangioma with medial canthal predominance

Discussion

Vascular tumors of the orbit are mostly benign, and the most common are cavernous hemangiomas. According to the main series published [1], cavernous hemangiomas account for 3-14% of all orbital tumors, and 50-80% of all orbital vascular tumors [2]. They generally affect young adults, rarely before the age of 20. However, our patient presented with this tumor at an older age, with a clear female predominance. In fact, the sex ratio is seven out of ten women. Common symptoms of these tumors include axial exophthalmos, which is progressive, painless, reducible, non-pulsatile and

may be accompanied by decreased visual acuity or ocular motility disorders. In rare cases, a more acute presentation with haemorrhage or thrombosis has also been reported [3].

These tumors are usually unilateral and can vary in location and volume. The main treatment is surgical, but the location of the lesion and its relationship with intraconical vascular-nervous structures make the procedure complex.

There are three main therapeutic options for treating these tumors: (4) intratumoral injection of corticosteroids, which may use different molecules jointly (triamcinolone, betamethasone, dexamethasone and methylprednisolone); (5) surgical excision; (6) oral corticosteroid therapy (Prednisone® 1 mg/kg/day) with the usual associated measures (low-salt diet, vitamin calcium and potassium supplementation) [4, 7]. These therapeutic options can be used alone or in combination. In cases where a single therapy is not effective, these different options can be used synergistically.

CONCLUSION

Cavernous hemangiomas in children are rare and challenging to treat due to their orbital location. Effective management options include corticosteroid therapy and surgical excision. Surgical removal is often preferred for complete symptom relief. Long-term follow-up is essential to monitor for recurrence.

REFERENCES

1. P.-A. Aymarda, *, B. Langlois, M. Putterman, P.-V. Jacomet, S. Morax, O. Galatoire, Management of orbital cavernous hemangiomas — evaluation of surgical approaches: about 43 cases, *French Journal of Ophthalmology* (2013) 36, 820—829
2. J. Bouguila 1, *, K. Yacoub 1, H. Bouguila 2, N. Ben Neji 1, S. Sahtout 1, G. Besbes 1. Intra-orbital cavernous hemangiomas. *rev Stomatol Chir Maxillofac* 2008;109:312-315
3. uban JM, Navailles B, Yalazkan B. Large orbital-palpebral cavernous hemangioma. *J Fr Ophthalmol* 1992;15:357—62. □
4. 1. Wasserman BN, Medow NB, Homa-Palladino M, Hoehn ME. Treatment of periocular capillary hemangiomas. *J AAPOS* 2004;8:175-81.
5. Offret G, Brini A, Dhermy P, Bec P. *Pathological anatomy of the eye and its appendages. Report from the French Society of Ophthalmology.* Éditions Masson; 1974.
6. Brini A, Dhermy P, Sahel J. *Oncology of the eye and adnexa. Anatomical-clinical atlas.* Dordrecht; Boston; London: Kluwer academic publishers; 1990.
7. Offret G, Haye C. *Tumors of the eye and ocular adnexa.* Éditions Masson; 1974.