

Case report

Oral Squamous Cell Carcinoma in Lao Elderly Patient with delay diagnosis: A Case Report

ABSTRACT

Introduction: Oral squamous cell carcinoma is a malignant epithelial. It is one of the major causes of mortality and mobility in humans especially in elderly person because the body loos of function from ageing.

Case presentation: We describe the care of female elderly Laotian diagnosed with oral squamous cell carcinoma in advanced stage and with a delayed diagnosis due to living in a rural rea. The patient, an 84-year-old, was seen at the Department of Basic Sciences in Dentistry, Faculty of Dentistry, University of Health Science Lao PDR.

Conclusion: An oral squamous cell carcinoma is multifaceted, involving biological factors such as aging, environmental processes, lifestyle factors, medical factors, delays in diagnosis and treatment, and access to healthcare. The early stage of detecting oral squamous cell carcinoma is a potentially malignant earlier must be the treatment outcome.

Keywords: Oral squamous cell carcinoma, Elderly patient, Risk factors, Delay diagnosis.

1. INTRODUCTION

The scientist research suggested, that 90% of oral cancer was identified as an oral squamous cell carcinoma [1] with the rate growth of oral cancer increases by 50% each year in the world [2]. It is the main cause of death from oral health diseases in many countries such as India and other south or eastern Asia regions [3] [4] [5]. According to Lao were increase 2.2% of new cases in 2020 [6] and 2,3% of new case in 2023[7]. Oral squamous cell carcinoma is one type of malignant epithelium neoplasm of the head and neck tumor in common, that can occur anyway within the oral cavity such as tongue, floor of the mouth, gingivobuccal. It is locally invasive, infrequently metastasizes to ipsilateral regional lymph nodes, a rarely spreads to distance sited [8]. Over a considerable period of time used tobacco, alcohol consumption and chewing betel leaves and inverted smoking were traditional risk factors of oral squamous cell carcinoma [9] [10]. The etiology of the tumor is found particularly low-income communities and is still mainly a problem of older people, 90% being over 45 years of age, with rate comparison of oral cancer was high prevalence in males than female at 14.4% [11] [12] [13] [14]. The clinical presentation of oral squamous cell carcinomas can be range from a white path or red path to an unclerated lesion, painful, including characteristics from exophytic or endophytic mass depend on location of the lesion[15]. Future more, the impact of delayed diagnosis can have efficiencies both of patient outcome and the public health care system, whereas progression due to advance stages, which

are harder to treat and reduce survival rate, reduce treatment options because of more aggressive and invasive treatment, high health care cost and increases morbidity and mortality rates in the individual [16].

However, the early stage of detecting oral squamous cell carcinoma is a potentially malignant earlier must be the goal, especially an elderly patient group [17]. Evidence showed that, age, stage, and site of cancer are most important for determinants of treatment of the oral cancer because increasing of age and stage were divided treatments toward non-surgery option treatment or treatment at all [18] [19]. Therefore, this case was reported, because the patients was coming in our department with an advanced stage ulcer and high-grade histology features.

2. CASE REPORTED

The patient, an 84-year-old female, was seen at the Department of Basic Sciences in Dentistry, Faculty of Dentistry, University of Health Science Lao PDR on Mach 2023, with a chief complaint of chronic pain in the lower mandibular left of the posterior teeth region for 3 months. The patient gave a history of taking antibiotics and antiseptics for 7 days before visiting the clinic. She had a long history of betel crew use for over 10 years and no systemic medical history. On extra-oral examination, larger submental lymph nodes measured 2 cm x 2 cm on the right and left sides of the face and neck regions. In the intraoral examination, there were poor oral hygiene and missing teeth (N.25, N.47, N.45, N.42, and N.41). A moderately sized exophytic ulcerative mass measuring 5 cm x 4 cm was found in the retromolar area until the lateral incisor, including the frenum, buccal fold, gingival, and floor of the mouth on the left side of the mandible. The lesion showed an irregular, white and red patch with a verruciform surface that was firm, hard on palpation, and easily bleeding, as shown in Fig. 1. The excisional biopsy was performed under histological examination. The pathology feature was diagnosis in the poorly differentiated grade of oral squamous cell carcinomas in (Fig. 2).

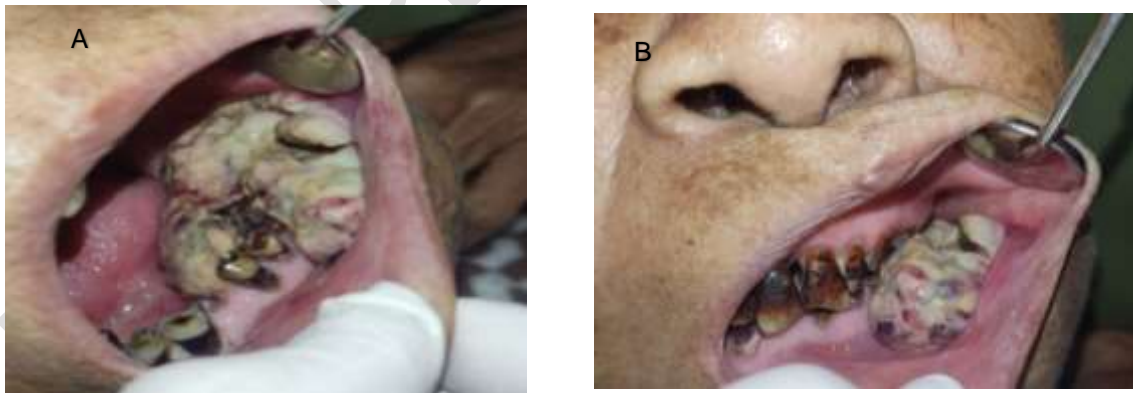


Fig. 1: (A) Intra-oral examination showing the lesion on the lingual surface with moderately sized exophytic ulcerative mass and an irregular, white patch with a verruciform surface; (B) clinical presence on the buccal surface with large-sized exophytic ulcerative mass from the left mandible to the retomolar.

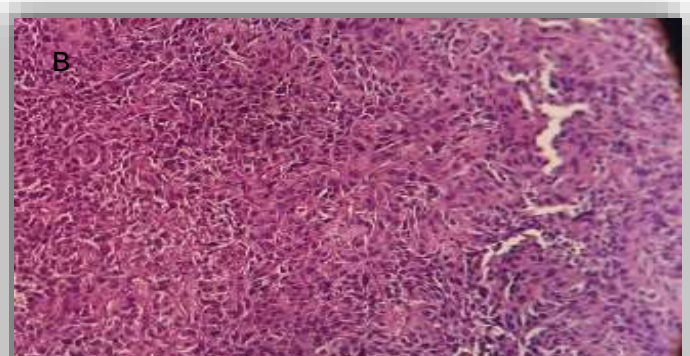
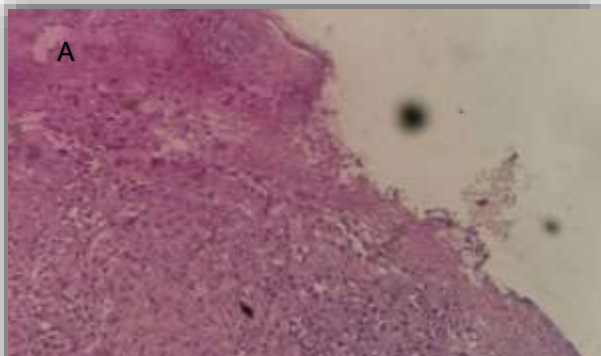


Fig. 2: (A) Low power photomicrograph showing lesion area, malignant cells invading in to the lamina propria and the numerous pleomorphic cells is seen (H&E,10x). (B) High power photomicrograph showing a hyperchromatic nuclei and increased nuclear to-cytoplasmic ration (H&E, 100x).

3. DISCUSSION

Oral squamous cell carcinoma is a type of oral cancer that originates from the squamous cell lining in the oral mucosa which a clinical presentation ranging from a white patch to an ulcerated lesion that is painful, including characteristics of an exophytic or endophytic mass, a proportion rate of sex was high in female group. The different of diagnosis included oral leukoplakia, oral verrucous carcinomas [20]. The important of case reported, we found the patient was older and had a habit of betel chewing for a long time with a primary diagnosed in oral stomatitis from health center and current staying at rural area. Therefore, the patient came late for diagnosis of oral cancer, according to the chronic infection with mass increasing in a short time. Due to the clinical symptoms, the excisional biopsy was performed in an ulceration mass and sent to the pathology laboratory at the Medical Faculty, University of Health Sciences for a final diagnosis. The result identifies a poorly differentiated grade of oral squamous cell carcinomas with TNM stage [21] was T3N2, while distant metastasis was not yet identifying because the patient is an unsurgons.

In fact, the multifaceted risk factors of oral squamous cell carcinomas are strongly associated with aging in elderly people. Amorim et al. (2023) showed that over 80% of elderly patients were diagnosed with oral squamous cell carcinoma [22] and the median survival time for elderly patients was 30 months shorter if compared with young patients. Similar to Yang et al. (2023), five-year survival rates peculiar to cancer were statistically significant and strongly dependent on age [23]. As identified by the WHO in 2022, the number of new cases of oral cancer increased from 2.2% in 2020 to 2.3%, and the mortality rate of oral cancer deaths was 2% in the Lao population [7]. That indicates the death rate associated with an oral cancer diagnosis is fairly significant, particularly in cases affecting elderly individuals because of the progressive loss of functional reserve of multiple organ systems in old people, while the advantage stage of cancer can invasively affect to the important organs of body, for instance, the peritoneum, pleura, pericardium, and arachnoid by transcoelomic spread, lymphatic, and blood vessels. Future more, health care assessment is necessary because that it ensures that individuals receive appropriate, timely, and in efficient care. As an example improving patient outcome, early detection can detect potential health problem early, increasing the chances of successful treatment on time as a Yunhan et al. (2023), found that 80%-90% of oral cancer survival rates can increase with early detection [24] and based on the findings of Jingjin et al.(2023), age has a crucial role in determining the variation the oral squamous cell carcinoma process [23].

In addition, majority of oral lesions can be diagnosed following clinical features indicated in oral mucosa conditions, while there are some oral lesions that have similar clinical characteristics that make it difficult to diagnosis diseases, especially oral squamous cell carcinoma. Moreover, histology examination is important of disease diagnosis process an examples a cytological, Hematoxylin and Eosinophil technique because there are objectively focused on characteristic, exfoliates of cells and type of cell, the tissues provide important information about the pattern, shape and structure of cell in a tissue sample. Consequently, in this case reported was in advanced stage disease with multiple factors impacting the develop of disease. According to Ogunbodede et al.(2015), there are inequalities in the levels of conception issues between rural and urban area due to conception living issues such as lower literacy and education levels, which affect oral health care and treatment outcomes and service delivery in rural area [25] and lower economic status was a deeper statistic significant with an impact oral health issues [26]. However, there are many treatment protocols for oral squamous cell carcinoma; anyway, it still remains a public health issue in developed and developing countries. That is why the final diagnosis process to identify an oral lesion needs a systematic approach, and the doctor who will be diagnosing oral cancer must have knowledge of the characteristics and signs of the disease, especially in the early stages of the disease. The risk factors related to the occurrence of disease are potential, including tissue biopsy in pathology examinations in order to determine oral cancer. In addition, the service center for the treatment of oral cancer must be sufficient for the ratio of population living. For this case report after final diagnosis we has consulting with patient and sent her to the cancer center for treatment.

4. CONCLUSION:

An oral squamous cell carcinoma is multifaceted, involving biological factors such as aging, environmental processes, lifestyle factors, medical factors, delays in diagnosis and treatment, and access to healthcare. They are normally asymptomatic and can be detected incidentally or routinely. Biopsies and histological examination are still the main methods of accurate diagnosis. The early stage of detecting oral squamous cell carcinoma, which is potentially malignant, must be the goal, especially in an elderly patient group.

CONCENFORM

We received a concern from patient before written in case report.

ETHICAL APPROVAL

Do not declared for this case report because this case report belongs from routing of dental clinic guideline treatment.

REFERENCES

1. Choi, S. and J. Myers, Molecular pathogenesis of oral squamous cell carcinoma: implications for therapy. *Journal of dental research*, 2008. 87(1): p. 14-32.
2. Rivera, C. and B. Venegas, Histological and molecular aspects of oral squamous cell carcinoma. *Oncology letters*, 2014. 8(1): p. 7-11.
3. Rivera, C., Essentials of oral cancer. *International journal of clinical and experimental pathology*, 2015. 8(9): p. 11884.
4. Bell, R.B., et al., Tongue cancer: is there a difference in survival compared with other subsites in the oral cavity? *Journal of oral and maxillofacial surgery*, 2007. 65(2): p. 229-236.
5. Argiris, A., et al., Competing causes of death and second primary tumors in patients with locoregionally advanced head and neck cancer treated with chemoradiotherapy. *Clinical cancer research*, 2004. 10(6): p. 1956-1962.

6. Organization, W.H., Lao People's Democratic Republic Source: Globocan 2020. 2021.
7. World Health Organization , I.A.f.R.o.C., Cancer today, Population Factsheets, Lao People's Democratic Republic. Statistics at a glance, 2022. © IARC 1965-2024.
8. Langley-Hobbs, S.J., J. Demetriou, and J. Ladlow, Feline soft tissue and general surgery. 2013: Elsevier Health Sciences.
9. Misra, S., A. Chaturvedi, and N. Misra, Management of gingivobuccal complex cancer. The Annals of The Royal College of Surgeons of England, 2008. 90(7): p. 546-553.
10. Capote-Moreno, A., et al., Oral squamous cell carcinoma: epidemiological study and risk factor assessment based on a 39-year series. International Journal of Oral and Maxillofacial Surgery, 2020. 49(12): p. 1525-1534.
11. Al-Jamaei, A., et al., A population-based study of the epidemiology of oral squamous cell carcinoma in the Netherlands 1989–2018, with emphasis on young adults. International Journal of Oral and Maxillofacial Surgery, 2022. 51(1): p. 18-26.
12. Stewart, B.W. and P. Kleihues, World cancer report. Vol. 57. 2003: IARC press Lyon.
13. dos Santos Costa, S.F., et al., Molecular basis of oral squamous cell carcinoma in young patients: Is it any different from older patients? Journal of Oral Pathology & Medicine, 2018. 47(6): p. 541-546.
14. Bruni L, A.G., Serrano B, Mena M, Collado JJ, Gómez D, Muñoz J, Bosch FX, de Sanjosé S., Human Papillomavirus and Related Diseases Report LAO PEOPLE'S DEMOCRATIC REPUBLIC. 2020(22 October 2021): p. 44-48.
15. Bagan, J., G. Sarrion, and Y. Jimenez, Oral cancer: clinical features. Oral oncology, 2010. 46(6): p. 414-417.
16. Mauceri, R., et al., Diagnostic delay of oral squamous cell carcinoma and the fear of diagnosis: A scoping review. Frontiers in Psychology, 2022. 13: p. 1009080.
17. Van Zyl, A.W. and B.K. Bunn, Clinical features of oral cancer: clinical review. South African Dental Journal, 2012. 67(10): p. 566-569.
18. Shia, B.-C., et al., Outcomes for elderly patients aged 70 to 80 years or older with locally advanced oral cavity squamous cell carcinoma: A propensity score–matched, nationwide, oldest old patient–based cohort study. Cancers, 2020. 12(2): p. 258.
19. Goldenberg, D., et al., *Age and stage as determinants of treatment for oral cavity and oropharyngeal cancers in the elderly*. Oral oncology, 2014. 50(10): p. 976-982.
20. Saghravarian, N., et al., *Human papillomavirus in oral leukoplakia, verrucous carcinoma, squamous cell carcinoma, and normal mucous membrane*. Oman medical journal, 2015. 30(6): p. 455.
21. Spiessl, B., et al., *TNM-atlas: Illustrated Guide to the TNM/pTNM-classification of Malignant Tumours*. 2013: Springer Science & Business Media.
22. Amorim, M.d.M., et al., *Survival of young and elderly adults with oral squamous cell carcinoma in a population in northeastern Brazil*. Brazilian Journal of Oral Sciences, 2023. 22: p. e230008.
23. Yang, J., et al., *Survival analysis of age-related oral squamous cell carcinoma: a population study based on SEER*. European Journal of Medical Research, 2023. 28(1): p. 413.
24. Tan, Y., et al., *Oral squamous cell carcinomas: state of the field and emerging directions*. International Journal of Oral Science, 2023. 15(1): p. 44.
25. Ogunbodede, E.O., et al., *Oral health inequalities between rural and urban populations of the African and Middle East region*. Advances in dental research, 2015. 27(1): p. 18-25.
26. Kuppusamy, E., et al., *Impact of oral health problems on the quality of life among low income group in an urban area in Malaysia: A preliminary study*. Journal of International Oral Health, 2021. 13(6): p. 617-622.