

# Left Intraventricular Myxoma: About Two Cases

## ABSTRACT

Myxoma is a rare benign primary cardiac tumor, which can cause vascular complications. Neurological symptoms may precede or accompany the diagnosis of systemic embolization myxoma, most often occurring in the cerebral circulation.

We report two cases of myxoma, one of which was complicated by an ischemic stroke. Cardiac echocardiography revealed a pedunculated tumor presents on the basal interventricular septum, mobile in the LV chamber in the vicinity of the mitral valve. Surgical excision was performed without any operative or post-operative complications. Histological examination confirmed the diagnosis of myxoma. The clinical course was favorable, with no recurrences after 1 year follow up.

We recall the high incidence of embolization potential of this tumor, whose surgical treatment prevents cerebral embolic recurrences.

*Keywords: Myxoma; emboli; stroke.*

## 1. INTRODUCTION

Primary cardiac tumors are rare entity with a frequency of 0.001% to 0.030%. Approximately 80% of these tumors are benign, of which 70% are myxomas [1-5]. Myxoma is the most common of all primary cardiac tumors. Neurological symptoms may precede or accompany the diagnosis of systemic embolization myxoma, most often occurring in the cerebral circulation. Given the multiplicity of clinical and para-clinical signs they may present, they deserve to be described separately.

## 2. CASE PRESENTATION

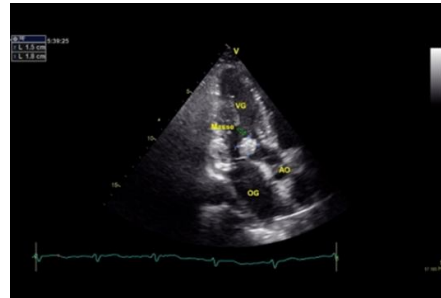
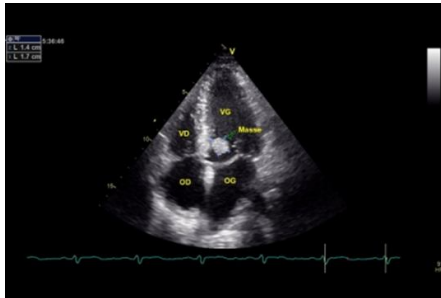
**Case 1:** This is a 34-year-old male patient whose cardiovascular risk factor is chronic smoking at a rate of 10P/A, recently weaned. He presented 3 months ago with right hemiplegia in a febrile context, for which he was treated in a peripheral hospital as an infective endocarditis. He received antibiotic therapy with vancomycin and gentamycin for 5 weeks, and was then referred to our center for further treatment. On admission, the patient reported no cardiovascular symptoms. Clinical examination revealed a conscious patient in good hemodynamic and

respiratory condition, blood pressure (BP) 120/83mmHg, heart rate (HR) 86bpm, SaO<sub>2</sub> 100% on room air. Cardiac auscultation was unremarkable, and neurological examination revealed right hemiplegic sequelae. ECG was done and showed normal sinus rhythm without ischemic changes. The chest X-ray showed a focus of pneumopathy in the lower part of the right upper lobe, and the chest CT confirmed the infectious nature of this focus and suggested a probable tuberculosis origin. Biological tests showed a slightly elevated CRP of 41.8mg/l, and the sputum was negative for koch's bacilli (BK). Trans-thoracic echocardiography (TTE) revealed a mobile intra-LV mass measuring 17x13mm in diameter, with a pedicle base attached to the basal inter-ventricular septum (IVS). Left ventricular systolic function is normal, with LVEF at 60%. The other cardiac chambers are unobstructed. Pulmonary pressure is normal [Figs. 1-2]. Brain computed tomography (CT) revealed three ischemic parenchymal lesions in the supratentorial region [Fig. 5]. The patient was put on anti-bacillary therapy and the therapeutic decision was taken to surgically remove the lesions under extracorporeal circulation (ECC). The mass was surgically removed after one month of anti-bacillary treatment. The immediate

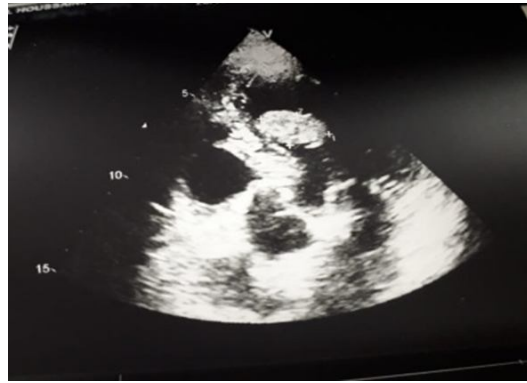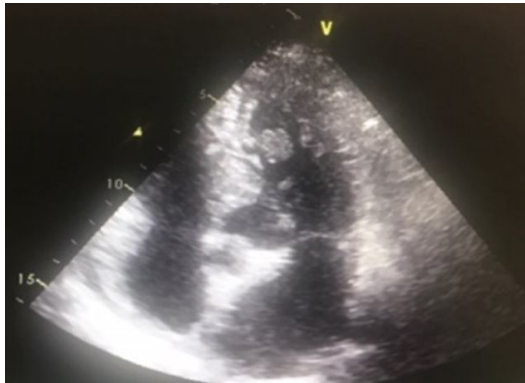post-operative course was straightforward. Pathological examination of the tumor confirmed the diagnosis of myxoma.

**Case 2:** This is a 67-year-old male hypertensive patient. Since 2009, he has been known to have a tumor of the left ventricle (LV), discovered incidentally during the initial assessment of his hypertension. Surgical resection was indicated, but the patient refused the procedure. He had been reporting atypical chest pain for three months. On clinical examination, the patient was hemodynamically stable: BP 135/83 mmHg, HR 64 B/min, SaO2 100% on room air. The rest of the cardiovascular examination was unremarkable. ECG showed a regular sinus rhythm, HR 56B/min, and the cardiac axis was

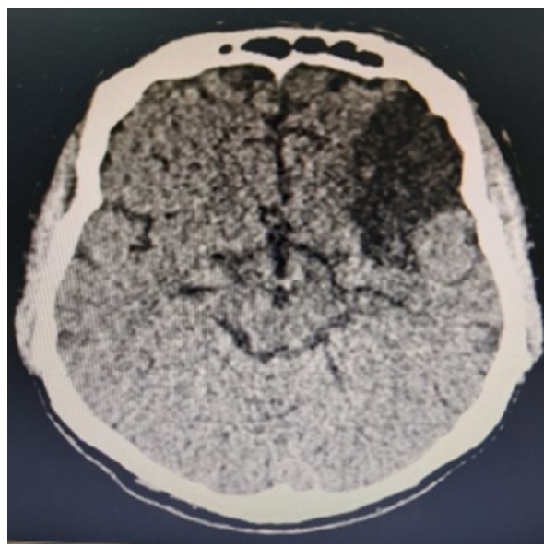
normal. Chest X-ray and laboratory tests were unremarkable. TTE revealed an intra-LV mass measuring 13x20 mm in diameter, mobile, attached to medial segment of the inter-ventricular segment and suggestive of a myxoma. Left ventricular systolic function was normal, with an LVEF of 60% [Figs.3-4]. Preoperative coronary angiography showed normal arteries, apart from insignificant atheroma in the first segment of the right coronary artery. The patient was operated on under extracorporeal circulation. Post-operative course was straightforward, and anatomopathological study of the tumor confirmed the diagnosis of cardiac myxoma.



**Fig. 1-2. Echocardiographic image showing a mobile intra-VG myxoma inserted on the basal SIV**



**Fig. 3-4. Echocardiographic image showing an intra-LV myxoma measuring 13x20mm inserted on the medial segment of the SIV**



**Fig. 5. Cerebral CT scan of the 1st patient showing hypodensity in the supratentorial region corresponding to an old ischemic lesion.**

### **3. DISCUSSION**

Primary tumors of the heart are rare. Their frequency is around 0.02%. Over 75% are benign. In adults, 85% are myxomas, lipomas or papillary fibroelastomas. The benign histological character of myxoma, which accounts for around 50% of these tumours, is accepted by all authors. The tumor develops from embryonic remnants sequestered mainly in the oval fossa of the interatrial septum (IAS). The preferred site of implantation is the SIA OG (75%) and OD (18%) [6]. According to the literature, the most frequent clinical signs are dyspnea and syncope, while signs of embolism are present in only 11% of cases [7]. Very frequently, the embolism is destined for the brain, producing transient or permanent ischemic strokes. Some myxomas may give rise to systemic signs with secretion of inflammatory mediators into the bloodstream (Interleukin6) responsible for weight loss fever, elevated sedimentation rate, anemia and hyperleukocytosis [8]. The clinical presentation of our first patient was an ischemic stroke complicated by hemiplegia and persistent aphasia. The initial etiological work-up suggested infective endocarditis, given the proximity of the mass to the mitral valve and the inflammatory biological signs. The patient was treated with antibiotics before being transferred to our center, where the diagnosis was rectified. In the second patient, atypical precordialgia was reported. Echocardiography has the highest sensitivity and specificity for the diagnosis of intracavitary tumors. It can also assess left ventricular function, as well as the size, shape, structure,

mobility and area of insertion of the tumor pedicle. Eight out of ten myxomas are located in the left atrium, and in 60% of cases their insertion is on the left side of the fossa ovale. Ten percent of myxomas are located in the right atrium, 3% in the left ventricle and 5% in the right ventricle. Exceptionally, myxomas may be found on the aortic or pulmonary sigmoid. In our two patients, the mass adhered to the interventricular septum. Although the diagnosis of myxoma is most often made on echocardiographic examination, it can be difficult to differentiate it from a thrombus or vegetation [9-10].

CT and MRI scans provide a good assessment of extra-cavitary tumor involvement, although they can also visualize intra-cavitary lesions. They also allow exploration of the mediastinum and structures close to the heart and pericardium. Coronary angiography should be performed in patients at risk of coronary lesion, or when coronary involvement by the tumor is suspected. Neurological complications of cardiac myxomas can be detected by cerebral CT scan in the case of ischemia or cerebral hemorrhage, and by MRI angiography in the case of cerebral aneurysms [11]. In our two patients, diagnosis was limited to echocardiography. Cerebral CT confirmed the ischemic nature of the stroke in the 1st patient and showed the absence of cerebral embolic complications in the 2nd. Tumours on the left side of the heart require urgent surgical intervention, due to the imminent danger of embolism and sudden death from the risk of tumour entrapment in the LV outflow tract. Tumor resection requires the patient to be placed on

extracorporeal circulation and the aorta to be clamped; this is the treatment recommended by most authors [11]. Histologically, polygonal cells with eosinophilic cytoplasm are the pathognomonic myxomatous cells of this tumor [12-13].

The prognosis for benign cardiac tumors is excellent in the vast majority of cases, with complete, curative resection. Recurrence may be due to incomplete resection, embolism of highly friable tumour fragments during extraction, or unidentified multifocal tumours [14].

In our patients, the operation went smoothly. The post-operative course was favorable, and no complications were noted during the post-operative stay.

#### **4. CONCLUSION**

Although rare, myxoma remains the most common cardiac tumor in adults, with the potential to cause severe ischemic events. Diagnosis has benefited greatly from echocardiography and cardiac imaging techniques. Despite its benign histological nature, its intra-left ventricular location is life-threatening, exposing the patient to embolic complications and sudden death, necessitating urgent surgical resection.

#### **DISCLAIMER (ARTIFICIAL INTELLIGENCE)**

Authors hereby declare that NO generative AI technologies such as Large Language Models (ChatGPT, COPILOT, etc) and text-to-image generators have been used during writing or editing of manuscripts.

#### **CONSENT**

As per international standards or university standards, patient(s) written consent has been collected and preserved by the author(s).

#### **ETHICAL APPROVAL**

As per international standards or university standards written ethical approval has been collected and preserved by the author(s).

#### **COMPETING INTERESTS**

Authors have declared that no competing interests exist.

#### **REFERENCES**

1. Centofanti P, Di Rosa E, Deorsola L, ActisDato GM, Patane F, La Torre M et al. Primary cardiac neoplasms: Early and late results of surgical treatment in 91 patients. *Ann ThoracSurg.* 1999;68:1236-41.
2. Sato, Hiroataka, Kei Aizawa, ArataMuraoka, HirohikoAkutsu, Yoshio Misawa. Cardiac angiosarcoma of the right atrium with cardiac tamponade. *Journal of Advances in Medicine and Medical Research.* 2015;12(5):1-5. Available:<https://doi.org/10.9734/BJMMR/2016/22051>.
3. Dounia, Jama, Haless Kamal, SelmaouiMarouane, HaboubMeryem, HabbalRachida, DrighilAbdenasser, Azzouzi Leila. A rare case of osteosarcoma metastasizing to the heart in a 30-year-old woman. *Asian Journal of Cardiology Research.* 2023;6(1):341-47. Available:<https://journalajcr.com/index.php/AJCR/article/view/177>.
4. Reece IJ, Cooley DA, Frazier OH, Hallman GL, Powers PL, Montero CG. Cardiac tumors: Clinical spectrum and prognosis of lesions other than classical benign myxoma in 20 patients. *The Journal of Thoracic and Cardiovascular Surgery.* 1984;88(3):439-46.
5. Kumar N, Agarwal S, Ahuja A, Das P, Airon B, Ray R. Spectrum of cardiac tumors excluding myxoma: Experience of a tertiary center with review of the literature. *Pathology-Research and Practice.* 2011, Dec 15;207(12):769-74.
6. Pinede L, Duhaut P, Loire R. Clinical presentation of left atrial cardiac myxoma: A series of 112 consecutive cases. *Medicine.* 200;80:159-72.
7. Robert JH, Denton A, Colley. *Heart Tumors.* In: Hurst JW, editor. *The heart.* Paris: Masson. 1985;1330–50.
8. Wilson SC, Frederick JS, Eugene B. Primary tumors of the heart. In: Eugene B, editor. *Treatise on cardiovascular medicine.* Padua: PaccinNuovaLibreria. 2000;2037–56.
9. Pinede L, Duhaut P,Loire R. Clinical presentation of left atrial cardiac myxoma: A series of 112 consecutive cases. *Medicine.* 2001;80:159—72.
10. Sarjeant JM, Butany J, Cusimano RJ. Cancer of the heart: Epidemiology and management of primary neoplasms and metastases. *Am J Cardiovasc Drugs.* 2003;3:407-21.
11. Perrouty, Bruno. Neurological complications of cardiac myxomas. *Diss. Montpellier.* 1988;1.

12. Cooley DA, Reardon MJ, Frazier OH, Angelini P. Human cardiac explantation and autotransplantation: Report of a case. *Tex Heart Inst J.* 1985;12:171-6.
  13. Pavie A, Gandjbakhch I, Hallali P, Bors V. Surgical treatment of intracardiac masses. *Heart.* 1984;15:31-42.
  14. Gowdamarajan A, Michler RE. Therapy for primary cardiac neoplasms: Is there a role for heart transplantation? *Curr Opin Cardiol.* 2000;15:121-5.
-