

Case Report

Drug-induced Cornea verticillata: A report of 2 cases

ABSTRACT:

Cornea verticillata is caused by the deposition of drugs, metabolic substrates, or disease byproducts in the basal epithelial layer of the cornea, it is most associated with amiodarone and Fabry disease. It can also be caused by a variety of other drugs, the most common of which are: Chloroquine and Hydroxychloroquine, Indomethacin, Phenothiazines.

We report two cases of drugs induced cornea verticillata, one secondary to prolonged intake of amiodarone and the other to amiodarone and hydroxychloroquine, to understand its pathophysiology, describe its clinical classification and discuss its treatment.

The medications that cause this pathology have similar cationic and amphiphilic characteristics that enable them to penetrate the cornea's basal epithelial layer lysosomes and attach to cellular lipids there. These drug-lipid complexes build up as deposits in the cornea and are resistant to enzymatic breakdown. **The deposits are generally not visually significant and generally disappear with the cessation of the causative agent. Several case reports have described resolution of whorled cornea with the use of topical heparin.**

Keywords: Cornea verticillata, amiodarone, Hydroxychloroquine.

1. INTRODUCTION :

Cornea verticillata (also called vortex keratopathy, verticillium keratopathy, or Fleischer's vortex) describes a whorl-like pattern of golden-brown or gray opacities in the corneal epithelium. It is called cornea verticillata from the Latin name "verticillus", which means "whorl".

“Usually asymptomatic, it is caused by the deposition of drugs, metabolic substrates, or disease byproducts in the basal epithelial layer of the cornea. Whorled cornea is most associated with amiodarone and Fabry disease”[1].

It can also be caused by a variety of other drugs, the most common of which are: Chloroquine and Hydroxychloroquine, Indomethacin, Phenothiazines[2 - 3].

Objective:we report two cases of drugs induced cornea verticillata, one secondary to prolonged intake of amiodarone and the other to amiodarone and hydroxychloroquine, to understand its pathophysiology, describe its clinical classification and discuss its treatment.

2. CASE REPORTS:

Case 1:

A 57-year-old male with a known history of atrial fibrillation and hypertension. Under amiodarone 200 mg/d for 7 years, which presents a slight bilateral and progressive decrease in visual acuity evolving for 1 year:

The ophthalmological examination finds:

A BCVA (**best corrected visual acuity**) at 20/20 in both eyes.

Corneal deposits at the level of the basal epithelium which form a faint golden brown verticillate pattern evident in both eyes (related to a Cornea verticillata) = some inferior linear deposits (*Grade 1*) (**Fig. 1**).

The rest of the exam is unremarkable.

Case 2:

A 65-year-old woman with a known history of atrial fibrillation and rheumatoid arthritis. Under amiodarone 200mg/day for 5 years and Hydroxychloroquine 200 mg/day for 10 years which presents a bilateral and progressive decrease in visual acuity evolving for 6 months:

The ophthalmological examination finds:

A BCVA (**best corrected visual acuity**) at 20/40 in the Right eye and 20/30 in the left one.

Corneal deposits at the level of the basal epithelium which form a slight golden brown verticillate pattern evident in both eyes (related to a Cornea verticillata) = cat's whisker appearance (*Grade 2*) (**Fig. 2**).

A bilateral cortico-nuclear cataract.

The rest of the exam is unremarkable.

3. DISCUSSION:

“Our 2 cases, developed classic corneal whorls following the use of amiodarone and hydroxy-chloroquine. Cornea verticillata results from the centripetal migration

of deposition-laden limbal stem cells as the corneal epithelium undergoes natural growth and repair”[4].

“The drugs that produce this pathology share cationic and amphiphilic properties that allow them to enter the lysosomes of the basal epithelial layer of the cornea, where they bind to cellular lipids. These drug-lipid complexes resist enzymatic degradation and accumulate as deposits in the cornea”[2]. “Specifically, amiodarone and hydroxy chloroquine inhibit lysosomal phospholipase A2”[5 - 6].

At an effective tissue concentration, 100% of patients will present after six months of treatment with amiodarone with bilateral corneal involvement. Regarding hydroxychloroquine, a cumulative dose greater than 1000 grams, a treatment duration greater than 5 years or a daily dose greater than 400 mg/day or 6.5 mg/kg/day increases the risk of corneal and retinal toxicity.

“Cornea verticillata is seen in 90% of patients with Fabry disease, a rare X-linked recessive lysosomal storage disorder, which is also associated with progressive nephropathy and peripheral neuropathy. In Fabry disease Cornea verticillata is caused by a deficiency of alpha-galactosidase A, a lysosomal enzyme. This leads to the accumulation of glycosphingolipids in lysosomes in all body tissues, including the cornea”[7 - 8].

UNDER PEER REVIEW

“Patients with Cornea verticillata usually do not have visual problems or eye discomfort. Rarely, patients may see blue-green rings in their vision or halos around lights”[2].

“Corneal whorls are recognizable by fine golden-brown or gray opacities in the basal epithelium that branch out from a central whorl, usually through the inferior cornea. The deposits do not stain and are almost always bilateral”[9]. Three grades have been described: some inferior linear deposits (*Grade 1*); appearance like cat's whiskers at (*Grade 2*); swirling appearance occupying most of the cornea in (*Grade 3*) [10 - 11].

“If cornea verticillata is associated with a drug that is known to produce retinal toxicities (most notably hydroxychloroquine, chloroquine, chlorpromazine, and tamoxifen), patients should be routinely monitored with automated visual fields plus spectral-domain optical coherence tomography”[12]. “The presence of cornea verticillata does not correlate with retinal toxicity”[13]. “The possibility of optic neuropathy should also be considered if patients taking amiodarone or tamoxifen present with reduced vision. For these patients, a reduction in dose or a switch to a different medication may be necessary”[14].

“There is no recommended treatment for Cornea verticillata. The deposits are generally not visually significant and generally disappear with the cessation of the

causative agent. No change in medication regimen or other workup is necessary for an isolated finding of Cornea verticillata”[2].Several case reports have described resolution of whorled cornea with the use of topical heparin[15].

4. CONCLUSION:

Amiodarone and Fabry disease are the conditions most commonly linked to cornea verticillata, which is a condition when medications, metabolic substrates, or disease byproducts are deposited in the basal epithelial layer of the cornea. Numerous other medications can also be the cause, the most popular being hydroxychloroquine (chloroquine and its hydroxychloroquine), indomethacin, and phenothiazines. There isn't a suggested course of action for Cornea verticillata. The deposits usually vanish when the causative agent is stopped and are not visibly noticeable. Topical heparin has been reported to resolve whorled cornea in a number of case reports.

Authors' contributions:

This work was carried out in collaboration among all authors. All authors read and approved the final manuscript.

UNDER PEER REVIEW

CONSENT:

As per international standards or university standards, patient(s) written consent has been collected and preserved by the author(s).

ETHICAL APPROVAL:

As per international standards or university standards written ethical approval has been collected and preserved by the author(s).

COMPETING INTERESTS:

Authors have declared that no competing interests exist.

Disclaimer (Artificial intelligence)

Option 1:

Author(s) hereby declare that NO generative AI technologies such as Large Language Models (ChatGPT, COPILOT, etc) and text-to-image generators have been used during writing or editing of manuscripts.

FIGURES:

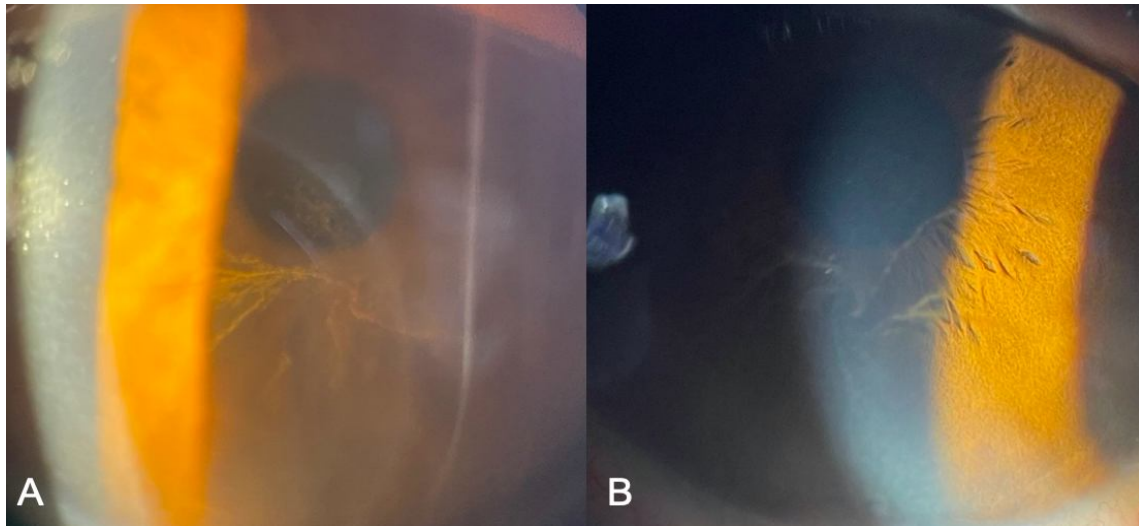


Figure 1: (A – Right eye, B – Left eye): Corneal deposits at the level of the basal epithelium which form a faint golden brown verticillate pattern evident in both eyes (related to a Cornea verticillata) = some inferior linear deposits (*Grade 1*).

UNDER PEER REVIEW

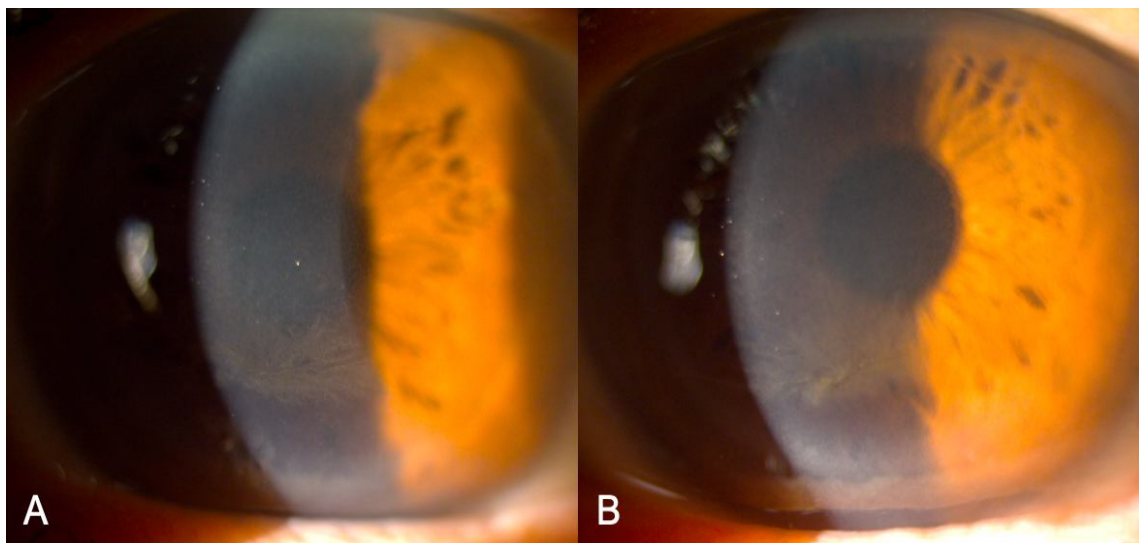


Figure 2: (A – Right eye, B – Left eye): Corneal deposits at the level of the basal epithelium which form a slight golden brown verticillate pattern evident in both eyes (related to a Cornea verticillata) = cat's whisker appearance (*Grade 2*).

REFERENCES:

1. Koh S, Hamano T, Ichii M, Yatsui K, Maeda N, Nishida K. Transient Cornea Verticillata of Unknown Etiology. *Cornea*. 2019; 38 (5): e16–e17. doi: 10.1097/ICO.0000000000001913.
2. Raizman M. B., Hamrah P., Holland E. J., Kim T., Mah F. S., Rapuano C. J., & Ulrich R. G. (2017). Drug-induced corneal epithelial changes. *Survey of ophthalmology*, 62(3), 286–301. 10.1016/j.survophthal.2016.11.008.
3. Wu JH, Chang SN, Nishida T, Kuo BI, and Lin JW. Intraocular pressure-lowering efficacy and ocular safety of Rho- kinase inhibitor in glaucoma: a meta- analysis and systemic review of prospective randomized trials. *Graefe's Arch. Clin. Exp. Ophthalmol*. Sept 7 2021. Pub online.
4. Bron AJ. Vortex patterns of the Corneal epithelium. *Trans ophthalmol SOC UK*. 1973; 93(0):455-72.
5. Sahyoun JY, Sabeti S, Robert MC. Drug-induced corneal deposits: an up-to-date review. *BMJ Open Ophthalmol* 2022;7(1):e000943. DOI: 10.1136/bmjophth-2021-000943.
6. Sahyoun, J.Y., Sabeti, S. & Robert, M.C. Drug-induced corneal deposits: an up-to-date review. *BMJ Open Ophthalmol* 7, e000943 (2022).
7. D'Amico DJ, Kenyon KR. Drug-induced lipidoses of the cornea and conjunctiva. *Int Ophthalmol*. 1981;4(1-2):67-76. doi:10.1007/BF00139581
8. Eng CM, Germain DP, Banikazemi M, et al. Fabry disease: guidelines for the evaluation and management of multi-organ system involvement. *Genet Med*. 2006;8(9):539-548. doi:10.1097/01.gim.0000237866.70357.c6
9. Sodi A, Ioannidis A, Pitz S. Ophthalmological manifestations of Fabry disease. In: Mehta A, Beck M, Sunder-Plassmann G, editors. *Fabry Disease: Perspectives from 5 Years of FOS*. Oxford: Oxford PharmaGenesis; 2006. Chapter 26. PMID: 21290696.
10. Kaplan LJ, Cappaert WE. Amiodarone keratopathy. Correlation to dosage and duration. *Arch Ophthalmol*. 1982 Apr;100(4):601-2. doi: 10.1001/archophth.1982.01030030603011. PMID: 7073573.
11. Orlando RG, Dangel ME, Schaal SF. Clinical experience and grading of amiodarone keratopathy. *Ophthalmology*. 1984 Oct;91(10):1184-7. doi: 10.1016/s0161-6420(84)34165-3. PMID: 6514284.
12. Chhablani J. Drug induced maculopathy. *American Academy of Ophthalmology, EyeWiki*. December 2018. https://eyewiki.aao.org/Drug_induced_maculopathy. Accessed June 19, 2019.
13. Marmor MF, Kellner U, Lai TY, Melles RB, Mieler WF; American Academy of Ophthalmology. Recommendations on Screening for Chloroquine and Hydroxychloroquine Retinopathy (2016 Revision). *Ophthalmology*. 2016;123(6):1386-1394. doi:10.1016/j.ophtha.2016.01.058
14. Ding HJ, Denniston AK, Rao VK, Gordon C, Hydroxychloroquine-related retinal toxicity, *Rheumatology*, Volume 55, Issue 6, June 2016, Pages 957–967.
15. Frings A, Schargus M. Recovery From Amiodarone-Induced Cornea Verticillata by Application of Topical Heparin. *Cornea*. 2017 Nov;36(11):1419-1422.