

Role of Computed Tomography Imaging in evaluation of pediatric congenital and developmental skeleton disorder

ABSTRACT

Introduction: Pediatric congenital and developmental disorders is common nowadays. That particularly occurs due to error in normal development of organ and tissue development. Genetic disorders affecting skeleton comprise a large group of clinically distinct and genetically heterogeneous condition. Clinical manifestations range from only mild growth retardation to lethality. Although these are rare, disorders of skeleton are of clinical relevance because of their overall frequency. Skeleton disorders have been subdivided into dysostosis, defined as malformation of bone or groups of bones and osteochondrodysplasia, developmental disorders of chondro-osseous tissue. **CT (computed tomography)** Scan have important role in diagnosis, specially 3D CT has added advantage in identifying bony architecture.

Aim: To evaluate the role of CT imaging in diagnosis of pediatric skeleton disorders, that further helps in management of the disorders. CT imaging has advantage like easily available, fast, affordable compared to MRI. So, in most of skeleton disorders CT is diagnosis of choice, bony abnormality can be better evaluated. 3DCT has good bone architecture differentiation, that helps in further management.

Material and Methods: Five case reports of pediatric congenital and developmental skeleton disorders have been discussed.

All the five patients underwent CT scan on Philips brilliance 256 slice machine. CT imaging findings with 3D Reconstruction have been described.

Conclusion: CT imaging is most important modality for diagnosis as well as severity of skeleton disorders and that helps in further management of child and reduce or prevent disability.

*Keywords: pediatric congenital and developmental skeleton disorder; **CT (computed tomography), 3D (three dimensional).***

1. INTRODUCTION

“Pediatric congenital and developmental disorders is common nowadays. That particularly occurs due to error in normal development of organ and tissue development. Genetic disorders affecting skeleton comprise a large group of clinically distinct and genetically heterogeneous condition. Clinical manifestations range from only mild growth retardation to lethality. Although these are rare, disorders of skeleton are of clinical relevance because of their overall frequency” [1].

Skeleton disorders have been subdivided into **dysostosis**, defined as diseases of mesenchymal bone formation in the appendicular skeleton are characterized by overrepresentation or a partial or complete absence of one or more bone elements. Patients usually present with a limb deformity and a severe, often non-weight-bearing lameness and **osteochondrodysplasia or skeletal dysplasia**, is a disorder of the development of bone and cartilage leading to skeletal maldevelopment, often short-limbed dwarfism.

CT (computed tomography) scan have important role in diagnosis, specially 3D CT has added advantage in identifying bony architecture.

Fibrous dysplasia: "It is a benign intramedullary fibro-osseous lesion. It is bone anomaly characterized by replacement of normal marrow bone by fibrous tissue that contains a newly formed mineralized product. About 3% patients associated with skin pigmentation and hyper functioning endocrine disorders known as a McCune Albright syndrome. CT imaging, which delineates morphological changes in bone, is modality of choice and superior to x rays" [3].

Developmental dysplasia of hip refers to abnormal relation of femoral head to acetabulum. "CT performed in patients diagnosed with DDH is important in the radiological algorithm because of the advantages as of the axial imaging feature, its capability to investigate the conformity of the femoral head to the acetabular cavity and the ability to measure rotation angles" [3].

Kyphoscoliosis means increased lateral curvature of spine with Cobb's angle >10 degree, CT has role in diagnosis and in identifying underlying bone abnormality.

Spina dysraphism means defective fusion posterior vertebral elements, leading to bifid configuration of spine. It is often considered as a most common CNS malformation. CT imaging has role in diagnosis and severity of defect, according to that further management can be done.

Osteogenesis imperfecta is heterogeneous group of congenital, non-sex linked, genetic disorders of collagen type 1 production, CT has role in identify various abnormality.

2. PRESENTATION OF CASES

Five cases of pediatric congenital and developmental skeleton disorders have been discussed.

All the patients underwent CT scan on Philips Brilliance 256 slice CT scan machine at New Civil Hospital, Surat.

All the patients were subjected to non-contrast CT in axial planes with multiplanar image reconstructions in sagittal and coronal planes wherever necessary and 3D CT.

2.1 CASE I

A 12-year-old female patient presented with chief complaints of right sided thigh pain, since 2 years macules in nape of neck since birth.

On plain radiographs, well circumscribed, radiolucent ground glass matrix with cortical thinning is seen.

On CT imaging, Expansile lytic intraosseous bony lesion which shows ground glass internal matrix with some cortical erosion noted involving right iliac bone, acetabulum, sacrum and right femur. (Fig. 1)

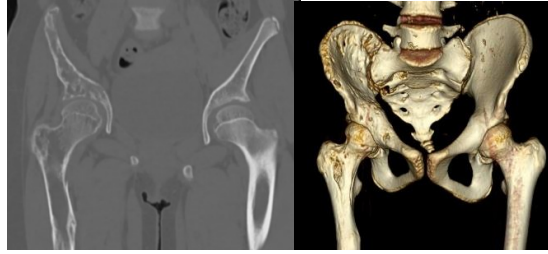

Fig. 1. Fibrous dysplasia

2.2 CASE II

An 8-year-old female patient presented with chief complains of left leg pain, shortening of left leg since birth, difficulty in walking for 5 years. On examination, trendelenberg test positive.

On CT imaging, Superior-posterior migration of head of femur noted with head noted in upper outer quadrant on left side. Discontinuity of Shenton's line noted on left side. Head of femur noted above hilgenreiner line. Epiphysis of head of femur on left side appear smaller in size. Shallow acetabulum noted on left side with fibrofatty tissue noted in acetabular fossa. (Fig. 2)

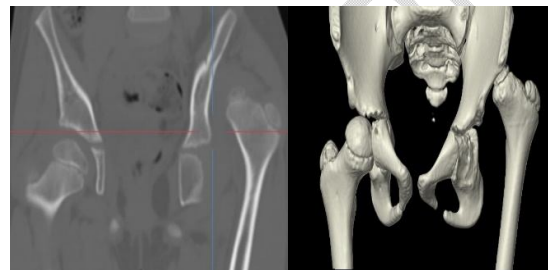

Fig. 2. Developmental dysplasia of hip

2.3 CASE III

An 11-year-old male patient presented with chief complains of deformity over back region.

On CT imaging, Severe kyphoscoliotic deformity of dorso-lumbar spine with convexity towards right side noted in lower thoracic and upper lumbar spine with crowding of ribs noted. cobb's angle measures more than 40 degree (severe kyphosis). (Fig. 3)

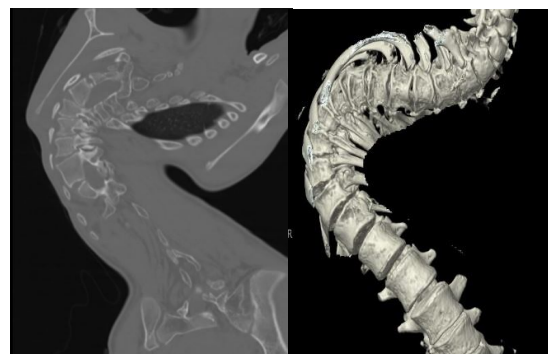

Fig. 3. Severe kyphoscoliosis

2.4 CASE IV

A 12-year-old male presented with chief complain of deformity over lower back region. Cutaneous sinus opening is also there.

On CT Imaging, Fusion of Lamina noted between L3-L4 and L4-L5 vertebrae noted on left side. cutaneous.(Fig. 4)

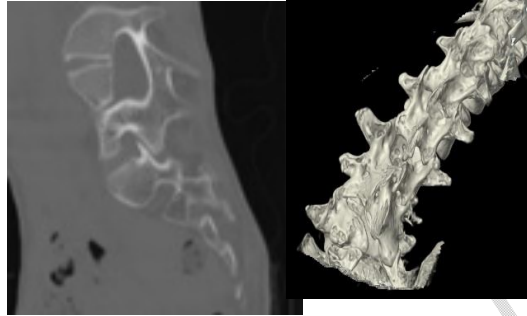


Fig. 4. Spinal dysraphism

2.5 CASE V

An 11-year-old female child presented with chief complain of deformity of lower limb and difficulty in walking since age of 3 years, multiple operations done to correct deformity and every time it develops again and further operation done.

On CT Imaging multiple non-united fractures noted involving bilateral femur with metallic implant noted in situ. (Fig. 5)

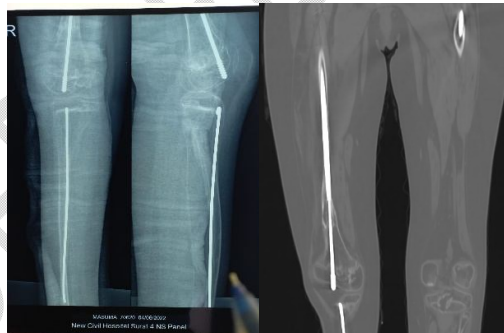


Fig. 5. Osteogenesis imperfecta

3. DISCUSSION

"A large number of genetic and developmental disorders affect the skeleton. Among the more common and more important of these is a group of inherited disorders referred to as osteogenesis imperfecta. Patients with this condition have bones that break easily (therefore, the condition is also known as brittle bone disease). There are a number of forms of osteogenesis imperfecta that result from different types of genetic defects or mutations. These defects interfere with the body's production of type I collagen. However, most osteogenesis imperfecta patients have low bone mass (osteopenia) and as a result suffer from recurrent fractures and resulting skeletal deformities" [7,8].

Fibrous dysplasia (FD) is a congenital disorder arising from sporadic mutation of the α -subunit of the Gs stimulatory protein. Osseous changes are characterized by the replacement and distortion of normal bone with poorly organized, structurally unsound, fibrous tissue. The disease process may be localized to a single or multiple bones. FD is commonly associated with McCune-Albright syndrome. On radiological imaging it shows ground glass bone matrix.

“Developmental dysplasia of the hip (DDH), is frequently seen in twins, in infants with a breech presentation and in cases of oligohydramnios. In hip dysplasia, the joint capsule and ligamentum teres are strained. The capsule may develop an hourglass shape. Fibrocartilage may enter the labrum joint and further deteriorate joint stability. Contracture develops in the iliopsoas and gluteal muscles. In the untreated hip, the probability of femoral and acetabular anteversion increases and the femoral head loses its roundness. Femoral anteversion can sometimes reach up to 60° to 90°. The bony acetabular roof flattens further, and a false acetabulum is often observed in the upper posterior aspect of the iliac wing. The femoral head migrates to the upper segment of iliac wing” [9].

“Congenital scoliosis refers to abnormal curvature of spine resulting from a congenital abnormality of the vertebra, e.g. a segmentation or fusion defect. Vertebral body segmentation and fusion defects will be visible on plain radiography. CT will usually be able to offer more detail of exact fusion patterns. Posterior element abnormalities (including fusion) will be most accurately depicted on CT” [7].

“Spinal dysraphisms (SDs) refer to a broad group of malformations affecting the spine and/or surrounding structures in the dorsum of the embryo. They are a form of neural tube defect. They are divided into two main groups: open SDs, which represent a medical emergency owing to direct environmental exposure of neural tissue, and closed SDs, in which the anomalies show skin coverage. SDs represent an important cause of childhood morbidity owing to not only neurologic impairment but also associated malformations, as in the respiratory and gastrointestinal tracts, leading to profound economic and psychosocial impact. Radiological imaging plays a pivotal role in diagnosis and presurgical evaluation of SDs” [8].

“Computed tomography (CT) plays an important role in the evaluation of congenital and developmental skeletal disorders in the pediatric patient. With the advent of high performance 256-section multidetector CT, images can be produced with sub second gantry rotation times and with submillimetre acquisition, which yields true isotropic high-resolution volume data sets; these features are not attainable with older spiral CT technology. Such capabilities are particularly helpful in the evaluation of pediatric patients by virtually eliminating the need for sedation and minimizing dependence on patient cooperation. The role of three-dimensional (3D) volume imaging in the evaluation of pediatric skeletal disorders continues to evolve, with this technique becoming increasingly important in detection and characterization of lesions as well as in decisions about patient care” [9].

4. CONCLUSION

Computed tomography (CT) imaging is most important modality for diagnosis as well as determining the severity of skeleton disorders and that helps in further management of child. Need of CT scan in child, evokes significant stress in parents, even in pediatrician also, but its important to understand that modern machine and new CT protocol optimize less radiation to child. Besides that, for certain indications and clinical settings pediatric CT always remains preferential over other modalities like MRI, e.g., assessment of cortical bone lesions, children with metal rods (e.g., after surgery for scoliosis, limb-lengthening, or osteogenesis imperfecta).

CONSENT

The informed written consent was taken from the parents/guardians of the patients.

ETHICAL APPROVAL

As per international standard or university standard written ethical approval has been collected and preserved by the author(s).

Disclaimer (Artificial intelligence)

Option 1:

Author(s) hereby declare that NO generative AI technologies such as Large Language Models (ChatGPT, COPILOT, etc) and text-to-image generators have been used during writing or editing of manuscripts.

Option 2:

Author(s) hereby declare that generative AI technologies such as Large Language Models, etc have been used during writing or editing of manuscripts. This explanation will include the name, version, model, and source of the generative AI technology and as well as all input prompts provided to the generative AI technology

Details of the AI usage are given below:

- 1.
- 2.
- 3.

REFERENCES

- 1) Kornak U, Mundlos S. Genetic disorders of the skeleton: a developmental approach. *The American Journal of Human Genetics*. 2003 Sep 1;73(3):447-74.
- 2) Bankaoğlu M. Three-dimensional computerized tomography and multiplanar imaging of developmental hip dysplasia. *ŞişliEtfalHastanesitıpBülteni*. 2019;53(2):103.
- 3) Mehany SN, Patsch JM. Imaging of pediatric bone and growth disorders: Of diagnostic workhorses and new horizons. *Wiener Medizinische Wochenschrift* (1946). 2021;171(5):102.

- 4) Kushchayeva YS, Kushchayev SV, Glushko TY, Tella SH, Teytelboym OM, Collins MT, Boyce AM. Fibrous dysplasia for radiologists: beyond ground glass bone matrix. *Insights into imaging*. 2018 Dec;9:1035-56.
- 5) Trapp B, de Andrade LourençãoFreddi T, de Oliveira Morais Hans M, Fonseca Teixeira Lemos Calixto I, Fujino E, Alves Rojas LC, Burlin S, Cerqueira Costa DM, Carrete Junior H, Abdala N, TobaruTibana LA. A practical approach to diagnosis of spinal dysraphism. *Radiographics*. 2021 Mar;41(2):559-75.
6. Trapp B, de Andrade LourençãoFreddi T, de Oliveira Morais Hans M, Fonseca Teixeira Lemos Calixto I, Fujino E, Alves Rojas LC, Burlin S, Cerqueira Costa DM, Carrete Junior H, Abdala N, TobaruTibana LA. A practical approach to diagnosis of spinal dysraphism. *Radiographics*. 2021 Mar;41(2):559-75.
- 7) Kim H, Kim HS, Moon ES, Yoon CS, Chung TS, Song HT, Suh JS, Lee YH, Kim S. Scoliosis imaging: what radiologists should know. *Radiographics*. 2010 Nov;30(7):1823-42.
- 7) Chatterjee AD, Hassan K, Grevitt MP. Congenital kypho-scoliosis: a case of thoracic insufficiency syndrome and the limitations of treatment. *European Spine Journal*. 2012 Jun;21:1043-9.
- 8)US Department of Health and Human Services. Bone health and osteoporosis: a report of the Surgeon General. Rockville, MD: US Department of health and human Services, office of the surgeon General. 2004 Oct 14;87.
- 9)Zonoobi D, Hareendranathan A, Mostofi E, Mabee M, Pasha S, Cobzas D, Rao P, Dulai SK, Kapur J, Jaremko JL. Developmental hip dysplasia diagnosis at three-dimensional US: a multicenter study. *Radiology*. 2018 Jun;287(3):1003-15.