

## Case report

# HYSTEROTOMY AND MYOMECTOMY FOR RETAINED PLACENTA IN A UTERUS: A CASE REPORT

### **Abstract.**

Retained placenta is a common complication, especially in mid-trimester miscarriage. However, when it is further complicated by the presence of multiple fibroids negating removal through the vaginal route, it becomes a problematic finding necessitating laparotomy for both myomectomy and removal of the placenta. A 36-year-old G3P0<sup>+2</sup> who had a miscarriage at 19 weeks 5 days gestation had a retained placenta with failed attempts at manual removal due to multiple uterine fibroids. She eventually had a hysterotomy and myomectomy with satisfactory results. This case highlights one of the several complications of fibroids coexisting with pregnancy and its management.

**Keywords:** Retained Placenta; Laparotomy; Hysterotomy; Myomectomy.

### **Introduction**

Uterine leiomyomas are common tumours seen in 20-50% of women of reproductive age and can be seen in 3-12% of pregnant women.<sup>1,2,3</sup> Most women with fibroids have uneventful pregnancies, however, uterine fibroids have been linked to an increased risk of spontaneous abortion, fetal malpresentation, placenta previa, preterm birth, cesarean section, postpartum hemorrhage, retained placenta etc.<sup>3,4</sup> Retained placenta after vaginal delivery is diagnosed when a placenta does not spontaneously deliver within 18–60 mins.<sup>5,6</sup> Risk factors for retained placenta include prolonged oxytocin use, high parity, preterm delivery, history of uterine surgery, and IVF conceptions, history of a prior retained placenta, and congenital uterine anomalies.<sup>6,7,8</sup> The management entails manual removal of the placenta with adequate analgesia, as medical intervention alone has not been proven effective. Sometimes, both medical and manual removal are not effective in evacuation of the uterus, especially when there is a huge cervical or lower uterine segment fibroid nodule obstructing access into the uterine cavity as may have occurred in this patient. For such patients, a hysterotomy for uterine evacuation and concomitant myomectomy. may be required.<sup>9</sup>

### **Case Report**

The patient was a 36-year-old Gravida3 Para 0+2 at 19 weeks 5 days gestation who presented at the gynaecology emergency with a complaint of drainage of liquor of 3 days duration. There was no prior history of trauma, associated fever, or urinary tract symptoms. The index pregnancy was booked and an early ultrasound revealed coexisting uterine fibroids. She was also a known hypertensive on treatment. On examination, she was afebrile, not pale (PCV – 28%) with a blood pressure of 150/90mmHg. Abdominal examination revealed a uterus of 27 weeks' size which was nodular and non-tender. A pelvic exam showed an open cervix with bulging membranes. She shortly had a spontaneous expulsion of a male abortus weighing 420g. After intramuscular administration of 10iu oxytocin, an attempt was made to deliver the placenta via controlled cord traction (CCT) which failed with the cord snapping. Eight hundred micrograms of misoprostol were inserted rectally and a manual removal was attempted. However, the cervical canal had reduced. Attempt at using long sponge-holding and ovum forceps also failed as the uterus was very bulky making it impossible to reach the fundally placed placenta. There was no active bleeding per vaginam and she was stable.

After she was counseled, four units of blood were crossmatched and she was scheduled for elective laparotomy the next morning. Laparotomy revealed a bulky uterus about 22 weeks in size, multiple (subserous, submucous, and intramural) uterine fibroids were found with the largest measuring approximately 8 by 10cm (Figures 1 and 5), a fundally placed placenta weighing 0.1kg (Figures 2 and 5) with uterine fibroid nodules on both the anterior and posterior body of the uterus below the placenta site. This finding corroborates the earlier unsuccessful attempts at manual removal of the placenta through the vagina. She had a hysterotomy with removal of the placenta and myomectomy of 31 fibroid nodules (Figure 5). The uterus was meticulously closed in layers. The estimated blood loss of 4,500ml and she was transfused six units of blood intraoperatively and another two in the ward. The abdomen was closed in layers and the recovery was uneventful. She was discharged seven days later and was reviewed after two weeks with no fresh complaints. She started menstruating 2 months after the surgery.

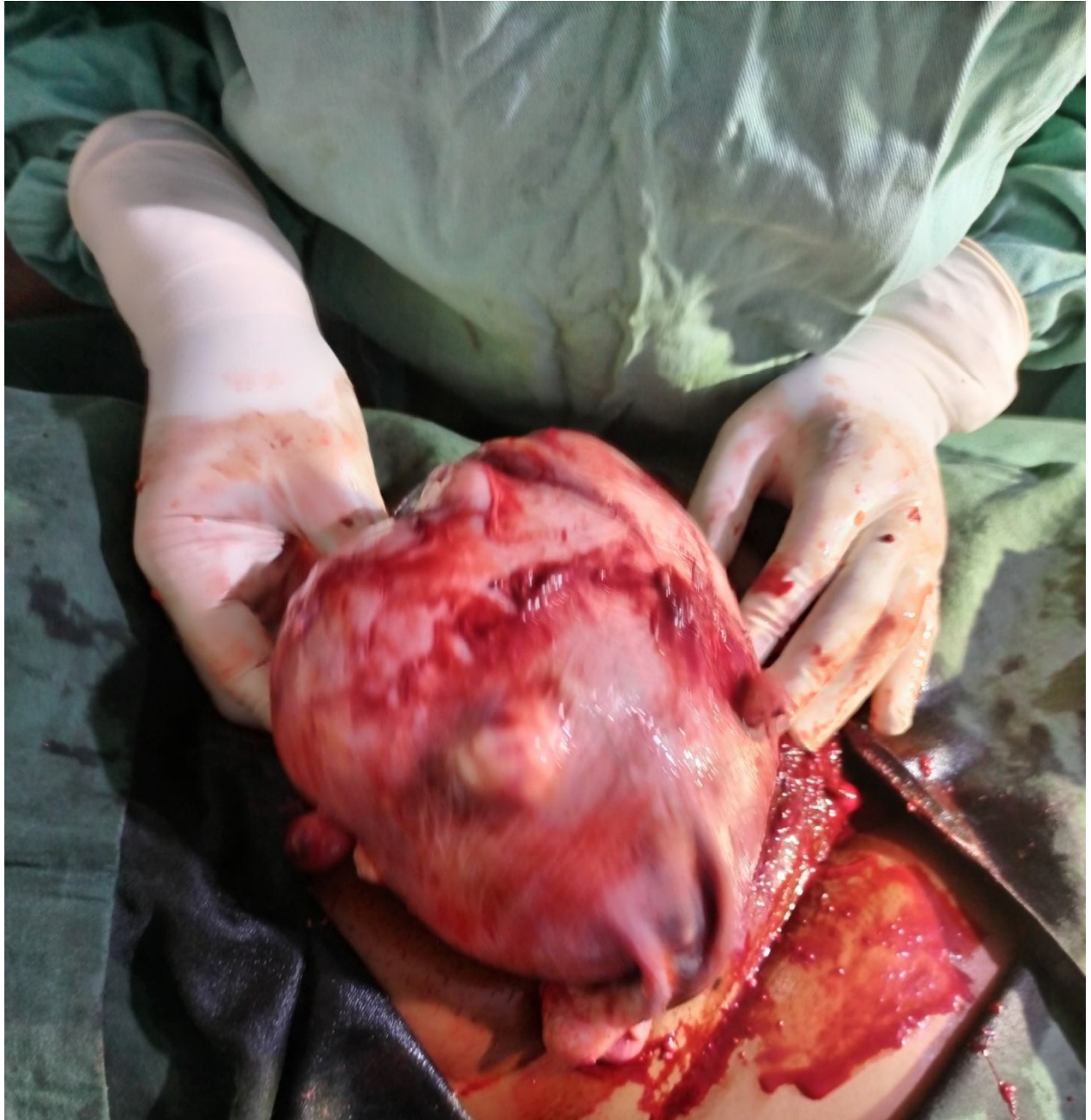

Fig. 1. Showing the uterus (full of fibroid seedlings) as it was exteriorized from the abdomen.

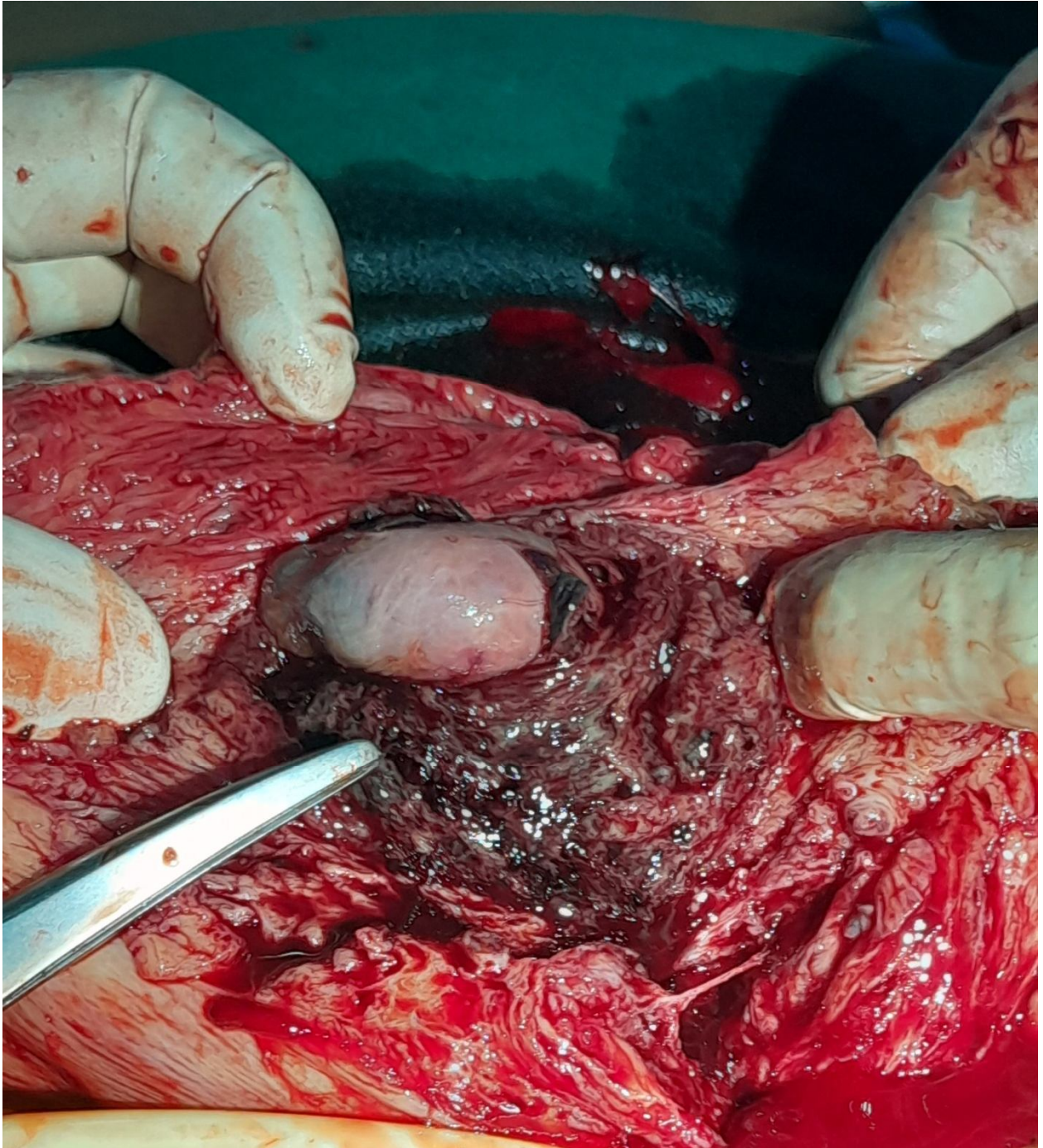


Fig. 2. Showing the fundal placed placenta with a submucous fibroid after removal of most of the of the subserous and intramural fibroids.

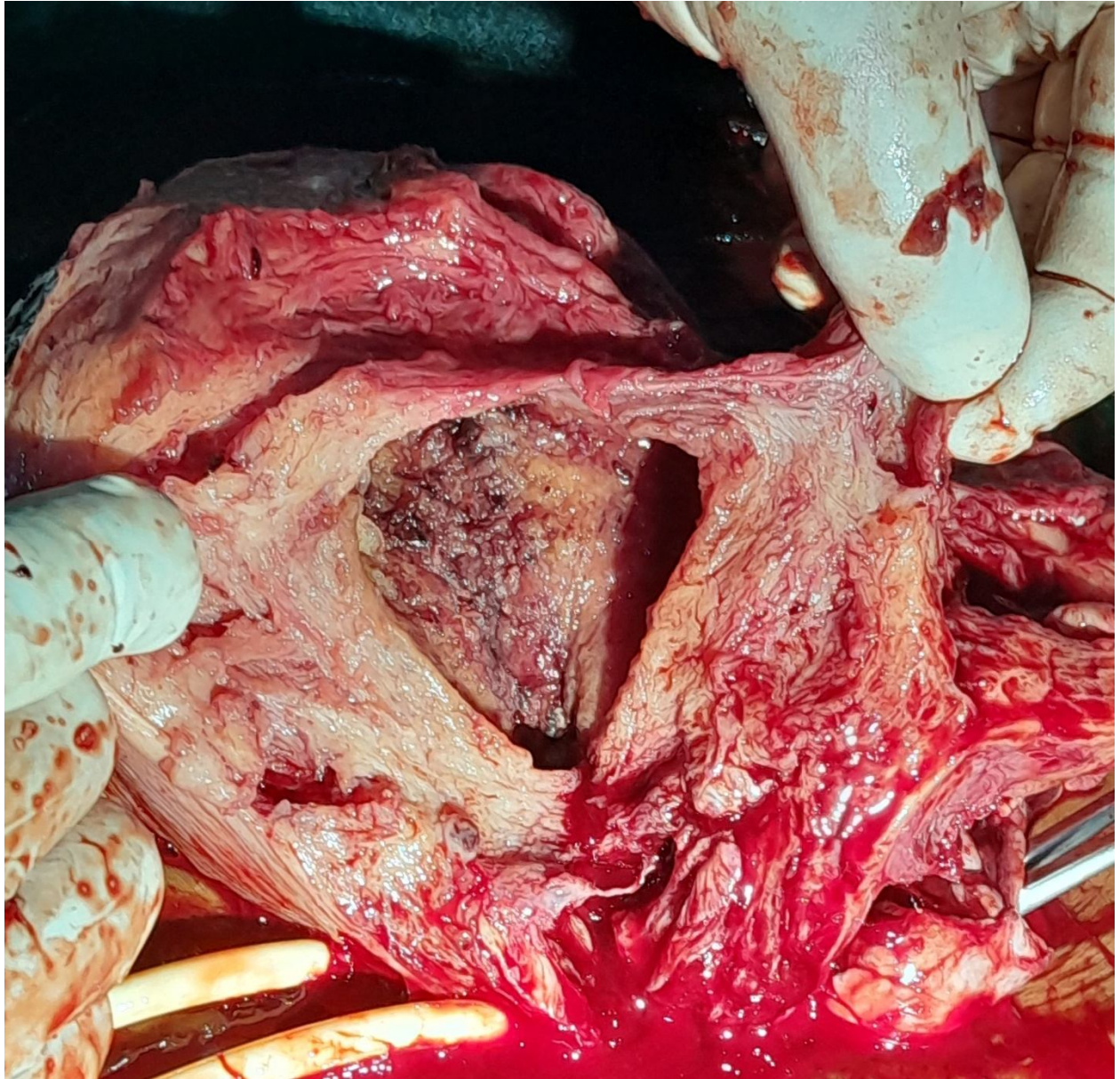


Fig. 3. Showing the base of the placenta after it was removed.

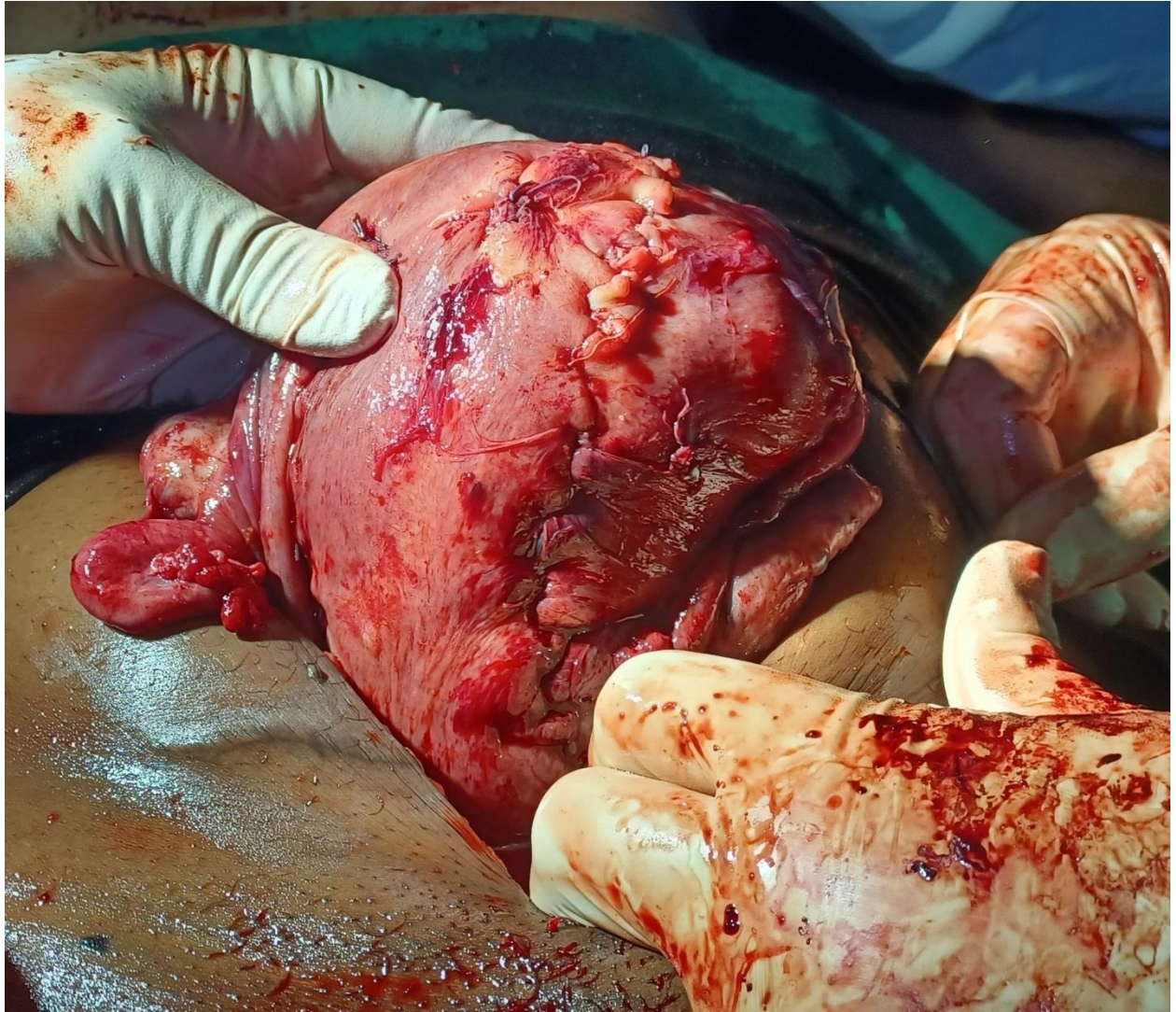


Fig. 4. Showing the repaired uterus with a grossly salvaged right uterine tube.

UNDEFIN

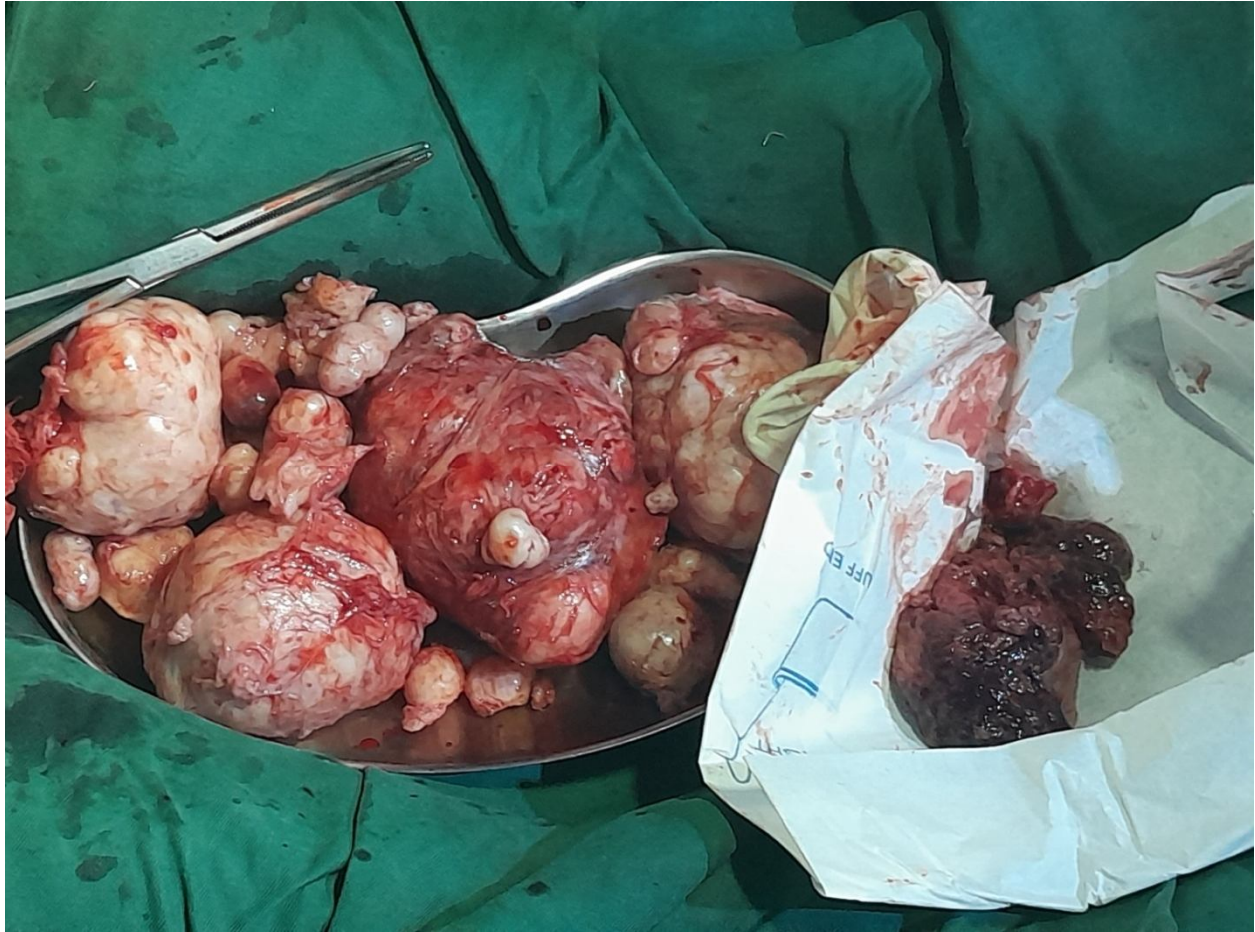


Fig. 5. Showing multiple uterine fibroid seedlings and the placenta after removal.

## Discussion

Uterine fibroids or leiomyomata are the commonest neoplasm of the female genital tract in particular, seen in 20-50% of women in the reproductive age and can be seen in 3-12% of pregnant women.<sup>1,2,3</sup> They occur predominantly in the reproductive age group with the peak age of incidence between 20 and 50 years, rarely occurring outside this age range.<sup>1,4</sup> The patient was 36 years old which was within the age at risk.

The exact aetiology of uterine fibroid is still unknown but there are well-known associated risk factors. They are more common, develop earlier, and seem to grow larger in Negroes than Caucasians<sup>1,2</sup>.

Most women with fibroids have uneventful pregnancies, however, they have been linked to an increased risk of spontaneous abortion, fetal malpresentation, placenta previa, preterm birth, cesarean section,

postpartum hemorrhage, retained placenta, etc.<sup>3,4</sup> Our patient developed preterm labour and aborted the pregnancy which may have been caused by the uterine fibroids.

Retained placenta after vaginal delivery is diagnosed when a placenta does not spontaneously deliver within 18–60 mins.<sup>5,6</sup> The patient had both uterine fibroids and preterm delivery which increased her risk for retained placenta. Uterine fibroids distort the uterine cavity or cause anomalous placental adhesion due to inflammatory changes at the area of the fibrous site, and localized retroplacental contractility failure.<sup>10</sup> Preterm birth and Intrauterine Growth Restriction (IUGR) could be closely related to retained placenta through an intrauterine inflammation in the placental site.<sup>10</sup> In this patient, since it was not difficult to deliver the placenta during the surgery, the failure to detach may be due to localized retroplacental contractility failure as a result of the uterine fibroids hindering uterine contraction. Sometimes the placenta is incarcerated by uterine fibroids after its detachment, however, in such situations, the placenta is seen to be already detached at hysterotomy.<sup>11</sup> This was not the case in this patient, though incarceration may have been a contributing factor.

The management of retained placenta involves manually removing the placenta with adequate analgesia, as medical intervention alone is not effective. Nitroglycerine (NTG) is sometimes used to relax the uterine muscles to facilitate manual extraction.<sup>6,7</sup> Some studies suggest using umbilical vein injections of prostaglandin F<sub>2α</sub> or dissolved misoprostol. However, umbilical vein injection with oxytocin has been found ineffective in a large RCT with 577 women.<sup>6</sup> These methods aim to prevent the need for a laparotomy. In the discussed patient case, these methods were not feasible due to partial cervical closure, and snapping of the umbilical cord during CCT.

If placental removal is refractory or only partially successful (i.e. the placenta or parts of the placenta remain in the uterus), or if bleeding persists despite placental delivery, often the next step is surgical management with curettage.<sup>7,8,10</sup> Where manual removal fails, the possibility of a morbidly adherent placenta should be considered and laparotomy performed.

In the case of our patient, both medical management and manual removal failed requiring a hysterotomy with concomitant myomectomy and removal of the placenta. Different forms of management of uterine fibroids are now available either singly or in combination, however the mainstay of treatment has been surgical though other adjuvant therapies may be used to complement it. Treatment must be

individualised and tailored to the woman's individual needs and aspirations.<sup>12,13,14</sup> Myomectomy in place of hysterectomy was done because she was desirous of future child bearing her future.<sup>12,15</sup> Severe haemorrhage and post-operative adhesions are the main complications of myomectomy especially during pregnancy.<sup>16,17</sup> To prevent severe hemorrhage during surgery, a rubber catheter was used to occlude the uterine arteries, and vertical midline anterior incisions were made in less vascular areas. Despite these efforts and the quickly closing the cavity, the patient required massive intraoperative transfusion due to significant bleeding. Post-operative adhesions were minimized by gentle tissue handling, use of normal saline to achieve flotation and vicryl as suture material were employed to reduce adhesions in our patient. Post-operative sepsis was prevented by the use of prophylactic antibiotics. Other methods to prevent adhesions however not used in this case include using dextran and hyscon.<sup>18,19,20</sup>

## Conclusion

Retained placenta due to uterine fibroid not amenable to manual removal through the vaginal is a rare and worrisome finding. In such situations, laparotomy with myomectomy and hysteromy for placenta removal becomes a viable alternative. This was done for our patient with satisfactory results.

## References

1. Saha MM, Mondal D, Biswas SC. Pregnancy with leiomyoma uteri and fetomaternal outcomes. *Al Ameen J Med Sci.* 2016;9(2):96-100.
2. Parazzini F, Tozzi L, Bianchi S. Pregnancy outcome and uterine fibroids. *Best practice & research Clinical obstetrics & gynecology.* 2016 Jul 1;34:74-84.
3. Radhika BH, Naik K, Shreelatha S, Vana H. Case series: pregnancy outcome in patients with uterine fibroids. *Journal of clinical and diagnostic research: JCDR.* 2015 Oct;9(10):QR01.
4. Ezzedine D, Norwitz ER. Are women with uterine fibroids at increased risk for adverse pregnancy outcomes?. *Clinical obstetrics and gynecology.* 2016 Mar 1;59(1):119-27.
5. Lee D, Johnson J. Hysterotomy for retained placenta in a septate uterus: A case report. *Case reports in obstetrics and gynecology.* 2012;2012(1):594140.
6. Perlman NC, Carusi DA. Retained placenta after vaginal delivery: risk factors and management. *International journal of women's health.* 2019 Oct 7:527-34.

7. Patrick HS, Mitra A, Rosen T, Ananth CV, Schuster M. Pharmacologic intervention for the management of retained placenta: a systematic review and meta-analysis of randomized trials. *American Journal of Obstetrics and Gynecology*. 2020 Sep 1;223(3):447-e1.
8. Grillo-Ardila CF, Ruiz-Parra AI, Gaitán HG, Rodriguez-Malagon N. Prostaglandins for management of retained placenta. *Cochrane Database of Systematic Reviews*. 2014(5).
9. Abam DS, Kasso T. Uterine fibroids and pregnancy: A review of the challenges. *Obstetrics*. 2017 Dec 20.
10. Favilli A, Tosto V, Ceccobelli M, Parazzini F, Franchi M, Bini V, Gerli S. Risk factors for non-adherent retained placenta after vaginal delivery: a systematic review. *BMC Pregnancy and Childbirth*. 2021 Dec;21(1):1-3.
11. Mbamara SU, Daniyan AB, Ejenobo O, Mbah IC. Case Report: Myomectomy for Retained Placenta Due to Incarcerated Fibroid Mass. *Annals of Medical and Health Sciences Research*. 2015;5(2):148-51.
12. Ndububa VI. Uterine fibroids: experience with 100 myomectomies in Orlu, South East Nigeria. *Port Harcourt Medical Journal*. 2016;10:124.
13. Lawal Y, Yaro IB, Rabi A, Emmanuel R. Prevalence and sonographic patterns of uterine fibroids in Northern Nigeria. *N Niger J Clin Res*. 2019;8:24.
14. Donnez J, Dolmans MM. Uterine fibroid management: from the present to the future. *Human Reproduction Update*. 2016;22:665-86.
15. Isah AD, Adewole N, Agida ET, Omonua KI. A five-year survey of uterine fibroids at a Nigerian Tertiary Hospital. *Open J ObstetGynaecol*. 2018;8:468.
16. De La Cruz MS, Buchanan EM. Uterine fibroids: diagnosis and treatment. *Am Fam Physician*. 2017;95:100-7.
17. Ekine AA, Lawani LO, Iyoke CA, Jeremiah I, Ibrahim IA. Review of the clinical presentation of uterine fibroid and the effect of therapeutic intervention on fertility. *Am J Clin Med Res*. 2015;3:9-13.
18. Ikechebelu JI, Okpala BC, Eleje GU, Nwachukwu CE, Nwajiaku LA, Nnoruka M. Delayed presentation of giant uterine fibroids in a Nigerian private specialist health facility. *SAGE Open Medical Case Reports*. 2021;9:2050313X211063137.
19. Garba I, Ayyuba R, Adewale TM, Abubakar IS. Surgical management of uterine fibroids at Aminu Kano Teaching Hospital. *Niger J Basic Clin Sci*. 2016;13:50.
20. Singh S, Thulkar T, Pawanarkar M, Thulkar J. Current practices for treatment of uterine fibroids. *J Midlife Health*. 2017;8:189.