

A Systematic Review on *Prototheca* spp. Infections in the Human Central Nervous System and Evaluation of Therapeutic Drug Approaches

ABSTRACT

Background and Aim: *Prototheca* is a genus of unicellular, non-photosynthetic microalgae found in diverse environments, including water, soil, and the intestinal microbiota of animals and humans. They are the only algae pathogenic to humans. Infections of the Central Nervous System (CNS) by *Prototheca* spp. are rare but severe. This research aims to systematically review the pathogenic potential of *Prototheca* spp. as CNS infectious agents in humans, identify underlying conditions that contribute to disease development, and evaluate the most suitable drug therapy alternatives for this clinical condition.

Methods: A systematic review was conducted using PubMed, SciELO, and Google Scholar databases. Search terms included "*Prototheca*," "Central Nervous System," "meningitis," "encephalitis," "meningoencephalitis," and "brain." Manuscripts published in English, Portuguese, Spanish, and Russian from 1981 to 2024 were reviewed.

Results: The review identified 15 case reports of CNS infections by *Prototheca* spp. described in 14 scientific articles. Three species were implicated: *Prototheca wickerhamii*, *Prototheca zopfii*, and *Prototheca trispora*, with *Prototheca wickerhamii* being the most prevalent (66.6%). Only four patients were immunocompromised. A significant association was found between hydrocephalus in children and vulnerability to CNS protothecosis, accounting for 20% of cases. All fatal cases occurred in immunocompromised patients. Resistance profile analysis showed 88.9% susceptibility to amphotericin B and susceptibility to two triazoles (voriconazole and isavuconazole) that cross the blood-brain barrier.

Conclusion: Immunodeficiency is not a prerequisite for susceptibility to CNS infections by *Prototheca* spp., but it predicts an unfavorable prognosis. The most promising treatments are combinations of amphotericin B with tetracyclines or isavuconazole. Dosage adjustments are necessary due to the toxicity of long-term algicidal antifungal treatments, posing a challenge in managing drug therapy.

Keywords: *Prototheca* spp., Protothecosis, Infections of the Central Nervous System, Drug Therapeutic Approaches

1. INTRODUCTION

The genus *Prototheca* is characterized by species of unicellular microalgae belonging to the family Chlorellaceae which lack chloroplasts and, therefore, do not have photosynthetic capability [1,2,3]. *Prototheca* algae are ubiquitously distributed in nature, found in water, soil, decomposing flora, and as part of the intestinal microbiota of animals [3,4,5,6]. It is possible that these algae belong to the gut microbiome of healthy individuals. [7,8].

Prototheca spp. are the only algae considered pathogenic to humans and animals. In animals, the disease presents with diverse clinical manifestations, such as nodular skin lesions and meningitis in felines [9,10], systemic infections in canines, cervids, bovids, equids, rodents, and fish, and primarily as a causative agent of mastitis in cows [9,11,12]. In humans, infections by *Prototheca* spp. mainly present in three clinical forms: cutaneous infections, olecranon bursitis, and disseminated or systemic infections. Cutaneous protothecosis is the most common form, representing approximately 66% of cases, and generally presents as erythematous plaques, papules, pustules, nodules, ulcers, vesicles, crusts, atrophic

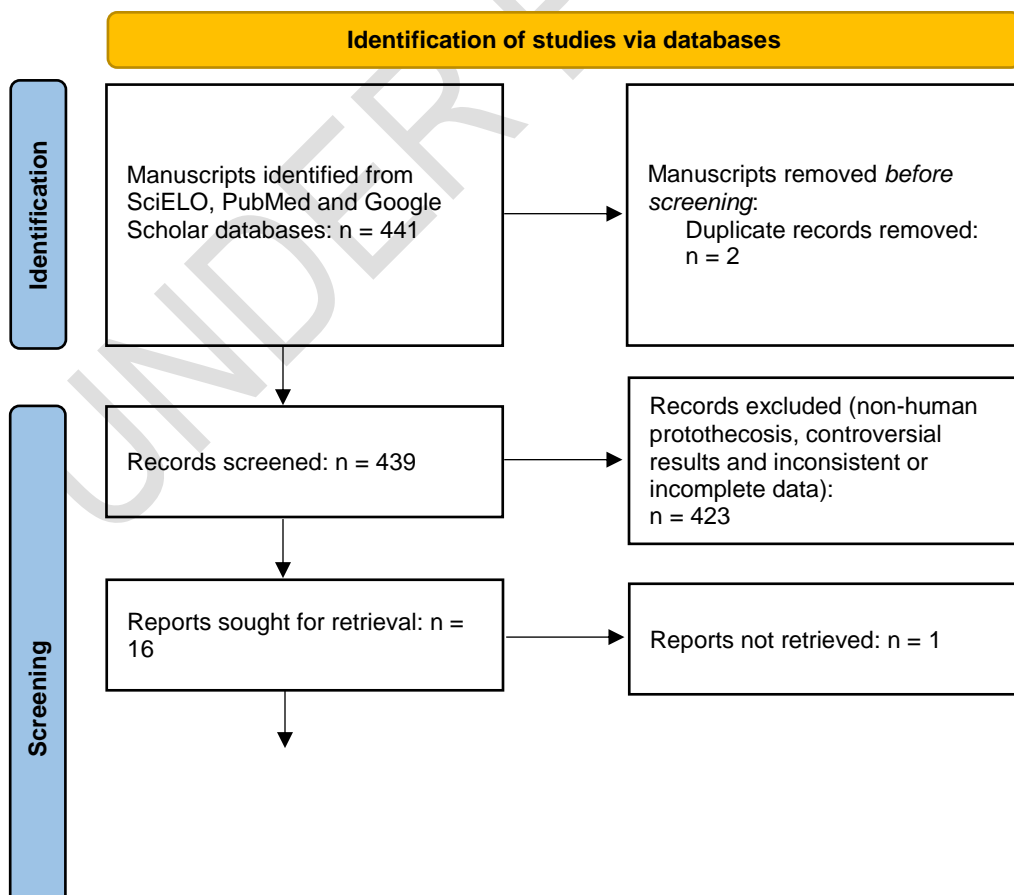
lesions, or verrucous lesions, often leading to misdiagnoses due to its variable presentation [13,14,15,16,17,99,100]. Olecranon bursitis, constituting about 15% of cases, involves inflammation of the bursa located over the olecranon region of the elbow and is frequently observed in immunocompromised individuals [13,19]. Disseminated or systemic infections represent only 19% of cases and are attributed to immunocompromised patients. Systemic infections can involve various organs, with the skin generally pointed as the first site where the infection manifests [1,18,19]. *Prototheca wickerhamii* and *Prototheca zopfii* are the main species responsible for infections in humans, with *Prototheca wickerhamii* being the most frequent species [3,20,21].

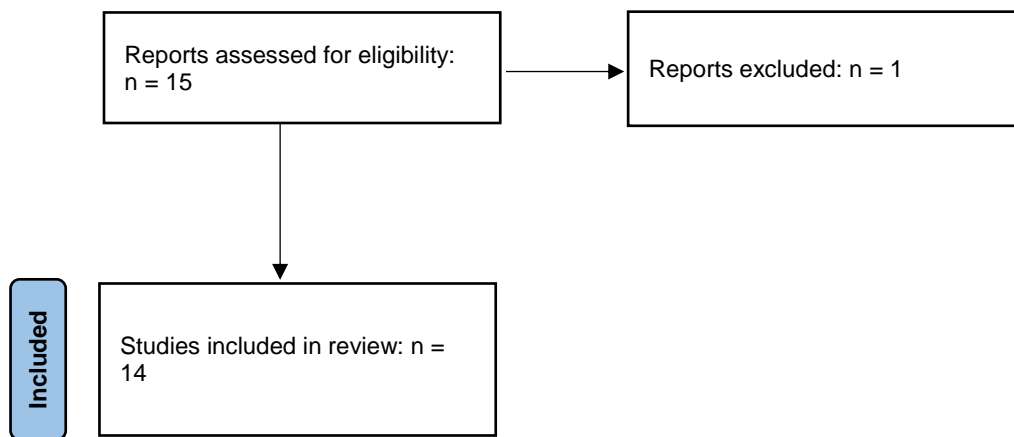
Infections by *Prototheca* spp. in the Central Nervous System are considered rare but of significant clinical importance, often posing a challenging diagnostic and therapeutic dilemma [18,22]. Wang et al. [19] estimate that only 5.5% of protothecosis cases are CNS infections. This clinical condition is frequently attributed to immunocompromised individuals [19,23]. The presence of *Prototheca* spp. in several environments and their pathogenic potential highlight the need for further research to understand their biology, pathogenic mechanisms, and to develop effective treatment strategies, particularly in severe and infrequent clinical presentations.

2. METHODS

A systematic review was conducted according to the methodological guidelines proposed by Moher et al. [24], updated by Page et al. [25], using the PRISMA model. The aim of the review was to analyze, through a systematic literature review, the pathogenic potential of *Prototheca* spp. as an infectious agent in the CNS in humans, to identify the underlying conditions involved in the development of the disease, and to evaluate the most suitable therapeutic drug options for this clinical scenario. The sources for the review included the databases PubMed, SciELO, and Google Scholar, and the search was conducted using the following descriptors: "*Prototheca*"; "Central Nervous System", "Central Nervous System", "Meningitis", "Encephalitis", "Meningoencephalitis", "Neurological Infection", "Brain". The reviewed manuscripts were published in English, Portuguese, Spanish, and Russian, from the period of 1981 to 2024. After reading the full text of each article and case report, relevant information was selected and evaluated. The most important aspects were recorded and summarized for analysis. Non-human cases of protothecosis and articles with incomplete data or controversial diagnostic interpretations were excluded. A flowchart was provided to illustrate the logic of selecting reference material for this review (Fig 1).

Fig. 1. Flowchart of the screening process of publications according to the PRISMA model.





*Source: the authors

3. RESULTS AND DISCUSSION

The systematic literature review revealed that there are currently 15 case reports of CNS infections by *Prototheca* spp. in humans, described in 14 scientific articles. A summary of the most important aspects of each case report is presented in Table 1. The profiles of antifungal resistance with algicidal action in cases where these tests were conducted are organized in Table 2.

Table 1. Key Aspects from Case Reports of Central Nervous System infections by *Prototheca* spp.

Reference	Gender	Age	Species	Clinical presentation	Comorbidities or underlying conditions	Antibiotic treatment	Outcome
Kaminski et al. [26]	Woman	25	<i>Prototheca wickerhamii</i>	Meningitis	Patient with AIDS. Meningitis caused by <i>Prototheca wickerhamii</i> and <i>Cryptococcus neoformans</i> . Oral candidiasis and exuberant herpetic lesions.	Amphotericin B, 5-flucytosine	Deceased after 5 months
Takaki et al. [27]	Man	20	<i>Prototheca wickerhamii</i>	Chronic meningitis	Systemic protothecosis with involvement of the liver, abdominal lymph nodes and ileum.	Miconazole, amphotericin B, itraconazole, fluconazole	The patient remained symptom-free more than six years after the infection and even after abandoning antifungal therapy
Sinitskaya et al. [28]	Not informed	Not informed	<i>Prototheca trispora</i>	Brain infection	Not informed	Not informed	Not informed
Zhang et al. [29]	Man	24	<i>Prototheca wickerhamii</i>	Meningitis	Immunocompetent	Amphotericin B, itraconazole	Medical discharge after 72 days
Zak et al. [30]	Man	6 months	<i>Prototheca wickerhamii</i>	Cerebrospinal infection	Ventriculoperitoneal shunt to treat hydrocephalus, removed at three months due to secondary infection by <i>Staphylococcus epidermidis</i> . Hydranencephaly. Daily lumbar punctures	Ketoconazole, fluconazole and amphotericin B	Medical discharge in approximately 2 months
Li et al. [31]	Man	23	<i>Prototheca wickerhamii</i>	Meningitis	Previous tuberculous meningitis. Use of corticosteroids. <i>Prototheca</i> meningitis aggravated by secondary infections with <i>Staphylococcus warneri</i> and <i>Staphylococcus epidermidis</i> .	Amphotericin B, flucytosine	Deceased after 11 months
Hench et al. [32]	Woman	23	<i>Prototheca zopfii</i>	Granulomatous encephalitis with severe neurological involvement	Immunocompetent	No specific treatment for protothecosis after surgical excision of granulomatous lesions	Medical discharge after 14 days
Hench et al. [32]	Man	20	<i>Prototheca zopfii</i>	Granulomatous encephalitis with severe neurological involvement	Immunocompetent	Amphotericin B, itraconazole	Medical discharge after 7 weeks
Ahn et al. [33]	Man	12	<i>Prototheca wickerhamii</i>	Eosinophilic meningoencephalitis	Communicating hydrocephalus	Amphotericin B	Medical discharge after two years

				Recurring			
Samarasekara et al. [34]	Woman	56	<i>Prototheca wickerhamii</i>	Brain infection emulating high-grade glioma	Immunocompetent	Amphotericin B	Discharge after subtle improvement, but with signs of persistent infection after 12 months
Lu et al. [13]	Man	17	<i>Prototheca wickerhamii</i>	Meningitis	Immunocompetent. Previous needling for tattooing.	Amphotericin B	Medical discharge after two months
Joerger et al. [35]	Woman	13	<i>Prototheca zopfii</i>	Chronic meningitis	Ventriculoperitoneal shunt to treat hydrocephalus. Delayed puberty. Chronic malnutrition. Recurrent systemic infection with <i>Staphylococcus aureus</i> .	Fluconazole, amphotericin B,	Discharge after subtle improvement, but with signs of persistent infection after 12 months
Herold et al. [36]	Woman	61	<i>Prototheca zopfii</i>	Encephalitis	Newly diagnosed myeloid leukemia. Diabetes mellitus. Metabolic syndrome. History of breast cancer and intestinal surgery. Secondary systemic <i>Klebsiella pneumoniae</i> and <i>Enterococcus faecium</i> . Systemic proteinosis with damage to the lungs, liver, kidneys, heart and brain	Amphotericin B	Deceased after 32 days from septic shock caused by <i>Prototheca zopfii</i>
Cross et al. [22]	Woman	55	<i>Prototheca wickerhamii</i>	Brain infection	Immunocompetent	Amphotericin B, isavuconazole, doxycycline, posaconazole, oxytetracycline	No signs of infection 18 months after diagnosis
Park et al. [37]	Not informed	<15	<i>Prototheca wickerhamii</i>	Recurrent meningitis	Immunodeficiency CARD9	Antifungal (unspecified)	Survived without neurological sequelae

*Source: the authors

Table 2. Resistance profiles of antifungal with algicidal action, indicating resistance (R), intermediate sensitivity (I), and sensitivity (S), for amphotericin B (AMB), voriconazole (VOR), isavuconazole (ISA), itraconazole (ITR), nystatin (NIS), ketoconazole (KCZ), posaconazole (PCZ), fluconazole (FLCZ), 5-flucytosine (5-FC), miconazole (MCZ), caspofungin (CFG), micafungin (MICA), and anidulafungin (AFG).

Reference	Species	AMB	VOR	ISA	ITR	NIS	KCZ	PCZ	FLCZ	5-FC	MCZ	CFG	MICA	AFG
Kaminski et al. [26]	<i>Prototheca wickerhamii</i>	S	-	-	-	-	-	-	-	R	-	-	-	-
Takaki et al. [27]	<i>Prototheca wickerhamii</i>	R	-	-	-	-	-	-	-	R	R	-	-	-
Zak et al. [30]	<i>Prototheca wickerhamii</i>	S	S	-	R	-	R	-	R	R	-	R	-	-
Li et al. [31]	<i>Prototheca wickerhamii</i>	S	-	-	-	S	-	-	-	-	-	-	-	-
Anh et al. [33]	<i>Prototheca wickerhamii</i>	S	-	-	-	-	-	-	-	-	-	R	-	-
Lu et al. [13]	<i>Prototheca wickerhamii</i>	S	S	-	-	-	-	-	-	-	-	-	-	-
Cross et al. [22]	<i>Prototheca wickerhamii</i>	S	I	S	I	-	-	I	-	R	-	R	R	R
Zhang et al [29]	<i>Prototheca wickerhamii</i>	S	-	-	R	-	I	-	R	R	-	-	-	-
Joerger et al. [35]	<i>Prototheca zopfii</i>	S	S	-	-	-	S	-	R	R	-	R	-	-

*Source: the authors

The species responsible for Central Nervous System infections in humans were *Prototheca wickerhamii* (10 cases), *Prototheca zopfii* (4 cases), and *Prototheca trispora* (1 case), with a predominance of *Prototheca wickerhamii* (66.6%). *Prototheca wickerhamii* and *Prototheca zopfii* were already recognized as agents of protothecosis in humans, being responsible for most cases of cutaneous and systemic infections. The description of *Prototheca trispora* in the cerebrospinal fluid of a patient [28] may represent the identification of another species with pathogenic potential for humans or an incidental case, deserving further research on the species infection potential. The manuscript by Sinitskaya et al. [28] which reported the case did not detail the context of the infection, the clinical course of the disease, nor patient data, focusing instead on the description of the ultrastructure and identification of the *Prototheca* species.

Encephalitis, meningitis, and meningoencephalitis caused by *Prototheca* spp. showed non-specific signs and symptoms, indistinguishable from similar infections caused by other pathogens, especially fungi. This significantly obscures the diagnosis of meningitis and encephalitis due to the overlap of symptoms with other conditions and the variability in clinical presentations. Histopathological examinations and culture of material obtained from lesions can introduce diagnostic pitfalls. The case report of cerebral infection by *Prototheca wickerhamii* mimicking high-grade glioma [34] is emblematic, demonstrating that protothecosis in the Central Nervous System can assume diverse or elusive clinical presentations and can lead to misdiagnoses. Histopathology of *Prototheca* spp. in Central Nervous System tissue can be mistaken for *Toxoplasma gondii* due to several microscopic similarities and lesion characteristics. Both infections can present granulomatous inflammations and multifocal necrotic lesions in the brain, further complicating histopathological distinction [22,34,38]. *Prototheca* sporangia can also be confused with fungal elements due to the staining method for microscopic observation, as these organisms stain positively with periodic acid-Schiff and Gomori's methenamine silver, which highlight the polysaccharides in cell walls in a manner similar to yeast-like fungal cells [39,40,41]. Cross et al. [22] reported that in the two years preceding the definitive diagnosis of cerebral protothecosis, the 55-year-old patient was treated with medication for toxoplasmosis, based on imaging studies and histopathology. Zak et al. [30] pointed out that microscopic images of *Prototheca* spp. lesions can be confused with *Coccidioides immitis* or *Rhinosporidium seeberi*, although there is a considerable size difference between *Prototheca* spp. sporangia and the endospores of these fungi.

The identification of *Prototheca* spp. as a pathogenic agent through culture of the infected material can also present diagnostic challenges. *Prototheca* spp. grow on culture media specific for fungi. Macroscopically, the appearance of *Prototheca* spp. colonies resembles that of yeasts, making them visually indistinguishable from fungal cultures, especially those of the genera *Candida* or *Cryptococcus* [6,13,30]. This confusion is even compounded by their susceptibility to antifungal agents used in antifungograms, leading to an incorrect diagnosis. It is possible that many CNS infections by *Prototheca* spp. have been misidentified as fungal infections, treated, and eventually resolved – or not – after antifungal therapy. According to Zak et al. [30], diagnosing protothecosis is not inherently difficult but requires a high degree of clinical suspicion. In this regard, diagnostic determination through more accurate methods, such as molecular tests or PCR, is absolutely necessary to confirm or exclude *Prototheca* species as agents of CNS infections. These infections are considered critical due to their high rates of morbidity and mortality, rapid progression, and potential for severe long-term sequelae, making prompt initiation of appropriate treatment crucial.

Among the 15 reported cases of *Prototheca* spp. infections in the Central Nervous System, only four patients were identified as immunocompromised [26,31,37]. This finding contrasts with the prevailing assertion that invasive protothecosis predominantly affects immunodeficient individuals [13,18,19,36,37,41]. Children with hydrocephalus are at heightened risk, accounting for 20% of the cases. The combination of an immature immune system, the necessity for invasive devices such as ventriculoperitoneal shunts, and complex inflammatory responses to infections renders children with communicating hydrocephalus particularly susceptible to CNS infections [42,43,44].

The prognosis among patients varied significantly; some patients were discharged after two months of treatment (LU et al., 2021), while others required over a year of treatment [33,34,35,22]. Three patients succumbed to the infection [26,31,36], with all fatal cases involving immunocompromised individuals. While immunodeficiency is not a prerequisite for CNS *Prototheca* spp. infections, it significantly predicts an unfavorable prognosis. Only three case reports suggested potential sources of infection: contamination during tattooing [13], contamination from illicit intravenous drug use [26], and contamination via a ventriculoperitoneal shunt [30]. Although Wang et al. [19] indicated that cutaneous infections by *Prototheca* spp. are the primary sites initiating the invasive process leading to systemic infection, only one CNS infection case [13] identified cutaneous protothecosis as the primary infection. Despite cutaneous infections by *Prototheca* spp. being easily misdiagnosed as dermatophytoses due to the non-specific nature of the lesions [2,45,46,47], it is unlikely that clinical histories of cutaneous manifestations would be overlooked in the case reports. The pathogenesis of *Prototheca* spp. CNS infections still requires extensive research to fully understand this severe clinical condition, particularly among immunocompetent patients without underlying conditions or comorbidities.

The specific genes linked to the pathogenicity of algae from the genus *Prototheca* are not well understood due to limited genomic and proteomic data, making it challenging to identify virulence factors from individual variations [48]. Genome

sequence analysis of *Prototheca wickerhamii* has revealed the presence of several genes potentially involved in pathogenicity, including those associated with virulence factors similar to those found in fungi such as *Trichophyton rubrum* [5], *Candida albicans* [5,49], and *Fusarium graminearum* [49]. The capacity of *Prototheca* species to form biofilms, which are associated with immune evasion and drug resistance, suggests that genes involved in biofilm formation may play a role in their pathogenicity [48]. Another mechanism implicated in immune evasion, also observed in fungi such as *Aspergillus* spp., *Candida albicans*, and *Fusarium graminearum* [50,51], is the downregulation of endo-1,4- β -mannosidase during *Prototheca wickerhamii* infections, resulting in a thinner cell wall and the reduction of β -mannanase activity, which can lead to the accumulation of intact mannan, and may impair the immune system's capability to recognize and respond to pathogens [49,50,51]. Haider et al. [52] reveals significant differences in the phagocytosis patterns of different *Prototheca* species and strains, suggesting that some strains of *Prototheca wickerhamii* may have developed other immune evasion mechanisms that are not yet fully understood.

While the pathogenic genetic traits similar to various fungal species pose a problem in terms of the infectious potential of *Prototheca* spp., the homology between the biochemical processes of these algae and various fungal species support the design of treatment strategies based on established protocols for systemic mycoses caused by *Aspergillus* spp., *Trichophyton* spp, *Fusarium* spp, and *Candida* spp, given the absence of specific algicides for human use. These strategies are particularly important in treating systemic infections or infections localized in critical organs and systems such as the Central Nervous System, where the knowledge of the drug's toxicity, antimicrobial perfusion in the infected tissue or biofilms, and efficacy in pathogen elimination are crucial considerations for successful therapy. Nevertheless, the limited repertoire of drugs to which *Prototheca* spp. strains causing CNS infections are susceptible represents a significant therapeutic challenge, expressly in balancing drug toxicity with the need for long-term medication to eradicate the infection.

The analysis of resistance profiles demonstrated sensitivity to amphotericin B in 88.9% of the strains tested for antifungal agents with algicidal activity, and also to two triazole compounds that cross the blood-brain barrier: voriconazole and isavuconazole. Variations in the set of substances tested for resistance profiles in each reported case preclude a meta-analysis of the comparative efficacy of each algicidal antifungal agent beyond amphotericin B.

The probable mechanism of action of amphotericin B on *Prototheca* spp. involves binding to ergosterol, a vital component of the cell membrane, leading to the formation of ion channels or pores, causing membrane permeabilization and leakage of intracellular constituents, resulting in cell death [53]. Additionally, amphotericin B induces ultrastructural changes in *Prototheca* spp., namely mitochondrial swelling, degradation of cellular organelles, accumulation of microbody-like structures, lipid droplets, and starch granules in the cytoplasm, as well as alterations in the inner cell wall layer. This antifungal agent disrupts the normal cellular structure and function of *Prototheca* spp., ultimately affecting their overall physiology [54]. Similar to amphotericin B, azole compounds interfere with physiological processes by targeting cell membrane integrity. These substances disrupt the ergosterol biosynthesis pathway in the cell membrane of *Prototheca* spp., leading to membrane destabilization and eventual cell death [55]. Dependence on drug therapies targeting a single biochemical pathway presents significant risks, primarily due to the potential development of pathogen resistance [56,57]. Since *Prototheca* spp. are the only algae capable of infecting humans on rare occasions, there are no intense efforts to develop algicides capable of halting these microorganism's infection. The development of resistance mechanisms by *Prototheca* spp. during long-term treatment is a possible risk, as presumed in the case related by Cross et al. [22], where the infecting strain ceased responding to isavuconazole after two months of therapy. This finding further suggest that *Prototheca* spp. may exhibit genomic plasticity capable of overcoming drug action. The need to increase the dose of amphotericin B to critical levels in the patient treated by Li et al. [31] may also be a consequence of the development of resistance mechanisms by the infecting strain during treatment with amphotericin B. Proskurnicka et al. [58] tested 23 varieties of *Prototheca* spp. isolated from human infections against amphotericin B and nine azole compounds, revealing that the efficacy of these drugs, particularly resistance to algicidal antifungal agents, varied greatly among different species and even among strains of the same species. Variations in drug efficacy on each strain directly impact the duration of treatment, constrain therapeutic options, and affect the prognosis of patients infected by *Prototheca* spp. in CNS sites [58].

All researches discussing the medication treatment of *Prototheca* spp. CNS infections indicate that antibacterial therapy was based in the use of amphotericin B, predominantly in its liposomal encapsulated form. In spite of its benefits over the traditional formulation, prolonged administration of liposomal amphotericin B should be refrained in the treatment of CNS infections due to notable complications associated with its effectiveness, safety, and potential for severe adverse reactions. Although liposomal amphotericin B is recognized for its decreased nephrotoxicity in comparison to traditional amphotericin B, uncommon instances of neurotoxicity, as reversible encephalopathy, have been reported [59, 60]. The primary issue linked with extended use of amphotericin B is its substantial renal toxicity and the emergence of hematological side effects, which can hinder therapy and result in elevated discontinuation rates [61,62]. The effectiveness of liposomal amphotericin B therapy is also rather reduced in CNS infections, even in the encapsulated form, as its entry into cerebrospinal fluid is restricted, requiring higher doses than those needed to reach other organs in the human body [63]. Among the examined instances of CNS *Prototheca* spp. infections, severe complications from prolonged use of liposomal amphotericin B have

been documented, including hypokalemia [13,35], gastrointestinal responses [13], and hepatic injury [34] and renal failure [13,22,34,31]. Throughout therapy, adjustments in the amphotericin B dosage or its interruption was required in some patients due to renal impairment [13,22,31,34,35]. Li et al. [31] stated that the patient, days before death, was receiving a dosage of 6000 mg per day, and it is believed that physiological harm from 11 months of amphotericin B treatment significantly contributed to the deterioration of health and subsequent decease of this patient. Ahn et al. [33] contend that amphotericin B is frequently the fundamental treatment for protothecosis because *Prototheca* species are generally vulnerable to this antifungal agent, although effectiveness may vary depending on the strain, patient condition, and timely diagnosis alongside aggressive and prolonged therapy, which is crucial for infection control.

Some researchers have observed that the effectiveness of amphotericin B was limited in managing *Prototheca* spp. infections in the CNS [27,30,32]. However, the decision to utilize amphotericin B as the cornerstone of drug therapy seems nearly unescapable, as only one of nine articles investigating antifungal resistance profiles documented a case of resistance to amphotericin B. Currently, several researches are ongoing investigating nanocarrier systems aimed at enhancing the delivery of amphotericin B to infectious sites in the brain and decreasing nephrotoxicity [64,65,66], providing future prospects for prolonging the duration of therapy for CNS protothecosis with this drug while minimizing adverse effects.

An alternative to amphotericin B in the treatment of *Prototheca* spp. CNS infections is voriconazole. In four clinical cases where susceptibility testing of *Prototheca* spp. to this agent was conducted, sensitivity was observed in three strains [13,30,35], with one strain displaying intermediate sensitivity [22]. Voriconazole have broad-spectrum antifungal activity and effective penetration in the Central Nervous System. Clinical investigations demonstrated that voriconazole achieves adequate brain penetration [67,68], although cerebrospinal fluid levels of this substance can be highly variable [69]. This variability requires constant therapeutic monitoring to adjust dosage and minimize toxicity, as voriconazole displays nonlinear pharmacokinetics and may lead to supratherapeutic levels and increased toxicity, particularly within the CNS [67,70]. Like amphotericin B, prolonged use of voriconazole is associated with severe adverse reactions, like hemorrhagic cystitis and bladder rupture (ZENG et al., 2020), periostitis [71,72], and hepatic damage [73,74,75]. Specifically regarding the Central Nervous System, visual disturbances and other neurological disorders occur in approximately 20.6% of patients [70], which can be mistaken for clinical signs resulting from the infection.

Isavuconazole was used in the treatment of a cerebral infection caused by *Prototheca wickerhamii* in a case reported by Cross et al. [22]. The infecting strain of *Prototheca* showed sensitivity to this new triazole agent, which has broad-spectrum antifungal activity and pharmacokinetic properties similar to voriconazole [76]. Although its main therapeutic indications are for invasive aspergillosis and mucormycosis, its broad-spectrum activity against various fungi, including yeasts, filamentous fungi, and dimorphic fungi [77,78,79], makes it a feasible option for CNS infections caused by *Prototheca* spp. Experimental clinical data points that isavuconazole is comparable to other antifungal agents like voriconazole and amphotericin B in terms of efficacy, with a significantly better safety profile, particularly with reduced incidence of adverse events, fewer dosage adjustments, and a lower rate of therapy discontinuations [77,80]. These qualities are crucial for the fine-tuning of Central Nervous System infection treatments, where prolonged therapy, as seen in *Prototheca* spp. infections, is often necessary, and drug tolerability is a constant concern. The permeability of isavuconazole into the Central Nervous System can vary depending on the site and physiological conditions [78], but it can achieve higher concentrations in brain tissue and inflamed areas in patients with Central Nervous System infections, suggesting some potential for Central Nervous System penetration under specific conditions [78,79]. During the treatment course reported by Cross et al.[22], isavuconazole therapy was discontinued due to decreased efficacy in controlling *Prototheca wickerhamii* after two months of treatment, suggesting the potential development of resistance mechanisms by the infecting strain.

Li et al. [31] revealed that the strain isolated from the patient with *Prototheca wickerhamii* meningitis was sensitive to nystatin. Despite its broad-spectrum efficacy against various fungal pathogens, the clinical use of nystatin is limited to topical applications due to its low solubility, pharmacokinetic limitations, and high toxicity when administered systemically [81]. While nystatin is a potential treatment for cutaneous protothecosis [2,23], it is not viable as a therapeutic option for Central Nervous System infections caused by *Prototheca* spp. owing to the drug's ineffectiveness to permeate the blood-brain barrier. [76,82].

Zak et al. [30] used ketoconazole as an initial option in treating cerebrospinal infection by *Prototheca wickerhamii*. Similar to nystatin, ketoconazole does not cross the blood-brain barrier [83], but it has limited action in treating some fungal meningitis because it diffuses into cerebrospinal fluid [30,84] but do not cross the blood-brain barrier. An investigation by Proskurnicka et al. [58] demonstrated that *Prototheca wickerhamii* was sensitive to ketoconazole at low minimum inhibitory concentrations in vitro. Sensitivity to ketoconazole was observed in the *Prototheca zopfii* strain isolated by Joerger et al. [35] in a patient with chronic meningitis, while the *Prototheca wickerhamii* strain isolated by Zak et al. [30] from a patient with cerebrospinal infection was considered resistant after antifungal testing, and the *Prototheca wickerhamii* strain isolated by Zhang et al. [29] from a patient with meningitis had a very high minimum inhibitory concentration. These results indicate

a wide variation in resistance to ketoconazole, which should be considered only as a secondary option in cases of meningitis caused by *Prototheca* spp.

Cross et al. [22] employed a therapeutic strategy combining amphotericin B with doxycycline and tetracycline. The synergy between amphotericin B and tetracycline and its derivatives, such as doxycycline, occurs through various mechanisms that increase antifungal efficacy while potentially reducing toxicity. The combination of amphotericin B with doxycycline showed promising results against multidrug-resistant *Candida auris*, suggesting that this synergistic combination can overcome resistance mechanisms that previously hindered the antifungal's action [85,86]. The combination of amphotericin B and tetracycline antibiotics can increase the uptake of both drugs by fungal cells, leading to higher intracellular concentrations without the need to increase the antifungal dosage [85,87,88]. Additionally, doxycycline may have immunomodulatory and anti-inflammatory effects, which can help reduce the inflammatory response associated with infections and potentially the toxicity of amphotericin B [89]. This therapeutic arrangement was successfully used in cases of systemic protothecosis [90,91], and it was likely crucial in the treatment adopted by Cross et al. [22] for maintaining amphotericin B therapy with reduced adverse effects and increased antifungal efficacy in three distinct periods over an eighteen-month treatment, resulting in a favorable resolution of the cerebral infection in the patient.

The combination of amphotericin B and isavuconazole for treating systemic mycoses shown good results, presenting only known adverse reactions for amphotericin B, without the combination with isavuconazole influencing this toxicity [92,93]. This combination shows therapeutic potential against CNS infections by *Prototheca* spp. and prompts further investigations. During the treatment conducted by Cross et al. [22], the use of isavuconazole combined with doxycycline displayed signs of antagonistic interaction. Therefore, the combinations of amphotericin B and doxycycline, and amphotericin B and isavuconazole, are mutually exclusive options in the search for the best performance of the medicinal protocol.

The combination of voriconazole and amphotericin B can lead to increased side effects, such as kidney damage caused by amphotericin B and liver toxicity from voriconazole, requiring careful monitoring and management of these adverse effects [94]. The simultaneous use of amphotericin B and voriconazole can also complicate the pharmacokinetics and pharmacodynamics of these drugs, making it challenging to determine the appropriate dosage and monitoring needed to achieve optimal therapeutic results without harming the patient [94]. According to Vikelouda et al. [95], the simultaneous use of voriconazole and liposomal amphotericin B has different effects depending on the infecting pathogen. For *Scedosporium apiospermum*, the combination showed a synergistic effect, while for *Fusarium solani* infections, it showed antagonistic interactions. The combination of voriconazole and liposomal amphotericin B was less effective against *Fusarium solani* biofilms compared to the use of each drug alone. Thus, it is not possible to predict whether the combination of voriconazole and liposomal amphotericin B would have a synergistic or antagonistic effect on *Prototheca* spp. infections. The possibility of patient health degradation due to the combined toxicities of both drugs is also a critical factor in choosing this combined therapy and may be the reason why it was not adopted in any cases of CNS infections by *Prototheca* spp., although it could be considered for more aggressive, short-term treatment when other pharmacological protocols prove ineffective.

New treatment options need to be explored for CNS infections caused by *Prototheca* spp. Ravuconazole, a new triazole compound, has shown superior algicidal action in vitro compared to itraconazole, voriconazole, and posaconazole against *Prototheca wickerhamii* and *Prototheca zopfii* [96], and pharmacokinetic studies suggest that this substance can cross the blood-brain barrier [97], making it a potential candidate for the treatment of CNS protothecosis. Invasive protothecosis often presents limited efficacy with azole compounds and amphotericin B, necessitating research into alternative treatments such as antimicrobial herbicides [98].

4. CONCLUSION

Protothecosis is generally considered to be a difficult infection to diagnose due to its rarity and the non-specificity of its clinical symptoms. This statement is even more compelling in relation to *Prototheca* spp. infections in the Central Nervous System, where in addition to the diagnostic pitfalls in histopathology and identification in culture media, there is also the uniqueness of the clinical manifestation of each case and the emulation of fungal infections. For this reason, the determination of *Prototheca* spp. as the etiological agent of CNS infections depends, besides a high degree of clinical suspicion, on confirmation by high accurate diagnostic tests, such as PCR or molecular tests.

At least three species have the ability to infect the Central Nervous System of humans: *Prototheca wickerhamii*, *Prototheca zopfii*, and *Prototheca trispora*, with *Prototheca wickerhamii* being the most prevalent (66.6%). From the 15 documented cases of *Prototheca* spp. infections in the Central Nervous System, only four cases involved individuals with compromised immune systems. This fact suggests that immunocompromise is not a necessary prerequisite for the occurrence of protothecosis in the Central Nervous System, but rather a negative prognostic indicator. Given that cutaneous protothecosis,

as highlighted by various researchers as the initial stage leading to invasive infections, it was recorded on a single case, and further exploration to elucidate the pathogenesis of *Prototheca* spp. CNS infections is imperative. Particularly, children with hydrocephalus are at heightened risk, constituting 20% of reported cases.

Sensitivity to amphotericin B in 88.9% of the strains tested confirms that the algicide therapy based on this drug is practically unavoidable, despite the known adverse effects of long-term drug treatment. Voriconazole and isavuconazole, both triazole compounds, are feasible treatment options for *Prototheca* spp. infections within the Central Nervous System. Combined drug therapies with amphotericin B and tetracyclines and the association of amphotericin B and isavuconazole can be considered even more promising, although the simultaneous implementation of these combinations is not recommended due to the antagonistic interaction between isovuconazole and doxycycline. This antagonistic interaction probably also occurs between isovuconazole and other tetracyclines. The need to adjust dosages due to the inherent toxicity of long-term treatment with algicide-acting antifungals still represents a challenge in drug therapy.

In view of the findings of this study, the formulation of novel guidelines for managing *Prototheca* CNS infections is of utmost significance, as it might result in the creation of more efficient and safer therapies. Subsequent investigations ought to concentrate on comprehending the resistance mechanisms of *Prototheca* species to existing treatments and investigating fresh drug combinations that could present therapeutic synergies. Furthermore, the exploration of adjunctive interventions, which have the potential to alleviate the adverse effects of extended therapies with amphotericin B and triazoles, is imperative for enhancing the quality of life of patients. Stringent clinical trials and in-depth case analyses are indispensable for assessing the effectiveness of new interventions and for adapting therapeutic schedules in accordance with the specific attributes of each patient. Collaboration among research institutions and medical facilities, given the uncommon nature of this infection, has the potential to hasten the dissemination of knowledge and the adoption of evidence-based guidelines, thereby potentially decreasing the mortality and morbidity related to *Prototheca* CNS infections.

DISCLAIMER (ARTIFICIAL INTELLIGENCE)

Authors hereby declare that NO generative AI technologies such as Large Language Models (ChatGPT, COPILOT, etc) and text-to-image generators have been used during writing or editing of manuscripts.

REFERENCES

1. Jagielski T, Bakula Z, Gawor J, Maciszewski K, Kusber WH, Dyla M, et al. The genus *Prototheca* (Trebouxiophyceae, Chlorophyta) revisited: Implications from molecular taxonomic studies. *Algal Research*. 2019 Nov;43:101639.
2. Santos DWDCL, Magalhaes Diniz YC, Silva RRD, Marques SG, Bomfim MRQ, Azevedo CDMPEs. Human protothecosis: A case report in northeastern Brazil. *Medical Mycology Case Reports*. 2023 Jun;40:1–4.
3. Shakoei S, Mohamadi F, Ghiasvand F, Khosravi AR, Kamyab K, Salahshour F. Disseminated protothecosis: Case report and review of the literature. *J Cutan Pathol*. 2024 Jun 11;cup.14668.
4. Bacova R, Kralik P, Kucharovicova I, Seydlova R, Moravkova M. A novel TaqMan qPCR assay for rapid detection and quantification of pro-inflammatory microalgae *Prototheca* spp. in milk samples. *Medical Mycology*. 2021 Jul 14;59(8):784–92.
5. Bakula Z, Siedlecki P, Gromadka R, Gawor J, Gromadka A, Pomorski JJ, et al. A first insight into the genome of *Prototheca wickerhamii*, a major causative agent of human protothecosis. *BMC Genomics*. 2021 Dec;22(1):168.
6. Kano R, Kazuo Satoh, Yaguchi T, Masuda M, Makimura K, De Hoog GS. Phenotypic Characteristics of *Prototheca* Species Occurring in Humans and Animals. *Medical Mycology Journal*. 2022;63(1):17–20.
7. Jinatham V, Cantoni DM, Brown IR, Vichaslip T, Suwannahitatorn P, Popluechai S, et al. *Prototheca bovis*, a unicellular achlorophyllous trebouxiophyte green alga in the healthy human intestine. *Journal of Medical Microbiology* 2021;70(9).
8. Yang H, Genot B, Duhamel S, Kerney R, Burns JA. Organismal and cellular interactions in vertebrate–alga symbioses. *Biochemical Society Transactions*. 2022 Feb 28;50(1):609–20.
9. Libisch B, Picot C, Ceballos-Garzon A, Moravkova M, Klimesová M, Telkes G, et al. *Prototheca* Infections and Ecology from a One Health Perspective. *Microorganisms*. 2022 Apr 29;10(5):938.
10. Lanave G, Pellegrini F, Palermo G, Zini E, Mercuriali E, Zagarella P, et al. Identification of *Prototheca* from the Cerebrospinal Fluid of a Cat with Neurological Signs. *Veterinary Sciences*. 2023 Nov 30;10(12):681.
11. Chen J, Hu X, Li G, Wan P, Shao Z, Jin E, et al. Investigation of *Prototheca bovis* Infection and Its Correlation with Dairy Herd Improvement Data from a Dairy Farm in Central China. *Veterinary Sciences*. 2024 Jan 17;11(1):37.
12. Zea SMR, Itoh M, Toyotome T. Development of Loop-Mediated Isothermal Amplification for the Detection of *Prototheca bovis* Directly from Milk Samples of Dairy Cattle. *Mycopathologia*. 2024 Feb;189(1):1.
13. Lu Y, Zhang X, Ni F, Xia W. Cutaneous Protothecosis with Meningitis Due to *Prototheca wickerhamii* in an Immunocompetent Teenager: Case Report and Literature Review. *IDR*. 2021; 14:2787–94.
14. Yun CH, Jeong JH, Ryu HR, Kim JH, Baek JO, Lee JR, et al. Cutaneous protothecosis responds rapidly to voriconazole. *Int J Dermatology*. 2016 Dec;55(12):1373–7.
15. Woo JY, Suhng EA, Byun JY, Choi HY, Sung SH, Choi YW. A Case of Cutaneous Protothecosis in an Immunocompetent Patient. *Ann Dermatol*. 2016;28(2):273.

16. Tseng H -C., Chen C -B., Ho J -C., Cheng Y -W., Huang H -W., Sun P -L., et al. Clinicopathological features and course of cutaneous protothecosis. *Acad Dermatol Venereol*. 2018 Sep;32(9):1575–83.
17. Belmokhtar Z, Djaroud S, Matmour D, Merad Y. Atypical and Unpredictable Superficial Mycosis Presentations: A Narrative Review. *JoF*. 2024 Apr 18;10(4):295.
18. Cullen GD, Yetmar ZA, Fida M, Abu Saleh OM. *Prototheca* Infection: A Descriptive Study. *Open Forum Infectious Diseases*. 2023 Jun 1;10(6):ofad294.
19. Wang X, Ran Y, Jia S, Ahmed S, Long X, Jiang Y, et al. Human Disseminated Protothecosis: The Skin is the “Window”? *Front Immunol*. 2022 Jun 14;13:880196.
20. Chen Y, Gao A, Ke Y, Zhou X, Lin L, Lu S, et al. Successful Treatment of Cutaneous Protothecosis Due to *Prototheca wickerhamii* with Terbinafine. *CCID*. 2024 Apr;Volume 17:913–9.
21. Xu C, Pan C, Xu C, Zheng W, Yin Q, Pan H, et al. Successful treatment of cutaneous protothecosis with fluconazole: A case report and epidemiology study of *Prototheca* infection in China. *J of Cosmetic Dermatology*. 2024 Jun;23(6):2190–8.
22. Cross P, Ratner JCL, Mahadeva U, McGann H, Igra M, Thomson S, et al. The first case of intracerebral lesions caused by *Prototheca wickerhamii*. *Clinical Infection in Practice*. 2021 Nov;12:100104.
23. Ely VL, Espindola JP, Barasuol BM, Sangioni LA, Pereira DB, Botton SDA. Protothecosis in Veterinary Medicine: a minireview. *Letters in Applied Microbiology*. 2023 Jun 1;76(6):ovad066.
24. Moher D, Liberati A, Tetzlaff J, Altman DG, The PRISMA Group. Preferred Reporting Items for Systematic Reviews and Meta-Analyses: The PRISMA Statement. *PLoS Med*. 2009 Jul 21;6(7):e1000097.
25. Page MJ, McKenzie JE, Bossuyt PM, Boutron I, Hoffmann TC, Mulrow CD, et al. The PRISMA 2020 statement: an updated guideline for reporting systematic reviews. *BMJ*. 2021 Mar 29;n71.
26. Kaminski ZC, Kapiia R, Sharer LR, Kloser P, Kaufman L. Meningitis Due to *Prototheca wickerhamii* in a Patient with AIDS. *Clinical Infectious Diseases*. 1992 Oct 1;15(4):704–6.
27. Takaki K, Okada K, Umeno M, Tanaka M, Takeda T, Ohsaki K, et al. Chronic *Prototheca* Meningitis. *Scandinavian Journal of Infectious Diseases*. 1996 Jan;28(3):321–3.
28. Sinitzkaya AI, Bogomolova TS, Yakovleva OV. Ultrastructure of *Prototheca trispora* (Ashe et al.), isolated from cerebrospinal fluid of a patient with brain infection. *Problems of Medical Mycology*. 2002;4:40–4.
29. Zhang QQ, Zhu LP, Weng XH, Li L, Wang JJ. Meningitis due to *Prototheca wickerhamii*: rare case in China. *Med Mycol*. 2007 Jan;45(1):85–8.
30. Zak I, Jagielski T, Kwiatkowski S, Bielecki J. *Prototheca wickerhamii* as a cause of neuroinfection in a child with congenital hydrocephalus. First case of human protothecosis in Poland. *Diagnostic Microbiology and Infectious Disease*. 2012 Oct;74(2):186–9.
31. Li Y, Zeng Y, Ning G, Gan W, Lin C. A Case Report of *Prototheca* Meningitis in China. *Pharmacoeconomics*. 2016;1(2):e1000108.
32. Hench J, Roschanski N, Hewer E, Rösler U, Lass-Flörl C, Stippich C, et al. Granulomatous encephalitis: protothecosis excluded? *Histopathology*. 2016 Dec;69(6):1082–4.
33. Ahn A, Choe YJ, Chang J, Kim D, Sung H, Kim MN, et al. Chronic Eosinophilic Meningoencephalitis by *Prototheca Wickerhamii* in an Immunocompetent Boy. *Pediatric Infectious Disease Journal*. 2017 Jul;36(7):687–9.
34. Samarasekera J, Mukherjee S, Ismail A, Corns R. Cerebral protothecosis mimicking high-grade glioma. *BMJ Case Rep*. 2021 Jan;14(1):e235362.

35. Joerger T, Sulieman S, Carson VJ, Fox MD. Chronic Meningitis Due to *Prototheca zopfii* in an Adolescent Girl. *Journal of the Pediatric Infectious Diseases Society*. 2021 Apr 3;10(3):370–2.
36. Herold S, Klodt T, Toelle D, Dennebaum M, Lippe E, Walz C, et al. Lethal systemic and brain infection caused by *Prototheca zopfii* algae in a patient with acute myeloid leukemia. *Medical Mycology Case Reports*. 2021;32:17–20.
37. Park S, Jung J, Chong YP, Kim SH, Lee SO, Choi SH, et al. Infectious Causes of Eosinophilic Meningitis in Korean Patients: A Single-Institution Retrospective Chart Review from 2004 to 2018. *Korean J Parasitol*. 2021;59(3):227–33.
38. Dincel GC, El-Ashram S, Tellez-Isaias G, Alali F, Alouf A, Alouffi A, et al. Neuroimmunopathology in Toxoplasmic Encephalitis. In: *Towards New Perspectives on Toxoplasma gondii*. IntechOpen; 2023. Available from: <https://www.intechopen.com/chapters/85605>
39. Kidd S, Halliday C, Ellis D. *Prototheca* Kruger. In: *Descriptions of Medical Fungi*. 4th ed. GB: CABI; 2022; 212–3. Available from: <http://www.cabidigitallibrary.org/doi/10.1079/9781800622340.0079>
40. Rudasill J, Criswell S. A Comparison of Histological Staining Methods for Pathogenic Fungi in Humans. *Int J Infect Dis Ther* 2023; 8(1): 10-22.
41. Rao P, Sethuraman N, Ramanathan Y, Gopalakrishnan R. Disseminated protothecosis caused by *Prototheca zopfii* in a liver transplant recipient. *J Global Infect Dis*. 2018;10(4):228.
42. Isaacs AM, Morton SU, Movassagh M, Zhang Q, Hehny C, Zhang L, et al. Central nervous system immune response in postinfectious hydrocephalus. 2020. Available from: <http://medrxiv.org/lookup/doi/10.1101/2020.07.30.20165332>
43. Konrad E, Robinson JL, Hawkes MT. Cerebrospinal fluid shunt infections in children. *Arch Dis Child*. 2023 Sep;108(9):693–7.
44. Pana ZD, Groll AH, Lehrnbecher T. An Update on the Diagnosis and Treatment of Invasive Mold Disease of the Central Nervous System in Children. *Pediatric Infectious Disease Journal*. 2023 Apr;42(4):e119–21.
45. Azevedo CDM, Santos DW, Diniz YCMYCM, Simões-Neto EASN, Mendes RBRB, Diniz FDMF, et al. Human protothecosis: A case report in Northeastern Brazil. *Medical Mycology*. 2022;60(s1):myac072P098.
46. Zhao F, Chen M, Fu Y. Multiple cutaneous infections caused by *Prototheca wickerhamii*. *Clinical Laboratory Analysis*. 2020 Nov;34(11):e23492.
47. Rajan A, Pai V, Shukla P. Cutaneous protothecosis in an immunocompetent host. *Indian J Dermatol Venereol Leprol*. 2020;86(4):414.
48. Shave CD, Millyard L, May RC. Now for something completely different: *Prototheca*, pathogenic algae. Sheppard DC, editor. *PLoS Pathog*. 2021 Apr 1;17(4):e1009362.
49. Guo J, Chen J, Li T, Gao L, Jiang C, Wu W. Integration of transcriptomics, proteomics, and metabolomics data for the detection of the human pathogenic *Prototheca wickerhamii* from a One Health perspective. *Front Cell Infect Microbiol*. 2023 May 5;13:1152198.
50. Lambré C, Barat Baviera JM, Bolognesi C, Cocconcelli PS, Crebelli R, Gott DM, et al. Safety evaluation of the food enzyme mannan endo-1,4- β -mannosidase from the genetically modified *Aspergillus niger* strain NZYM-NM. *EFA* 2022;20(4).
51. Zhang SB, Zhang WJ, Li N, Zhai HC, Lv YY, Hu YS, et al. Functional expression and characterization of an endo-1,4- β -mannosidase from *Triticum aestivum* in *Pichia pastoris*. *Biologia*. 2020;75(11):2073–81.
52. Haider MJA, Shave CD, Onyishi CU, Jagielski T, Lara-Reyna S, Frickel EM, et al. Species- and strain-specific differences in the phagocytosis of *Prototheca*: insights from live-cell imaging. Roy CR, editor. *Infect Immun*. 2023;91(9):e00066-23.

53. Watanabe T, Ishikawa T, Sato H, Hirose N, Nonaka L, Matsumura K, et al. Characterization of *Prototheca* CYP51/ERG11 as a possible target for therapeutic drugs. *Medical Mycology*. 2021;59(9):855–63.
54. Segal E, Socher R. The effect of amphotericin B on the ultrastructure of *Prototheca* species. *Mycopathologia* 1981;76(2):73–7.
55. Abad JMM, Kozikova V, Toral JCU. Protothecosis: case report with emphasis on microbiological diagnostic. *Rev Ecuat Cienc Tec Innov Salud Pub* 2023;7(22):95-100.
56. Silver LL. Appropriate Targets for Antibacterial Drugs. *Cold Spring Harb Perspect Med*. 2016 Dec;6(12):a030239.
57. Manshadi MD, Setoodeh P, Zare H. Systematic analysis of microorganisms' metabolism for selective targeting. *Biorxiv* 2023. Available from: <http://biorxiv.org/lookup/doi/10.1101/2023.07.14.549016>
58. Proskurnicka A, Żupnik K, Bakula Z, Iskra M, Rösler U, Jagielski T. Drug Susceptibility Profiling of *Prototheca* Species Isolated from Cases of Human Protothecosis. *Antimicrob Agents Chemother*. 2023;67(4):e01627-22.
59. Luo S, Wen H, Zhou M, Wu C, Hong D. Case report: Reversible encephalopathy associated with liposomal amphotericin B in a patient with cryptococcal meningitis. *Front Neurol*. 2022;13:1019137.
60. Nailor MD, Goodlet KJ, Gonzalez O, Haller JT. Early Experiences with Intrathecal Administration of Amphotericin B Liposomal Formulation at a Neurosurgical Center. *Cent Nerv Sys Drug*. 2024;38(3):225–9.
61. Cavassin FB, Baú-Carneiro JL, Vilas-Boas RR, Queiroz-Telles F. Sixty years of Amphotericin B: An Overview of the Main Antifungal Agent Used to Treat Invasive Fungal Infections. *Infect Dis Ther*. 2021;10(1):115–47.
62. Yan C, Lin Q, Su B, Su X, Su H, Mo L. Analysis and Management of Adverse Drug Reactions after Injection of Amphotericin B in AIDS Patients with Fungal Infection. *Nat Sci* 2022;14(02):62–70.
63. Petraitis V, Petraitiene R, Valdez JM, Pyrgos V, Lizak MJ, Klaunberg BA, et al. Amphotericin B Penetrates into the Central Nervous System through Focal Disruption of the Blood-Brain Barrier in Experimental Hematogenous *Candida* Meningoencephalitis. *Antimicrob Agents Chemother*. 2019;63(12):e01626-19.
64. Wang X, Mohammad IS, Fan L, Zhao Z, Nurunnabi M, Sallam MA, et al. Delivery strategies of amphotericin B for invasive fungal infections. *Acta Pharmaceutica Sinica B*. 2021;11(8):2585–604.
65. Sharifi N, Alitaneh Z, Asadi S, Vahidinia Z, Aghaei Zarch SM, Esmaeili A, et al. Developing nanosize carrier systems for Amphotericin-B: A review on the biomedical application of nanoparticles for the treatment of leishmaniasis and fungal infections. *Biotechnology Journal*. 2024;19(1):2300462.
66. Mehrizi TZ, Mosaffa N, Vodjgani M, Shahmabadi HE. Advances in nanotechnology for improving the targeted delivery and activity of amphotericin B (2011–2023): a systematic review. *Nanotoxicology* 2024;1–28.
67. Campos LDA, Fin MT, Santos KS, Gualque MWDL, Cabral AKLF, Khalil NM, et al. Nanotechnology-Based Approaches for Voriconazole Delivery Applied to Invasive Fungal Infections. *Pharmaceutics*. 2023;15(1):266.
68. Aboabdo M, Mishkin A. Antifungal therapy for the treatment of Central Nervous System infections. *Curr Fungal Infect Rep*. 2024;18(2):146–53.
69. Staudt KJ, Dias BB, Alves IA, Lelièvre B, Bouchara JP, De Araújo BV. Modeling and Simulation as a Tool to Assess Voriconazole Exposure in the Central Nervous System. *Pharmaceutics*. 2023;15(7):1781.
70. Yang L, Wang C, Zhang Y, Wang Q, Qiu Y, Li S, et al. Central Nervous System Toxicity of Voriconazole: Risk Factors and Threshold – A Retrospective Cohort Study. *IDR*. 2022; 15:7475–84.
71. Ávila DCF, Diehl M, Degrave AM, Buttazzoni M, Pereira T, Aguirre MA, et al. Voriconazole-induced periostitis. *Reumatismo* 2021;73(1):44–7.

72. Masnammany AM, Lau W, Wong PKK, Manolios N. Voriconazole-induced arthritis, enthesitis and periostitis. *Proceedings of Singapore Healthcare*. 2023;32:e201010582211495.
73. Bonastre PT, Aragones Eroles A, Martinez Sogues M, Martinez Castro B, Cano Marrón S, Rivero Arango E, et al. Voriconazole therapeutic drug monitoring: relationship with liver toxicity. In: *Section 4: Clinical pharmacy services*. *Eur J Hosp Pharm* 2022;29(s1):A66-A67.
74. Xiao G, Liu Y, Chen Y, He Z, Wen Y, Hu M. The Development and Validation of a Predictive Model for Voriconazole-Related Liver Injury in Hospitalized Patients in China. *JCM*. 2023;12(13):4254.
75. Yun J, Fan L, Chai J, Liu X, Liu W. Hepatic dysfunction events associated with voriconazole: a real-world study from FDA adverse event reporting system (FAERS) database. *Authorea* 2023. Available from: <https://www.authorea.com/users/591807/articles/627633-hepatic-dysfunction-events-associated-with->

UNDER PEER REVIEW

76. Schwartz S, Kontoyiannis DP, Harrison T, Ruhnke M. Advances in the diagnosis and treatment of fungal infections of the Central Nervous System. *The Lancet Neurology*. 2018;17(4):362–72.
77. Batista MV, Ussetti MP, Jiang Y, Neofytos D, Cortez AC, Feriani D, et al. Comparing the Real-World Use of Isavuconazole to Other Anti-Fungal Therapy for Invasive Fungal Infections in Patients with and without Underlying Disparities: A Multi-Center Retrospective Study. *JoF* 2023;9(2):166.
78. Lewis JS, Wiederhold NP, Hakki M, Thompson GR. New Perspectives on Antimicrobial Agents: Isavuconazole. *Antimicrob Agents Chemother*. 2022;66(9):e00177-22.
79. Bergmann F, Wölfel-Duchek M, Jorda A, Al Jalali V, Leutzendorff A, Sanz-Codina M, et al. Pharmacokinetics of isavuconazole at different target sites in healthy volunteers after single and multiple intravenous infusions. *Journal of Antimicrobial Chemotherapy*. 2024;79(5):1169–75.
80. Kato H, Hagihara M, Asai N, Umemura T, Hirai J, Mori N, et al. A systematic review and meta-analysis of efficacy and safety of isavuconazole for the treatment and prophylaxis of invasive fungal infections. *Mycoses* 2023;66(9):815–24.
81. Saadat E, Dinarvand R, Ebrahimnejad P. Encapsulation of nystatin in nanoliposomal formulation: characterization, stability study and antifungal activity against *Candida albicans*. *Pharm Biomed Res* 2016;2(1):44–54.
82. Black KE, Baden LR. Fungal Infections of the Central Nervous System: Treatment Strategies for the Immunocompromised Patient. *Cent Nerv Sys Drug* 2007;21(4):293–318.
83. Daneshmend TK, Warnock DW. Clinical pharmacokinetics of ketoconazole. *Clin Pharmacokinet*. 1988 Jan;14(1):13-34.
84. Jodh R, Tawar M, Mude G, Khodaskar H, Kinekar K. Ketoconazole: A Promising Drug for Fungal Infections. *AJPS*. 2023;101–5.
85. Brennan-Krohn T, Friar L, Ditelberg S, Kirby JE. Synergistic Activity of Minocycline and Rifampin in Combination with Antifungal Drugs against *Candida auris*. *Biorxiv* 2021. Available from: <http://biorxiv.org/lookup/doi/10.1101/2021.02.23.432620>
86. Simon SP, Li R, Silver M, Andrade J, Tharian B, Fu L, et al. Comparative Outcomes of *Candida auris* Bloodstream Infections: A Multicenter Retrospective Case-Control Study. *Clinical Infectious Diseases*. 2023;76(3):e1436–43.
87. Gao L, Sun Y, Yuan M, Li M, Zeng T. In Vitro and In Vivo Study on the Synergistic Effect of Minocycline and Azoles against Pathogenic Fungi. *Antimicrob Agents Chemother*. 2020;64(6):e00290-20.
88. Tan L, Shi H, Chen M, Wang Z, Yao Z, Sun Y. In vitro synergistic effect of minocycline combined with antifungals against *Cryptococcus neoformans*. *Journal of Medical Mycology*. 2022;32(1):101227.
89. Falci DR, Pasqualotto AC. Amphotericin B: a review about different formulations adverse effects and toxicity. *Clin Biomed Res* 2015;35(2):65–82.
90. Todd JR, King JW, Oberle A, Matsumoto T, Odaka Y, Fowler M, et al. Protothecosis: report of a case with 20-year follow-up, and review of previously published cases. *Med Mycol*. 2012;50(7):673–89.
91. Yagnik K, Bossé R, Reppucci J, Butts R, Islam S, Cannella AP. Case Report: Olecranon Bursitis due to *Prototheca wickerhamii* in an Immunocompromised Patient. *Am J Trpo Med Hyg* 2019;100(3):703–5.
92. Feys S, Dedeurwaerdere F, Lagrou K, Van Lerbeirghe J, Deeren D. Successful Multimodal Therapy with Intracerebral Liposomal Amphotericin B and Systemic High-Dose Isavuconazole in Proven Disseminated Aspergillosis. *JoF*. 2023;9(3):327.

93. Teng Q, Ye X, Wang B, Zhang X, Tao Z, Yin X, et al. Case report: Successful combination therapy with isavuconazole and amphotericin B in treatment of disseminated *Candida tropicalis* infection. *Front Med*. 2024;11:1397539.
94. Al Jalali V, Sauermann R, Eberl S, Zeitlinger M. In vitro activity of voriconazole and amphotericin B against *Candida albicans*, *Candida krusei*, and *Cryptococcus neoformans* in human cerebrospinal fluid. *Infection*. 2019;47(4):565–70.
95. Vikelouda K, Simitsopoulou M, Skoura L, Antachopoulos C, Rolidis E. Activity of Amphotericin B Formulations and Voriconazole, Alone or in Combination, against Biofilms of *Scedosporium* and *Fusarium* spp. *Antimicrob Agents Chemother*. 2021;65(11):e00638-21.
96. Miura A, Kano R, Ito T, Suzuki K, Kamata H. In vitro algacidal effect of itraconazole and ravuconazole on *Prototheca* species. *Medical Mycology*. 2020 Aug 1;58(6):845–7.
97. Groll AH, Mickiene D, Petraitis V, Petraitiene R, Kelaher A, Sarafandi A, et al. Compartmental pharmacokinetics and tissue distribution of the antifungal triazole ravuconazole following intravenous administration of its di-lysine phosphoester prodrug (BMS-379224) in rabbits. *J Antimicrob Chem* 2005;56(5):899–907.
98. Morello L, Tiroli T, Aretino F, Morandi S, Breviaro D. Preliminary Results, Perspectives, and Proposal for a Screening Method of In Vitro Susceptibility of *Prototheca* Species to Antimicrotubular Agents. *Antimicrob Agents Chemother*. 2020;64(3):e01392-19.
99. Cunha, B. A. (2001). Central nervous system infections in the compromised host: a diagnostic approach. *Infectious disease clinics of North America*, 15(2), 567-590.
100. Erdem, H., Inan, A., Guven, E., Hargreaves, S., Larsen, L., Shehata, G., ... & Nassar, M. (2017). The burden and epidemiology of community-acquired central nervous system infections: a multinational study. *European journal of clinical microbiology & infectious diseases*, 36, 1595-1611.