

Revitalizing Ovarian Function: Autologous Stem Cell Therapy in Poor Ovarian Reserve

ABSTRACT

Ovarian reserve indicates the quantity and quality of Ovarian primordial follicles. Poor ovarian reserve (POR) indicates the reduction in the quantity of ovarian follicular pool in women of reproductive age group. In recent years, autologous stem cell therapy has emerged as a promising avenue in the realm of reproductive medicine, offering new hope to patients with POR

Aims: To evaluate the ovarian response (FSH, LH, AMH and Antral follicular Count) after autologous stem cell therapy

To assess the pregnancy rate after autologous stem cell therapy

Study design: Prospective Observational study

Place and Duration of Study: The study was conducted in a fertility clinic from June 2022 to June 2023.

Methodology: This prospective observational study was conducted in a Fertility clinic (Srikari Hospital, Hospet, Karnataka) for one year, from June 2022 to June 2023. The study was done among women diagnosed with poor ovarian reserve with infertility. Autologous bone marrow-derived stem cell therapy was given as a part of fertility treatment. Hormonal assays and Antral Follicular Counts were measured before and after the stem cell therapy. The improvement in ovarian function was assessed. Pregnancy rates were also assessed.

RESULTS:

The present study was conducted among 8 women, The mean age of the study participants was 32.1 ± 6.33 years (minimum age 20 years and max age 39 years). The serum Anti Mullerian Hormone levels and Antral follicular counts showed a significant change after the stem cell therapy. The mean baseline AMH was 0.371 ± 0.198 ng/l, and at the end of 3rd month, AMH was 0.786 ± 0.353 ng/l. Pregnancy rates after the procedure were about 71%

Conclusion: Autologous bone marrow-derived stem cell therapy has emerged as a new hope for ovarian rejuvenation for women with poor ovarian reserve. Clinical application of this in the reproductive medicine practice helps to solve the challenge of infertility associated with poor ovarian reserve

Keywords: Poor ovarian reserve, infertility, Stem cell therapy, Pregnancy

1. INTRODUCTION

Reproductive aging is a continuous process from before birth till menopause where the irreversible attrition of germ cells progressively diminishes the follicular pool of the women. Fertility peaks before

the age of thirty and later on it declines gradually due to a reduction in follicular pool as a result of ovulation and follicular atresia.¹

Ovarian reserve indicates the quantity and quality of Ovarian primordial follicles. Poor ovarian reserve (POR) indicates the reduction in the quantity of ovarian follicular pool in women of reproductive age group.^{1,2}

POR is associated with low pregnancy rates and high pregnancy loss irrespective of age. Poor ovarian reserve (POR) poses a significant challenge to women seeking to conceive, impacting their fertility potential and often leading to emotional distress and frustration[18-20].

Reproductive medicine has many advancements in assisted reproduction technology since the first baby from invitro fertilization which was born 40 years ago. There are many advancements such as intracytoplasmic sperm injection, peri-implantation genetic counselling, and many others. Despite many advancements, poor ovarian reserve is still a major challenge in reproductive medicine.

Oocyte donation seemed to be the only therapeutic option for women with poor ovarian reserve who desire to have a pregnancy. This has many significant psychological and other issues related to it in terms of not being able to have their own biological child.^{1,4}

Ovarian rejuvenation^{5,6}, a new concept has emerged recently, it is the procedure for restoring Ovarian function and it has been used to enhance fertility in women with poor ovarian reserve. Many methods have been tried-

Intraovarian Platelet-Rich Plasma Injections, Autologous stem cell therapy, Mesenchymal stem cell mobilization from peripheral blood.

In recent years, autologous stem cell therapy has emerged as a promising avenue in the realm of reproductive medicine, offering new hope to patients with POR.⁶ This innovative approach harnesses the regenerative potential of a patient's own stem cells to rejuvenate ovarian function, potentially enhancing ovarian reserve and improving reproductive outcomes. As research in this field continues to advance, understanding the mechanisms and efficacy of autologous stem cell therapy among POR patients is crucial for optimizing fertility treatments and offering renewed possibilities for those facing fertility challenges. This introduction sets the stage for exploring the rationale, methodologies, and outcomes associated with autologous stem cell therapy in the context of poor ovarian reserve, shedding light on its potential as a transformative strategy in reproductive medicine.^{7,8}

In 2013, Abd-Allah and co-workers reported the therapeutic application of BMSCs for cyclophosphamide-mediated ovarian dysfunction in a rabbit model and explored the underlying mechanism. They reported that intravenous injection of BMSCs could restore the structure and function of ovarian follicles through down-regulation of FSH and upregulation of estrogen and VEGF levels.⁹

In 2017, Badawy conducted a similar experiment on mice and documented that there was a revival of hormonal levels and pregnancy in infertile mice after administration of bone marrow stem cells after 21 days⁶

Sonia Herraiz conducted an experimental study on mice on bone marrow-derived stem cell therapy for restoring ovarian function. The study showed the fertility rescue and observed spontaneous pregnancies.¹⁰

Lee et al, reported that bone marrow transplantation restored ovarian function which has been regarded as a promising treatment for patients with ovarian insufficiency. To date, many studies on bone marrow-derived stem cells have reported good results

Including improved Ovarian volume, restoration of the menstrual cycle, improved menopausal symptoms, increased anti-Mullerian hormone (AMH) levels increased number of antral follicles, and higher pregnancy rates.^{11,12}

The present study was conducted to explore the phenomenon of ovarian rejuvenation and its outcomes on the fertility of women with poor ovarian reserve. The present study was conducted with the following objectives

- To evaluate the ovarian response (FSH, LH, AMH and Antral follicular Count) after autologous stem cell therapy
- To assess the pregnancy rate after autologous stem cell therapy

2. MATERIALS AND METHODS

This was a prospective observational study conducted in the fertility clinic for 1 year from June 2022 to June 2023 at Srikari Hospital, Hospet among the women diagnosed with Poor Ovarian reserve with Infertility. The Bologna Criteria was used for diagnosing the cases of Poor ovarian reserve. Women with Anomalies of the uterus, endometriosis, prior ovarian surgeries, male factor infertility, and Infertility due to genetic or chromosomal disorders were excluded from the study. The Participants were included using purposive sampling.

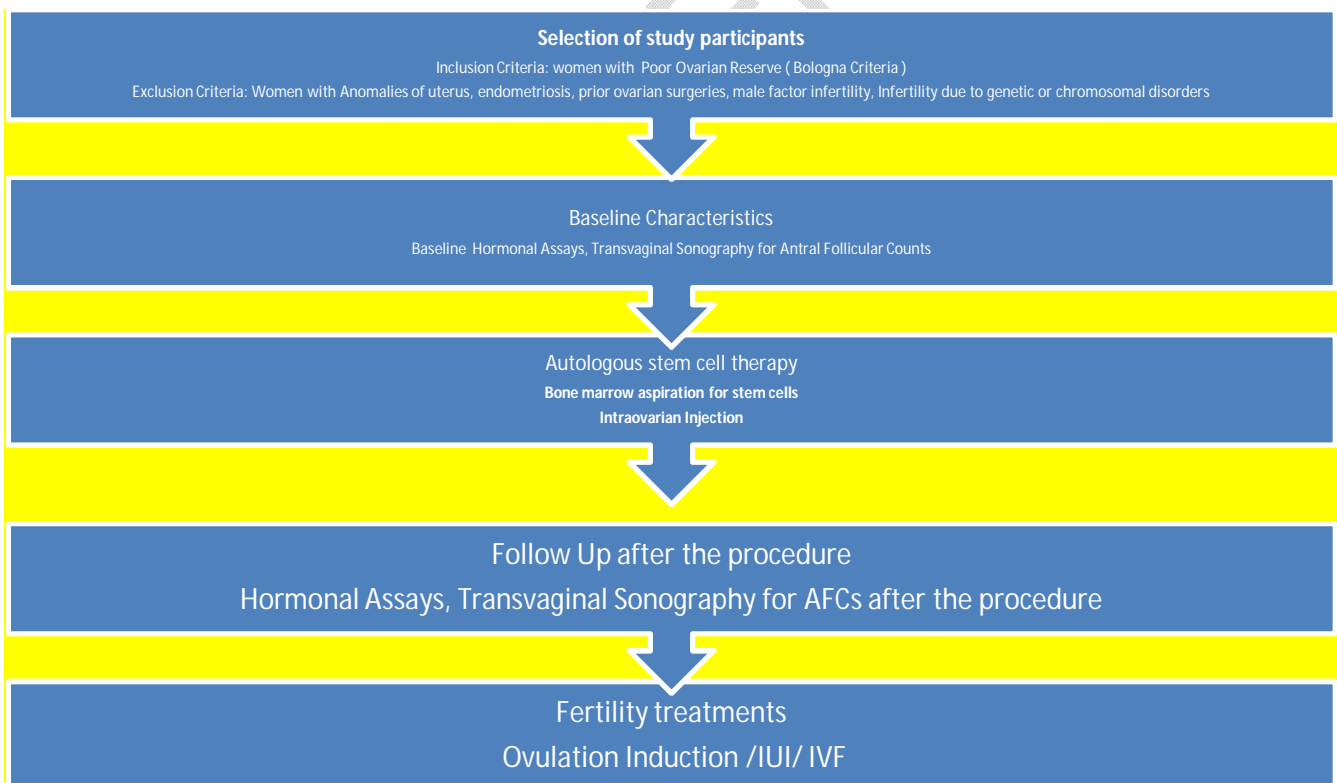

Figure 1: Methodology

Baseline characteristics: The following details were collected on day 2 of the menstrual cycle

Basic Sociodemographic details

- Hormonal assays- Follicular Stimulating Hormone (FSH), Luteinizing hormone(LH), Anti Mullerian Hormone(AMH) were measured in a certified laboratory using standard hormonal assay methods,
- Antral follicular count(AFC) by assessed Transvaginal sonography

Autologous bone marrow-derived Stem cell therapy

Bone marrow aspiration for stem cells:the procedure was conducted on the 7th day of the menstrual cycle.

Bone marrow extraction was done from the iliac crest using 13G or 11G using a Jamshedi needle. Using 20ml syringe, 10ml of Bone marrow was aspirated under aseptic precautions. The aspirated bone marrow was subjected to centrifugation at 1800rpm for 12min at 20 degrees(with heparin). Buffy coat and protein-rich plasma extracted from initial centrifugation were again subjected to centrifugation at 3400 rpm for 6min. Suitable aseptic measures were taken during the procedure. Adverse events or any untoward events during the procedures were taken care of throughout the procedure.

Intraovarian Injection: After the bone marrow aspiration and centrifugation, the stem cells are instilled in both ovaries, and 0.8-1ml of Platelet-rich plasma/ovary was instilled into both ovaries by laparoscopically under all aseptic precautions.

The whole procedure was done under spinal anesthesia.

Follow-up Schedule: The participants were followed up for 1 year, The hormonal assays and AFCs were assessed at the end of 3 months after the procedure on day 2 of the menstrual cycle. The fertility treatment was started after 3 months of the procedure. The participants were followed up for one year. Pregnancy rates were assessed.

Diagnosis of POR was done using this criteria: Bologna criteria¹³ recommend the presence of at least two of the following three features for diagnosis of POR

- I. Advanced maternal age (≥ 40 years) or any other risk factor for POR
- II. A previous POR (\leq three oocytes with a conventional stimulation protocol)
- III. An abnormal Ovarian Reserve Tests (i.e. AFC, 5–7 follicles or AMH, 0.5–1.1 ng/ml)

3. RESULTS AND DISCUSSION

The present study was conducted among 8 women, The mean age of the study participants was 32.1 ± 6.33 years (minimum age 20 years and max age 39 years)

Out of 8 patients about 75% were diagnosed with Poor Ovarian Reserve (N=6) and about 25% of patients had early menopause (n=2)

Bone marrow aspiration was done among 8 women, but the intra-ovarian injection was done among 7 women as 1 aspiration was a dry tap.

Table 1: Baseline levels of FSH, LH and AMH and AFC

	Mean± Standard Deviation(n-8)
AMH (ng/l)	0.362±0.185
FSH (IU/l)	18.3±20.5
LH (IU/l)	13.7±18.1
AFC	1.14±1.21

Evaluation of Ovarian function after autologous stem cell therapy: This was assessed by comparing the baseline hormonal levels of the study participants with hormonal levels at 3rd month after autologous stem cell therapy. The results showed the change in the hormonal levels, serum AMH levels were raised at the end of 3rd month (0.786±0.353) when compared to the mean baseline AMH Levels (0.371±0.198 ng/l) which was statistically significant (P value obtained using Paired t-test), Serum FSH levels were decreased, Serum LH levels were also decreased after autologous stem cell therapy (Table 2).

Changes in AFCs: The study also showed an increase in the Antral follicular count after the procedure. The rise in AFC showed statistical significance.

Table 2: Changes in FSH, LH, AMH and AFC after autologous stem cell therapy

	Mean±SD	Mean difference	P
Baseline AMH(ng/l)	0.371±0.198	-0.414(-0.569±-0.259)	< .001*
AMH after Intraovarian injection of Stemcells(ng/l)	0.786±0.353		
Baseline FSH(IU/l)	19.571±21.801	9.829(-5.64±25.297)	0.171
FSH after Intraovarian injection of Stemcells(IU/l)	9.743±11.323		
Baseline LH(IU/l)	15.257±19.008	8.4(-4.836±21.636)	0.171
LH after Intraovarian injection of Stemcells(IU/l)	6.857±7.264		
Baseline AFCs	1.143±1.215	-2.429(-4.018±-0.839)	0.01*
AFCs after Intraovarian injection of Stemcells	3.571±2.299		

*significant

Pregnancy after Stem cell therapy: Out of 7 patients who underwent Ovarian injection of Stem cells, 5 members conceived. Among them 2 women conceived with IVF, 2 women conceived with Ovulation Induction and 1 woman conceived naturally (Figure 1).

PREGNANCY AFTER STEM CELL THERAPY

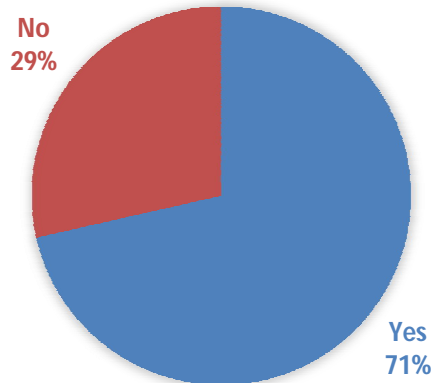


Figure 2: Pregnancy rate after intraovarian injection of autologous stem cells.

Adverse events during the study period: Out of 8 women who underwent Bone marrow aspiration, none of them reported any adverse event during the procedure. Out of 7 women with intra-ovarian injection of stem cells, none of the women reported any side effects or adverse events throughout the follow-up period.

Discussion

Certain Ethnicities have also shown Poor Ovarian reserve, they exhibit the signs of poor ovarian response while undergoing IVF. In a study by Carlos Iglesias M.D. among Indian and Spanish women, Ovarian age (AFC, AMH) showed that Indian women were found to be approximately 6.3 years older compared to Spanish women.¹⁴

In a study conducted by Jesmine Banu in Dhaka, after autologous stem cell mobilization in cases of poor ovarian reserve, baseline AMH levels were $0.39 \pm 0.63 \text{ ng/l}$, and at the end of 3rd month AMH was $1.21 \pm 0.27 \text{ ng/l}$, AMH levels were increased by $0.820 \pm 0.44 \text{ ng/l}$, AFC counts were also increased, and the increase was statistically significant. Pregnancy was achieved in 4% of the cases⁷. In the present study, Serum AMH and AFC count were statistically significant and were improved when compared to baseline values with follow-up values at 3rd month. A similar study by the same author, Jesmin Banu in Dhaka, Bangladesh on the efficacy of platelet-rich plasma among infertile women having poor ovarian reserve, similar findings were obtained to the present study. There was an improvement in the AMH and AFCs count post-PRP Ovarian Infusion. They reported a pregnancy rate of 20%¹⁷

The present study showed higher levels of pregnancy compared to the other studies. 71% of the participants became pregnant after the procedure. This sets a new hope for the women with poor ovarian reserve and also for the treating obstetrician.

In a study conducted by N Singh¹⁵ among women with diminished ovarian reserve, there was a significant increase in AMH and AFC Values after autologous stem cell ovarian transplantation (ASCOT) which was similar to the results obtained from the present study.

In a case report by Shreya Gupta⁸ A 45-year-old perimenopausal female, with AFC of 1, Autologous Bone Marrow-Derived Stem Cell Therapy was performed, after 8 weeks of the procedure, her TVS

showed 2 follicles in each ovary, the pregnancy was successful with IVF. This was India's first baby with Autologous Bone Marrow-Derived Stem Cell Therapy.

Despite the promising results in animal and human studies on autologous stem cell therapy for ovarian rejuvenation, the mechanism by which it enhances ovarian function and fertility is yet to be understood.

Further studies are needed to evaluate the efficacy of stem cell therapy and other benefits of stem cell therapy.

Limitations of the study: Small sample size

4. CONCLUSION

The present study showed that ovarian injection of autologous stem cells has a significant impact on the fertility status of women by improving the levels of Anti-Mullerian Hormone and also by Antral Follicular count. The Pregnancy rates were also increased. Autologous stem cell therapy can be considered in patients with poor ovarian reserve. Clinical application of this autologous bone marrow-derived stem cell therapy in the reproductive medicine practice helps to solve the challenge of infertility associated with poor ovarian reserve

CONSENT:

The procedure, risks and benefits of the procedure were explained to the patients in their own understandable language and voluntary written consent was taken from the patient before the procedure. Confidentiality, anonymity and privacy of the patients were maintained during the procedure, follow up and further management.

ETHICAL APPROVAL

The study was approved by the local ethics committee.

DISCLAIMER (ARTIFICIAL INTELLIGENCE)

Option 1:

Author(s) hereby declare that no generative ai technologies such as large language models (chatgpt, copilot, etc) and text-to-image generators have been used during writing or editing of manuscripts.

Option 2:

Author(s) hereby declare that generative ai technologies such as large language models, etc have been used during writing or editing of manuscripts. This explanation will include list the name, version, model, and source of the generative ai technology and as well as the all input prompts provided to a generative ai technology

Details of the ai usage are given below:

- 1.
- 2.
- 3.

REFERENCES

1. Jirge PR. Poor ovarian reserve. J Hum Reprod Sci. 2016 Apr-Jun;9(2):63-9. doi: 10.4103/0974-1208.183514. PMID: 27382229; PMCID: PMC4915288.

2. Hansen KR, Knowlton NS, Thyer AC, Charleston JS, Soules MR, Klein NA. A new model of reproductive aging: The decline in ovarian non-growing follicle number from birth to menopause. *Hum Reprod.* 2008; 23:699–708.
3. Peters H. Intrauterine gonadal development. *FertilSteril.* 1976;27:493–500.
4. *Oocyte or embryo donation to women of Advanced Reproductive Age: An ethics committee opinion* (no date) *Fertility and sterility*. Available at: <https://pubmed.ncbi.nlm.nih.gov/27450186/> (Accessed: 30 April 2024).
5. Fraidakis M, Giannakakis G, Anifantaki A, Skouradaki M, Tsakoumi P, Bitzopoulou P, Kourpa S, Zervakis A, Kakouri P. Intraovarian Platelet-Rich Plasma Injections: Safety and Thoughts on Efficacy Based on a Single Centre Experience With 469 Women. *Cureus.* 2023 May 7;15(5):e38674. doi: 10.7759/cureus.38674. PMID: 37288228; PMCID: PMC10243509.
6. Saha, S.; Roy, P.; Corbitt, C.; Kakar, S.S. Application of Stem Cell Therapy for Infertility. *Cells* **2021**, *10*, 1613. <https://doi.org/10.3390/cells10071613>
7. Banu J, Jahan N, Anwary SA, Tarique M, Aziz I, Laskar N, et al. Effects of autologous stem cell therapy for fertility enhancement among women with premature ovarian insufficiency. *Int J Reprod Contracept ObstetGynecol*2023;12:310-6
8. Gupta S, Lodha P, Karthick MS, Tandulwadkar SR. Role of Autologous Bone Marrow-Derived Stem Cell Therapy for Follicular Recruitment in Premature Ovarian Insufficiency: Review of Literature and a Case Report of World's First Baby with Ovarian Autologous Stem Cell Therapy in a Perimenopausal Woman of Age 45 Year. *J Hum Reprod Sci.* 2018 Apr-Jun;11(2):125-130. doi: 10.4103/jhrs.JHRS_57_18. PMID: 30158807; PMCID: PMC6094531.
9. Abd-Allah SH, Shalaby SM, Pasha HF, El-Shal AS, Raafat N, Shabrawy SM, Awad HA, Amer MG, Gharib MA, El Gendy EA, Raslan AA, El-Kelawy HM. Mechanistic action of mesenchymal stem cell injection in the treatment of chemically induced ovarian failure in rabbits. *Cytotherapy.* 2013 Jan;15(1):64-75. doi: 10.1016/j.jcyt.2012.08.001. PMID: 23260087.
10. Herraiz S, Buigues A, Díaz-García C, Romeu M, Martínez S, Gómez-Seguí I, Simón C, Hsueh AJ, Pellicer A. Fertility rescue and ovarian follicle growth promotion by bone marrow stem cell infusion. *FertilSteril.* 2018 May;109(5):908-918.e2. doi: 10.1016/j.fertnstert.2018.01.004. Epub 2018 Mar 22. PMID: 29576341.
11. Lee, H.J.; Selesniemi, K.; Niikura, Y.; Niikura, T.; Klein, R.; Dombkowski, D.M.; Tilly, J.L. Bone marrow transplantation generates immature oocytes and rescues long-term fertility in a preclinical mouse model of chemotherapy-induced premature ovarian failure. *J. Clin. Oncol.* **2007**, *25*, 3198–3204.

12. Mohamed, S.A.; Shalaby, S.M.; Abdelaziz, M.; Brakta, S.; Hill, W.D.; Ismail, N.; Al-Hendy, A. Mesenchymal Stem Cells Partially Reverse Infertility in Chemotherapy-Induced Ovarian Failure. *Human Reprod. Sci.* **2018**, *25*, 51–63.
13. Anna Pia Ferraretti, Luca Gianaroli, The Bologna criteria for the definition of poor ovarian responders: is there a need for revision?, *Human Reproduction*, Volume 29, Issue 9, 1 September 2014, Pages 1842–1845, <https://doi.org/10.1093/humrep/deu139>
14. Carlos Iglesias, Manish Banker, Nalini Mahajan, Leyre Herrero, Marcos Meseguer, Juan A. Garcia-Velasco, Ethnicity as a determinant of ovarian reserve: differences in ovarian aging between Spanish and Indian women, *Fertility and Sterility*, Volume 102, Issue 1, 2014, Pages 244-249,
15. Singh, Neeta & Dogra, Yogita & Mohanty, Sujata & Seth, Tulika. (2021). P-796 Trial of Autologous Marrow derived Stem Cell Ovarian Transplantation (TAMSCOT) in young infertile women with diminished ovarian reserve for ovarian rejuvenation – HOPE still persists. *Human Reproduction*. 36. 10.1093/humrep/deab130.79
16. Garavelas A, Michalopoulos E, Mallis P, Nikitos E. Rejuvenation of Ovarian Function after Autologous Platelet Lysate Injection: Promising Evidence from Confirmed Cases. *Clin J Obstet Gynecol*. 2023; 6: 225-232.
17. Banu J, Tarique M, Jahan N, Lasker N, Sultana N, Alamgir CF, et al. Efficacy of autologous platelet rich plasma for ovarian rejuvenation in infertile women having poor ovarian reserve. *Int J Reprod Contracept Obstet Gynecol* 2022; 11:2948-53.
18. Adegoke, B. O., Adegoke, B. . O., Lawal M. A., Dada, M. U., Obadeji, A., & Oluwole, L. O. (2024). Comparison of Quality of Life among Fertile and Infertile Women in a Developing Country. *Asian Research Journal of Gynaecology and Obstetrics*, 7(1), 1–11. Retrieved from <https://journalarjgo.com/index.php/ARJGO/article/view/205>
19. I. Ikeh, E., Mike, E., John, A., A. Oluwole, A., & Nneoma, I. (2017). Mycoplasma genitalium in Infertile and Pregnant Women in Lagos, Nigeria. *Asian Journal of Medicine and Health*, 4(3), 1–8. <https://doi.org/10.9734/AJMAH/2017/32825>
20. Karabulut A, Özkan S, Oğuz N. Predictors of fertility quality of life (FertiQoL) in infertile women: analysis of confounding factors. *European Journal of Obstetrics & Gynecology and Reproductive Biology*. 2013 Sep 1; 170(1):193-7.

UNDER PEER REVIEW