

Vaginoplasty for Acquired Gynaetresia secondary to insertion of herbal concoction in the vagina: Successful repair. - A Case Report.

Abstract.

Acquired Gynaetresia is more common in developing countries mostly due to unconventional crude treatment involving per vagina insertion of various caustic substances for various gynaecological purposes leading to tissue injury, alongside possible superimposed infection from unhygienic local substances and eventual healing by fibrosis. This case reports brings to fore a case of 32-year-old woman with four months history of absent menses following insertion of corrosive in the vagina to treat premature ovarian failure. This caused her severe vaginal stenosis which was subsequently corrected by surgery and serial dilatation.

Keywords; Acquired Gynaetresia, alternative medicine, vaginoplasty, penile moulds, amenorrhoea.

Introduction

Gynatresia, also known as vaginal stenosis or cicatrisation, is the narrowing or complete occlusion of the vaginal canal^{1,2,3}. Aetiology may be congenital or acquired^{1,2,3}. Congenital causes is commoner in the developed world while acquired causes mostly from surgery or radiotherapy which is rare^{1,2,3}. In Nigeria and most developing countries, acquired gynaetresia is more prevalent, mainly from the use of per vaginal herbal pessaries and concoctions aimed at treating uterine fibroids, menorrhagia, infertility, uterovaginal prolapse, or induced abortion or even female genital mutilation.^{2,5,6,7} Postpartum vaginal insertion of rock salts and many other concoctions aimed at achieving vaginal tightening or to restore the vagina to a nulliparous state is a common cause in Africa and the Arab world^{2,7,8}. Physical trauma from female genital mutilation and obstetric injuries are also factors in developing

countries. The ultimate mechanism is that of chemical vaginitis with healing by fibrosis^{7,9} or sepsis leading to fibrosis and then vaginal stenosis with eventual hematocolpos, haematometra if occlusion is complete^{5,10}.

The hypoestrogenic state created by lactational amenorrhoea in the postpartum period makes it easier for vaginal agglutination¹¹. This is more likely in the setting of retention of a foreign body in the vagina.¹²

Case report.

Patient was a 32-year-old para two with two previous caesarean sections. She has 4 years history of amenorrhoea following her last delivery, during which she visited a non-orthodox herbal practitioner who administered several corrosive substances to be inserted per vagina to induce menses. She subsequently noticed that she was unable to have penetrative vaginal intercourse afterwards that necessitated her presentation to our facility. She had no medical co-morbidity. Attempt at passing a paediatric vaginal speculum, nasal speculum or a single digital vaginal examination was unsuccessful. Pelvic ultrasound scan showed normal sized uterus and small sized ovaries. Her follicle stimulating hormone was 68 mIU/L suggestive of premature ovarian failure.

She had examination under anaesthesia, during which a size 5 Hagar's dilator under ultrasound guidance was passed through a "smiling" crease at the blind end of the short vagina with puckering/dimples at the two lateral edges of the crease. The probe was visualized and guided through the vaginal canal behind the crease and freely mobile side to side until it aborts at the cervical tissue. She was subsequently scheduled for vaginoplasty under general anaesthesia. The repair involved a repeat probing of the crease at its midline under pelvic ultrasound scan guidance, incisions were made on the lateral margins of the probe until it gets to the lateral ends, the site of puckering of crease. Gauze wrapped around

the index finger was used to bluntly dissect the vaginal tissues exposing raw areas superiorly and inferiorly until the cervix was visible in its entire circumference and the vagina could admit two fingers and a standard sized speculum. The cervical canal was successfully easily probed and entry into uterine cavity confirmed under pelvic scan. Haemostasis was maintained with a combination of pressure, 1:10,000 units adrenaline packing and a few interrupted polyglactin 2/0 sutures. Anti-adhesion barrier was placed over the raw vaginal areas superiorly and inferiorly. An improvised disposable penile mould was made using a lubricated condom containing an adult size maternity sanitary pad which patient was taught how to make one for personal use till comfortable for sexual activity with spouse. She was discharged on oral analgesics, antibiotics and seen weekly for next 3 weeks. She had good recovery and was later discharged from the clinic with good outcome.

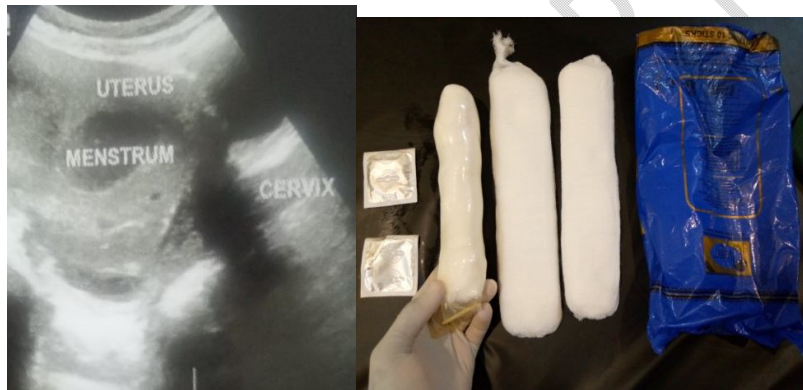

Fig. 1 & 2; Pre-operative pelvic scan showing haematometria , sanitary pads and condoms used to recreate penile mould respectively.

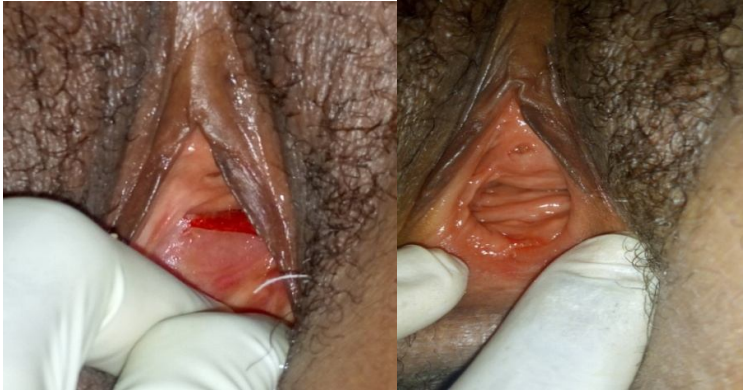


Fig. 3 & 4; Showing gynaetresia with raw surface on dissection and post operative vagina on follow up respectively

Discussion

In the developed world, **gynaetresia** is commonly congenital such as in Mayer-Kustner-Hauser syndrome while acquired vaginal stenosis or **gynaetresia** is rare mostly following radiation therapy or surgery^{1,2,3}. It may also occur with chronic graft-host reaction of bone marrow transplantation, also as part of Steven-Johnson syndrome and toxic epidermal necrolysis². Forgotten or **long-standing** foreign body retention in the vagina is also a factor¹².

Acquired **gynaetresia** is prevalent in developing nations where the prevalence and causes reflecting the extent of unskilled interventions and puerperal complications. The leading implicating factor of acquired **gynaetresia** in the tropics is the vaginal insertion of caustic herbal substances.^{1,2} Others are obstetric fistula repair and other complications of birth injuries and female genital mutilation^{1,2,6,7}.

The corrosive nature of the herbal pessaries and salts causes irritation and inflammation of the vaginal mucosa by inducing chemical vaginitis^{7,9}. This presents as severe pain or burning sensation, bleeding with or without infection in the early periods. Healing occurs by fibrosis alongside vaginal walls apposition, scarring, and subsequent partial or complete vaginal

occlusion^{5,6} This similar scarring or healing by fibrosis in the genital tract can also occur following female genital mutilation, a predominant practice in African countries.⁷

History may suggest the causative factor alongside dyspareunia and loss of sexual function.

There may also be dysmenorrhea and cryptomenorrhea if there is complete vaginal

Occlusion.¹ Diagnosis is clinical, typically defined as the inability to insert two fingers into the vagina on examination⁴. Haematocolpos, haematometra may be present on ultrasound if occlusion is complete in the pre-menopausal woman¹⁰.

Treatment of **gynaetresia** is mainly surgical. Cases with flimsy adhesions can be managed using vaginal dilators¹³. Dilation causes stretching of mucosa, allows for cellular mitosis and growth of new mucosa. Gynatresia with dense adhesions are not amenable to dilators alone due to loss of elasticity of de-vascularized scarred vagina tissues¹³. Surgical management takes the form of either simple excision or complete vaginal reconstruction depending on severity¹³. Adhesiolysis by division or excision combined with vaginal dilation is simpler with good outcome but more likely to be complicated by restenosis².

Surgical reconstruction procedures aimed at creating a neo vagina include one of autologous split thickness skin graft of anterior thigh or buttocks in McIndoevaginoplasty^{13,14}, pudendal thigh flap¹⁵, and the use of peritoneum and intestinal segment^{13,14,16}

Challenges of surgical reconstructive surgery include hair growth and numbness in the vagina with skin flaps or graft and excessive secretion when bowel loops are used¹⁶.

Postoperative dilators or moulds are important aids to the success of the reconstructive vaginal surgery by reducing the likelihood of restenosis or scarring^{7, 13,17}. Types of vaginal dilators or penile moulds are of no advantage over the other. Frequent peno-vaginal intercourse may also substitute¹⁸.

Conclusion.

Acquired Gynaetresiais common in developing nations for many reasons. Awareness and education of reproductive age women is paramount to reduce its burden and attendant consequences. It also highlights the difficulties women in developing countries face in the hands of un-orthodox practitioners. The continued damage of the female genital tract by these practitioners calls for a safeguarding concern.

Disclaimer (Artificial intelligence)

Option 1:

Author(s) hereby declare that NO generative AI technologies such as Large Language Models (ChatGPT, COPILOT, etc) and text-to-image generators have been used during writing or editing of manuscripts.

Option 2:

Author(s) hereby declare that generative AI technologies such as Large Language Models, etc have been used during writing or editing of manuscripts. This explanation will include the name, version, model, and source of the generative AI technology and as well as all input prompts provided to the generative AI technology

Details of the AI usage are given below:

- 1.
- 2.
- 3.

Reference;

1. Allen OO, Badejoko OO. Once treated, twice harmed: A case report of acquired gynatresia following vaginal insertion of herbs. Trop J ObstetGynaecol2019;36:472-3.
2. Kunwar S, Khan T, Gupta H. Case report: Acquired gynatresia. BMJ Case Rep 2014;2014:bcr2014203529
3. Umar AG, Ahmed Y, Garba JA, Adoke AU, Saidu AD, Hassan M. Successful pregnancy following acquired gynatresia. Ann Afr Med 2019;18:108-110
4. Allen OO, Badejoko OO. Once treated, twice harmed: A case report of acquired gynatresia following vaginal insertion of herbs. Trop J ObstetGynaecol 2019;36:472-3
5. Anzaku SA, Ahmadu D, Mikah S, Didamson GD. Cryptomenorrhoea due to acquired mid-vaginal atresia: A case report treated by vaginoplasty and serial vaginal dilatation. J Gynecol Infertility 2017;1:1.
6. Nakhal RS, Williams CE, Creighton SM. Chemical vaginitis: Implications and management. J Low Genit Tract Dis 2013;17:95-8.
7. Ugwu AO, Owie E, Olamijulo JA, Okorafor UC, Odo CC, Okoro AC. Epidermal Inclusion Cysts of the Clitoris Following Female Genital Mutilation: Case Series and Review of Literature. Nigerian Journal of Experimental and Clinical Biosciences 10(4):p 131-133, Oct-Dec 2022. | DOI: 10.4103/njecp.njecp_20_22.
8. Kaur G, Sinha M, Gupta R. Postpartum vaginal stenosis due to chemical vaginitis. J Clin Diagn Res: JCDR 2016;10:QD03.

9. Umar AG, Ahmed Y, Garba JA, Adoke AU, Saidu AD, Hassan M. Successful pregnancy following acquired gynatresia. *Ann Afr Med*. 2019 Apr-Jun;18(2):108-110. doi: 10.4103/aam.aam_12_18. PMID: 31070154; PMCID: PMC6521645.10. Kingston AE. The vaginal atresia of Arabia. *Br J ObstetGynaecol* 1957;64:836–9.
11. Howard TF, Lewicky-Gaup C. Postpartum vaginal agglutination: a case report. *Female Pelvic Med ReconstrSurg* 2012;18:188–9.
12. Simon DA, Berry S, Brannian J, et al. Recurrent, purulent vaginal discharge associated with long standing presence of a foreign body and vaginal stenosis. *J PediatrAdolescGynecol* 2003;16:361–3.
13. Adze, Joel A.; Bature, Stephen B.; Durosinlorun, Amina Mohammed; Caleb, Mohammed; Taingson, Matthew C; Moroof, Suleman O.1. Gynatresia with Cryptomenorrhea Following Cesarean Section after Failed Vacuum Extraction: Case Report in a 26-Year-Old Woman. *Nigerian Journal of Basic and Clinical Sciences* 19(1):p 84-86, Jan–Jun 2022. | DOI: 10.4103/njbcs.njbcs_15_21
14. Horowitz IR, Buscema J, Majmuda B. Surgical conditions of the vulva. In: Rck JA, Jones HW, editors. *TeLindes Operative Gynaecology*. 10th ed. India: Lippincott Williams Wolters Kluwer; 2008. p. 548-56
15. Ugburo AO, Mofikoya BO, Oluwole AA, et al. Pudendal thighflap in the treatment of acquired gynatresia from caustic pessaries. *Int J GynaecolObstet* 2011;115:44–8.
16. Kapoor R, Sharma DK, Singh KJ, et al. Sigmoid vaginoplasty: long-term results. *Urology* 2006;67:1212–15.
17. Ugwu AO, Harrison NE, Haruna M, Ayeni SA. Genital tuberculosis in a Nigerian woman with primary infertility. *Niger JMed* 2023;32:445-8.

18. The International Clinical Guideline Group. International Guidelines on Vaginal Dilation after Pelvic Radiotherapy. <http://www.ncsi.org.uk/wp-content/uploads/Inter-Best-Practice-Guide-Vaginal-Dilators-July-2012.pdf> (accessed 24 June 2024).

UNDER PEER REVIEW