

## **Laparotomy and cephalo-caudal cervical dilatation and stenting for severe cervical stenosis - A Case Report.**

### ***Abstract.***

Cervical stenosis can be congenital or acquired. Acquired causes could be through obliteration by mass effect or iatrogenically following cervical surgeries or more importantly in the tropics by cephalad extension of severe acquired gynaetresia induced by per vagina insertion of various corrosive agents for treatment of gynaecological ailments or vaginal tightening postpartum. This is a case report of severe cervical occlusion as part of severe acquired gynaetresia with non-visualization of the cervix even after vaginal reconstructive surgery presenting with amenorrhoea. Oral contraceptive pills induced cryptomenorrhea with pelvic ultrasound demonstrating haematometra. She had laparotomy and utero-cervical cannulation/stenting to allow for fertility treatment.

**Keywords; Cervical stenosis, gynaetresia, laparotomy, retrograde uterocervical cannulation/stenting.**

### **Introduction**

Cervical stenosis is the narrowing or constriction of the cervix <sup>1</sup>. It can occur congenitally as part of müllerian anomalies <sup>1,2</sup>. It can also be acquired as one of endocervical scar tissue contraction, agglutination of traumatized raw surfaces or the obliteration by a mass <sup>2</sup>. A common cause in the tropics is its occurrence as part of extensive intra-uterine adhesion and extensive acquired gynaetresia with cephalad extension due to per vagina insertion of various

unproven corrosives substances intended for relief of gynaecological disorders and infertility<sup>3</sup>.

Cervical surgeries such as cone biopsy, cauterly, laser surgery and irradiation have been implicated in tissue scarring<sup>1,4</sup> Granulomatous infections such as genital tuberculosis have been implicated in some cases acquired gynaetresia and cervical stenosis, although very rare.<sup>5</sup> Inadequate visualization of the endocervix due to cervical stenosis during colposcopy necessitating a cone biopsy may worsen existing stenosis<sup>1</sup>. The narrowing is usually in the region of the internal os.<sup>1</sup>

Physiological hypoestrogenic states of menopause, lactation, the iatrogenic hypoestrogenic state caused by extended medroxyprogesterone depot injection and diethylstilbesterol exposure makes the endocervix prone to agglutination after cervical trauma<sup>1,2</sup>.

The post-menopausal patients tend to be asymptomatic until development of one of haematometra, pyometra or hydrometra<sup>1,2,5,6</sup>. The pre-menopausal patients may present with non-fertility related symptoms such as worsened or new onset dysmenorrhoea due to increased uterine pressure needed to achieve menstrual outflow through the stenosed os, pelvic pain or abnormal bleeding if the obstruction is partial and amenorrhoea if obstruction is complete<sup>1,2</sup>. The infertility related symptoms are those of endometriosis consequent to retrograde menstruation, inability to cannulate the cervix for gametes or embryo(s) transfer and the dye instillation for fertility work-up<sup>1,2</sup>. Obstetric complications are consequence of failed induction of labour and cervical dystocia<sup>2</sup>.

Examination may not reveal any findings if obstruction is partial while a soft, bulky uterus may be felt if obstruction is complete. Ultrasound examination demonstrates fluid-containing uterine cavity. The inability to introduce a 1- to 2-mm dilator transcervical into the uterine cavity is usually diagnostic<sup>7</sup>. Other accepted diagnostic criteria include; the inability to pass

a fine probe, endocervical brush, or cotton-tipped applicator and the dye retention in the uterus on radiography<sup>1</sup>.

In-vitro model experiments set a cervical os diameter of 5mm as satisfactory patency and less than 2mm associated with retention and backflow<sup>8</sup>.

### **Case Report**

Patient was a 34-year-old nulliparous lady with primary infertility of 6 years duration. Four years earlier, she had attempted in-vitro fertilization (IVF) which was aborted due to her non-response to ovarian stimulation expectedly as her serum anti-mullerian hormone (AMH) was suggestive of ovarian failure on 3 independent occasions (0.01ng/ml, 0.01ng/ml and 0.03ng/ml). She sought unorthodox local traditional care for fertility purposes two years after the botched IVF due to her aversion for donor oocytes -IVF and had per vagina insertion of unknown corrosive pessaries leading to local vaginal tissue injury and scarring and eventual gynaetresia and amenorrhoea. She subsequently had vaginoplasty 6 months after developing gynaetresia involving pudendal thigh flap. Six months after vaginal reconstructive surgery she had menses only upon initiation with combined oral contraceptive pills (COCP) usage. Two years after surgery she now no longer sees menses despite COCP usage. Examination revealed a short vaginal canal (1.5cm in maximum depth) lined by grafted stratified squamous epithelium with significant hair growth and sebum production typical of pudendal donor skin region. On both lateral inner pudendal thigh regions were scar evidence of missing skin used for vaginoplasty. Single digital and paediatric and nasal speculum examination of vaginal canal was not visible except for manual parting to expose the blind ending vagina with no visible cervical tissue. Pelvic scan revealed a normal sized uterus and endometrial stripe was visible. She was given a repeat COCP after which she had pelvic cramping and a follow-up pelvic scan during cramping revealed haematometra without any ballooning of

cervical region suggestive of outflow obstruction up to the region of the internal cervical os. She was counselled on the findings. Several attempts under sedation at probing with size 5 Hagar's dilator and uterine sound under pelvic scan guidance were unsuccessful due to the significant thickness of the neo-vagina skin with risk of bladder and bowel injuries with further forceful persistence. She was counselled and consented to laparotomy under spinal anaesthesia during which the uterus had a size a size 16 Foley catheter tied at the cervico-isthmic junction as a tourniquet to reduce bleeding. An anterior incision was made on the uterus deep to the endometrium and a cephalo-caudal or retrograde uterocervical serial dilatation was done using Hagar's dilator up to size 7 from the internal os until tip of dilators were felt and seen in vaginal canal. A long artery Forcep was used to grasp a paediatric size 8 Foley catheter from the vagina end into the endometrial cavity and inflated and the with uterus closed over the bulb and catheter in layers while adequate haemostasis was secured after removal of cervico-isthmic tourniquet and abdomen closed up in layers. The cervical stent made of Foley catheter was removed after 14 days and patient now bleeds upon use of COCP. Cervico-uterine patency was achieved and confirmed by successful passage of uterine sound per vagina subsequently ahead of donor egg IVF.

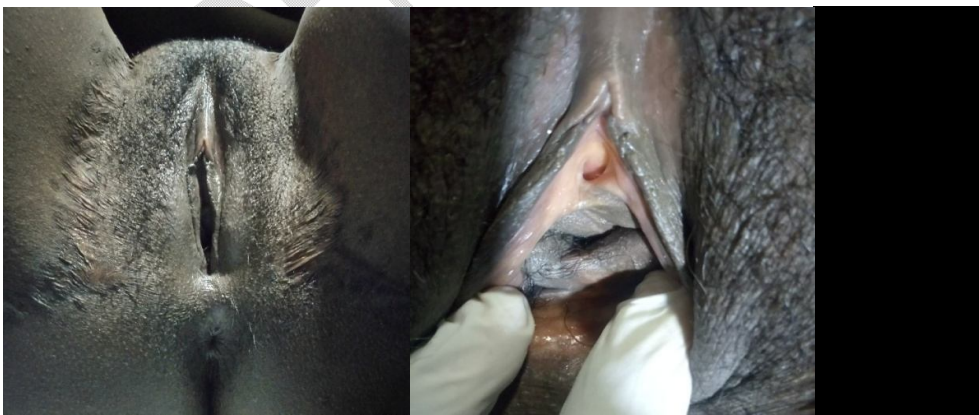

Fig. 1 & 2 ( upper frames) ; perineum and short blind-ending vagina following vaginoplasty for severe acquired gynaetresia with associated cervical stenosis.

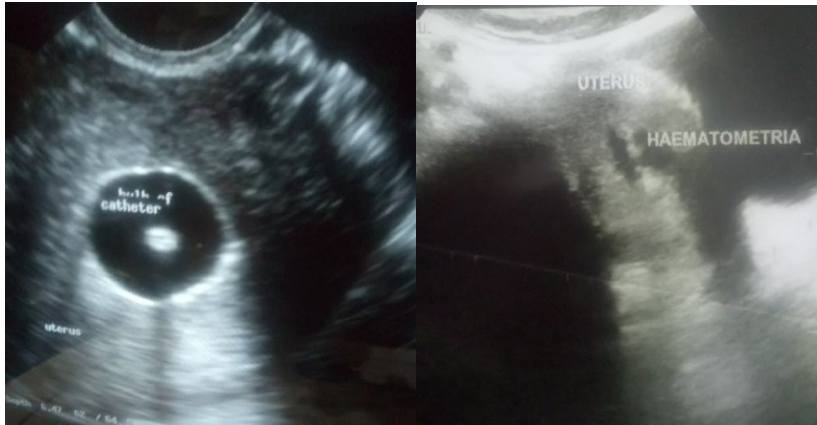


Fig. 3 & 4 (lower frames); intrauterine size 8 Foley catheter and haematometria seen pre-operatively on pelvic scan respectively.

### **Discussion**

Treatment could be offered to relieve non-fertility related issues such as amenorrhea, dysmenorrhea, pelvic mass, pelvic discomfort and the inability to view or sample the endocervix or the endometrium. Fertility indications include; the inability to cannulate the cervix for contrast instillation during work-up and to enable access for transfer gametes or embryos.

Serial dilation with dilators preferably under ultrasound guidance has been the traditional first line treatment <sup>1,9</sup>. Cervical priming with misoprostol may make this procedure easier especially where a dimple is visible. Traditional dilatation is associated with high recurrence <sup>1</sup>. Monthly laminaria tents are option for recurrence. <sup>10,11,12,13</sup>.

Hysteroscopic cervical resection is known to be safe and effective treatment for cervical stenosis, and associated infertility by allowing for successful embryo transfer or semen Insemination <sup>14</sup>. This will not be suitable in this case where the vaginal canal is not accessible and no cervical dimple or stump is visible.

Carbon dioxide laser treatment has been documented <sup>2</sup>. The injecting of botulinum toxin has also been documented to be useful <sup>15</sup>.

Complications of transvaginal attempt at treatment include; creation of false passages, cervical perforation and uterine perforation which may be associated with bleeding and infection, vasovagal reaction to cervical manipulation, failure to complete the procedure, possibility of an unsuccessful procedure at a single attempt and recurrence of stenosis <sup>1,2</sup>. A transmyometrial embryo transfer to complete IVF has been reported in the setting of repeated failed attempts at dilatation. <sup>16</sup>.

Severe cervical stenosis often seen in the tropics following per vagina insertion of unorthodox corrosive substances for various gynaecological symptoms may cause complete distortion of cervical anatomy with a cervix flushed with the vagina and an absence of cervical dimple. This makes attempts at transvaginal dilatation or cannulation challenging and very dangerous even under pelvic scan guidance due to risk of bladder, bowel and uterine perforation. This has resulted in an unusual and uncommon treatment modality such as one employed in the case presented above involving laparotomy, retrograde uterocervical cannulation with a paediatric Foley catheter and metroplasty which comes with all the risk of

laparotomy. Plastic reconstructive surgeries in general usually gives better outcome at primary attempt with no guarantee at repeat attempts hence a repeat reconstructive surgery to attempt exposing the cervix was not considered by the patient.

Obstetric complications follows a spectrum ranging from ; post term pregnancy , failed induction of labour, cervical dystocia, arrest of cervical dilatation and delivery by caesarean section are the common presentation<sup>2, 16</sup>. Complete occlusion may result in absence of postpartum lochia<sup>2</sup> There is also the challenge about compliance of cervical outlet for uterine evacuation in the setting of fetal demise.

Prophylactic placement of a temporary cervical stent following cervical dilation for a few days and following a cone biopsy or cauterly could be preventive. Placement of temporary stent using a paediatric Foley catheter during removal of paracervical/juxta cervical fibroids during myomectomy may also be preventive. Access to quality healthcare alongside public enlightenment to discourage the per vagina insertion of corrosive agents which may obliterate both the vagina and adjoining cervical os.

### **conclusion**

In conclusion, severe acquired cervical stenosis especially those caused by caustic agents leading to the cervix being flushed to the vagina and absence of cervical dimple as may be seen in the tropics may require unconventional non-per-vaginal treatment modality of laparotomy and retrograde uterocervical cannulation with a paediatric Foley catheter and metroplasty.

### **Consent**

A written informed consent was obtained from the patient for publication of this case report.

## Reference

1. Frishman GM. Treatment of Cervical Stenosis. In: Seifer D.B, Collins R.L. (eds) Office-Based Infertility Practice. Springer, Berlin, Heidelberg 2002; 14:149-149.
2. Ondieki DK, Wanyoike- Gichuhi J. Obstetric complications of cervical stenosis: Case report. *East Afr Med J* 2015; 92(11): 568-570.
3. Umar AG, Ahmed Y, Garba JA, Adoke AU, Saidu AD, Hassan M. Successful pregnancy following acquired gynatresia. *Ann Afr Med* 2019 ;18:108-110
4. Baldauf JJ, Dreyfus M, Ritter J. Risk of cervical stenosis after large loop excision or laser conisation. *ObstetGynecol* 1996; 88: 933-938.
5. Ugwu AO, Harrison NE, Haruna M, Ayeni SA. Genital Tuberculosis in a Nigerian Woman with Primary Infertility. *Nigerian Journal of Medicine* 32(4):p 445-448, Jul–Aug 2023. | DOI: 10.4103/NJM.NJM\_41\_23.
6. Goldstein SR. Postmeopausal endometrial fluid collections revisited: look at the doughnut rather than the hole. *ObstetGynecol* 1994; 83: 738-740.
7. Katz V.L, Lentz G.M. and Lobo R.A. Benign Gynecologic lesions in *Comprehensive Gynecology*. 5th Edition. Mosby Elsevier, Philadelphia, USA. 2007; 18.
8. Barbieri RL, Callery M, Perez S.E. Directionality of menstrual flow: cervical os diameter as a determinant of retrograde menstruation. *Fertil Steril* 1992; 57:727.
9. Hornstein MD, Osathanondh R, Birnholz JC et al. Ultrasound guidance for selected dilatation and evacuation procedures. *J Reprod Med* 1986; 31: 947-950.
10. Yang J, Zhu L, Lang J. Vascular stent as treatment for refractory cervical stenosis. *Chin Med J (Engl)* 2014; 127(5): 986-7.

11. Kovachev E, Ivanon S, Hinev A, et al. Clinical application of the natural cervical dilators (Laminaria) in obstetrics and gynecology. *Akush Ginekol (Sofia)* 2011; 50(2): 36-38.
12. Stern JL. Preventing cervical conisation by achieving satisfactory colposcopy with hygroscopic cervical dilators. *Am J ObstetGynecol* 1990; 163: 176-177.
13. Johnson N, Crompton AC, Wyatt J, et al. Using lamitel to expose high cervical lesions during colposcopic examinations. *Br J ObstetGynaecol* 1990; 97: 46-52.
14. Lin Y-H, Hwang J-L, Huang L-W, et al. Efficacy of hysteroscopic cervical resection for cervical stenosis. *J Minim Invasive Gynaecol* 2013; 20(6): 836-41.
15. Van den Berg C, Cronje H.S. Cervical stenosis relieved by botulinum toxin an injection. *Int J Gynaecol Obstet.* 2011; 112(3):243.
16. Sulliva-Pyke C.S, Kort D.H, Sauer M.V, et al. Successful pregnancy following assisted reproduction and transmyometrial embryo transfer in a patient with anatomical distortion of the cervical canal. *SystBiolReprod Med* 2014; 60(4): 234-238.