

## Case report

# “A case report on challenges in retrieving an ingested mobile phone”

Abstract:

Background:

This case report discusses our experience of managing a rare case of mobile phone ingestion by trial of endoscopy followed by surgery.

Presentation of case:

A 25 year old male prisoner presented with history of 9 days old foreign body ingestion with dull aching upper abdominal pain . Clinical examination was unremarkable. Serial radiograph monitoring was done and patient was posted for endoscopic removal of foreign body. A semi opened mobile phone noted and due to its bigger size and difficulty in aligning using available retrieval devices, only back cover with battery was removed. Patient was posted for elective surgery to remove the remaining device and the body of the mobile was retrieved. Patient had an uneventful recovery and was discharged on post operative day 8.

Discussion:

Mobile phone ingestion is a rare encounter with no standard approach. Usage of endoscopy for large foreign body retrieval is questionable considering the available devices. Direct surgical approach not only saves time and energy, but also skips complications of endoscopy and frequent anaesthesia.

Conclusions:

Endoscopic retrieval of large foreign bodies, like mobile phones, may be challenging and may require surgical intervention. Modification in existing retrieval devices to assure better grip and alignment in endoscopy can be helpful for retrieval of larger foreign bodies, and pre-endoscopic dimension of foreign body should be noted and accordingly feasibility of retrieval should be taken into account.

Key words: foreign body, retrieval, stomach, endoscopy, gastrotomy

## Introduction:

Encounter of unintentional and intentional foreign body ingestion in emergency department is relatively common. Unintentional ingestion is mostly encountered in paediatric population, more commonly with developmental delay and intentional foreign body ingestion mostly encountered in prisoners; moreover, it may also be seen with psychiatric disorders, substance abuse.<sup>1</sup> **ESGE recommends urgent (within 24 hours) therapeutic esophagogastroduodenoscopy for foreign bodies in the stomach such as sharp-pointed objects, magnets, batteries, and large/long objects and suggests nonurgent (within 72 hours) therapeutic esophagogastroduodenoscopy for medium-sized blunt foreign bodies in the stomach.**<sup>2</sup> Foreign body ingestion can present as, respiratory distress, foreign body sensation, abdominal pain, chest pain, vomiting, obstipation, bloody stools<sup>3</sup> depending on location and systemic symptoms in case of poisonous foreign bodies like lithium containing batteries. Lithium toxicity can lead to local injury like ulceration, perforation, or fistula formation.<sup>4</sup>

Mobile phones have secondary batteries which are rechargeable and can be used repeatedly. These batteries are usually cadmium, nickel metal hydride or lithium ion.<sup>5</sup> Nickel, cadmium and lithium are heavy metals and serious complications like respiratory distress, bone pain, sterility, abortions, renal stones<sup>6</sup>, heart block, renal failure, encephalopathy<sup>7</sup>. Mobile phone ingestion is very rare and only four cases have been reported among which only one showed that it could be removed endoscopically.<sup>8</sup>

**This case report analyses how to remove an unusual and large foreign body.**

## Presentation of case:

History: A 25 year old **male** prisoner with a history of nine days old intentional ingestion of mobile phone which he smuggled in jail presented to the emergency department **with complaints of dull aching upper abdominal pain.**

Clinical examination- unremarkable.

Investigations- Radiological investigations were done to confirm the foreign body. Serial radiographs confirmed the foreign body remained in situ in the stomach.

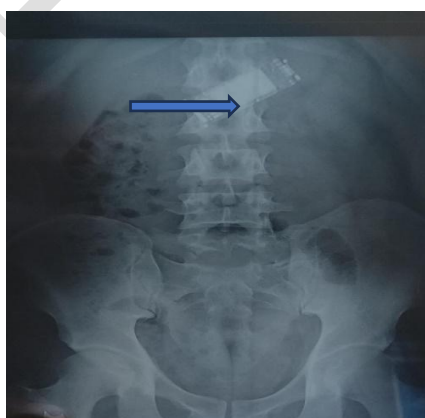

Fig 1: Erect XRay abdomen showing foreign body in stomach.

Contrast enhanced scanning of abdomen and pelvis was done for confirmation of site and number of foreign bodies which stated a single foreign body, likely an electronic gadget was present in the antrum of stomach.

Management- A decision to remove the foreign body using upper gastrointestinal endoscopy under sedation was made. A semi-opened mobile phone was noted. After multiple failed attempts using snare and basket, battery and back cover was retrieved with difficulty using rat toothed forceps, followed by which multiple attempts to retrieve the body of the mobile was made but was unsuccessful. **Size of the device, with its un mouldable nature posed difficulty to align the device during endoscopy.** Patient was posted for surgery **to remove the remaining device, as it would not pass through the pylorus.**



Fig 2 and 3: Endoscopic image of mobile phone; battery and back cover of endoscopically retrieved mobile phone

A four cm upper midline incision was made and the phone was delivered through an anterior gastrotomy, with an abdominal drain placement in Morrison's pouch which was removed at post op day 7. The patient made an uneventful recovery with drain removal on day 7 and was discharged on post operative day 8.

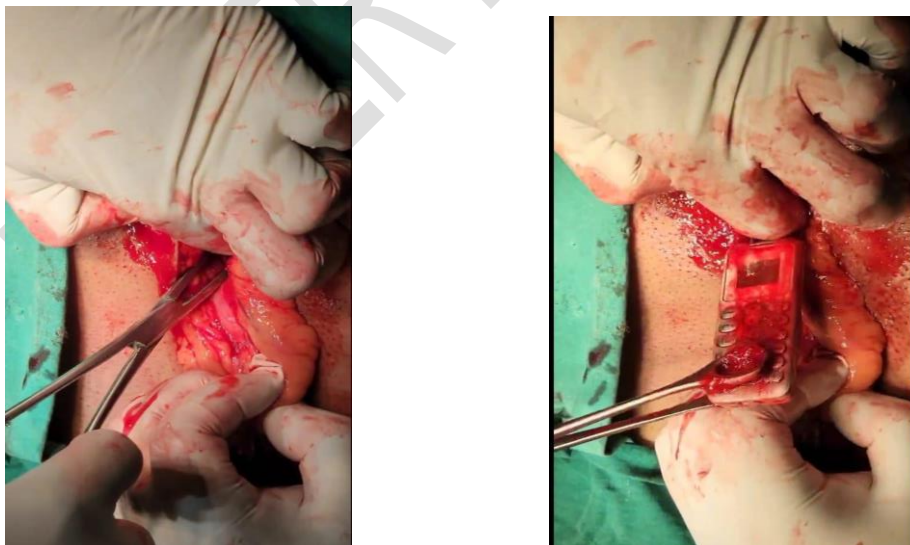


Fig 4 and 5: Body of mobile phone removal by anterior gastrotomy

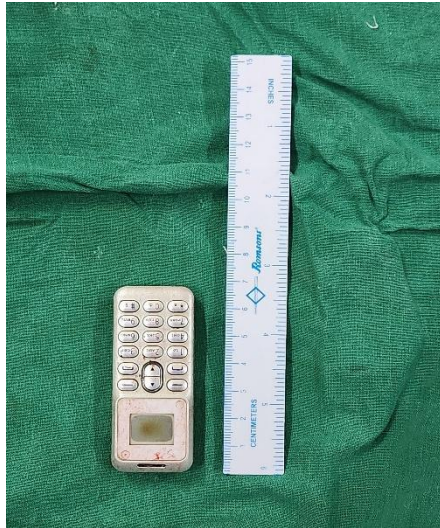

Fig 6 and 7: Surgically retrieved image of Chinese Kencheoda mobile phone; 4 cm upper midline laparotomy post skin closure wound.

#### Discussion:

Cricopharynx, the upper oesophageal sphincter is the narrowest part of upper digestive tract<sup>9</sup>, other potential sites for foreign body entrapment in gastrointestinal tract are lower oesophageal sphincter, pylorus, ileocecal junction. In our case we encountered with mobile phone in antrum of stomach which couldn't pass through pylorus, the mobile phone had dimensions of 6.4x2.2x1.2cm. Foreign body in stomach can be managed conservatively with watchful monitoring, but in our case, it was a mobile phone containing heavy metal battery. Mobile phone having batteries made of heavy metals must be considered for removal to avoid disastrous complications like ulceration, perforation, peritonitis but there is no standard approach as mobile phone ingestion is rarely encountered. Very few articles have been found regarding mobile phone ingestion, and majority articles concluded surgical removal as a better option.<sup>10</sup>

In our case, patient was a 25 years old male prisoner who intentionally ingested mobile phone. Considering the age and unremarkable examination findings, a decision to proceed with a relatively lesser invasive procedure of endoscopy was made, and surgery was avoided initially. **The result of Endoscopy was not very satisfactory.** Even after multiple attempts using various retrieval devices, only battery and back cover could be recovered and the patient ultimately had to undergo surgery. The failure of endoscopy to remove the mobile phone, highlights the limitations of this approach.

**Very few cases of mobile ingestion have been reported and in all cases endoscopy trial were given but ended with similar results. The size and difficulty to orient the device was the major challenge.**

#### Conclusion:

Considering the current endoscopic devices available, surgical retrieval is preferred to avoid unnecessary delay and complications of endoscopy. The dimensions of mobile phone should be considered before endoscopy. Retrieval of smaller dimension gadgets can be attempted with current available endoscopic devices considering the semi-successful nature of

endoscopic retrieval in our case. Devices with better grip can be made and a trial of endoscopic simulation on dummy with similar foreign body can be done.

## Disclaimer (Artificial intelligence)

I hereby declare that NO generative AI technologies such as Large Language Models (ChatGPT, COPILOT, etc) and text-to-image generators have been used during writing or editing of manuscripts.

### References:

1. Obinna obinwa et al, David Cooper et al, James M.O Riordan et al; An ingested mobile phone in the stomach may not be amenable to safe endoscopic removal using current therapeutic devices, international journal of surgery, volume 22, 2016.
2. Michael Birk et al, Peter Bauerfeind et al, Pierre H. Deprez et al, Removal of foreign bodies in the upper gastrointestinal tract in adults: European Society of Gastrointestinal Endoscopy (ESGE) Clinical Guideline, 2016
3. Gregory P. Connors et al, Michael Mohseni et al, Donna Wallace et al, Pediatric Foreign Body Ingestion, statpearls PubMed, June 2023
4. Dijkstra B et al, Gibson J. et al, Disc Battery ingestion, Newman RK et al, statpearls PubMed, Aug 2023
5. Renner Nrior et al, Baridilo Gboto et al, Comparative toxicity of spent mobile phone batteries. IOSR Journal of Environmental Science, Toxicology and Food Technology, Volume 11, August 2017.
6. Bar-Sela S et al, Levy M et al, Westin JB et al, Laster R et al, Richter ED et al. medical findings in nickel-cadmium battery workers. Isr J Med Sci. Sep 1992
7. Gaetani SL et al, Amaducci A M et al, Fikse D et al, Koons AL et al. Lithium Toxicity: A Case Report of Toxicity Resulting in a Third-degree Heart Block. Clin Pract Cases Emerg Med. 2024 Feb
8. Dragasevic S et al, Lalosevic MS et al, Toncev L et al, Milovanovic T et al, Markovic AP et al, Djuranovic S et al, Popovic D et al. The cell phone in the twenty-first century: Risk for addiction or ingestion. World J Emerg Med. 2021
9. Fazal L Wahid et al, Habib Ur Rehman et al, Iftikar Ahmad Khan et al. Management of Foreign Bodies of Upper Digestive Tract; Indian Journal Otolaryngol Head Neck Surg. 2014 Jan
10. Qureshi et al, Nafees et al, Cherian et al, Endoscopic Retrieval of an Intentionally Ingested Mobile Phone in an Adult: First Case Report of its Kind; Annals of Clinical Case Reports, 2016.

UNDER PEER REVIEW