

# Indocyanine green compared to technetium-99m in sentinel node detection in breast cancer: A single-center retrospective study

*Abstract :*

**Introduction:** Sentinel lymph node biopsy (SLNB) is a standard procedure in the surgical management of early-stage breast cancer. While the Tc99m radioisotope technique is the gold standard for SLNB, indocyanine green (ICG) fluorescence imaging has emerged as a potential alternative. Our study aimed to evaluate the concordance between ICG and Tc99m in detecting axillary sentinel lymph nodes (SLNs) in breast cancer patients.

**Materials and Methods:** We conducted a retrospective single-center study between January 2021 and October 2021. Patients with localized breast cancer and indication for axillary SLNB were included. Preoperative Tc99m lymphoscintigraphy and intraoperative ICG fluorescence imaging were performed. The primary outcome was the concordance rate between the two methods in detecting SLNs.

**Results:** Eleven patients with a total of 34 SLNs were included. The detection rate was 94.1%, with 32 SLNs detected by ICG and 23 by Tc99m. Concordance between the two methods was 67.6%. All discordant SLNs (26.5%) were ICG positive/Tc99m negative, including one micrometastatic SLN detected only by ICG. No complications related to ICG use were observed.

**Conclusion:** Our study suggests that ICG could be a promising alternative to Tc99m for SLNB in breast cancer, potentially offering higher sensitivity. However, larger prospective studies are needed to confirm these findings and establish standardized protocols for ICG use.

*Keywords: Breast cancer, sentinel lymph node biopsy, indocyanine green (ICG), technetium-99m (Tc99m), fluorescence imaging, radioisotope, axillary lymph nodes, concordance, sensitivity.*

## Introduction

The surgical management of localized breast cancer necessitates the identification and biopsy of the sentinel lymph node (SLN), the initial site of axillary lymphatic drainage. This procedure, now standard for tumors staged T0, T1, and T2 up to 5 cm in the absence of clinical or radiological lymph node involvement [1,2], has significantly reduced the morbidity associated with axillary surgery by limiting the need for complete axillary lymph node dissection [3,4].

The gold standard technique for SLN detection relies on technetium-99m (Tc99m) radioisotope labeling, often combined with a dye [5,6]. However, this approach has drawbacks, including the need for a nuclear medicine department, discomfort associated with radiotracer injection, and radiation exposure for both the patient and medical personnel.

A promising alternative is the use of indocyanine green (ICG), a near-infrared fluorophore easily detected intraoperatively with a specialized camera [7,8]. Although not extensively studied in this context, ICG could offer a simpler and less invasive approach for SLN biopsy.

Our study aims to assess the concordance between ICG and Tc99m in detecting axillary SLNs during breast cancer surgery, to determine whether ICG can serve as a reliable alternative to the standard method.

## Materials and Methods

We conducted a retrospective single-center study at the National Oncology Institute Sidi Mohammed Ben Abdellah in Rabat between January 2021 and October 2021.

### Patient Selection

Inclusion criteria were the presence of localized breast cancer with an indication for axillary SLNB and consent for ICG use. Exclusion criteria were palpable axillary lymphadenopathy, tumor size exceeding 3 cm, prior breast surgery, or hepatic or renal insufficiency.

### Surgical Protocol

The day before surgery, each patient received a subcutaneous injection of 0.4 mL of Tc99m at the areola. Detection scintigraphy was performed after the injection to determine the number of lymph nodes detected in the axilla.

In the operating room, under general anesthesia, we injected 0.4 mL of a 5 mg/mL ICG solution at four periareolar cardinal points. Using an infrared camera, we visualized the lymphatic pathway towards the axillary region in real time. The pathway was marked with a skin marker, and the skin incision was made where the light path disappeared into the axilla.

The SLN(s) was/were visualized with the infrared camera upon opening of the clavipectoral fascia. After excision of the fluorescent SLN(s), we verified with a gamma detection probe whether they were positive (concordant SLNs) or not (discordant SLNs) for radioisotope labeling.

Finally, we used the gamma probe to check for any non-fluorescent but Tc99m-positive SLNs remaining in the axilla. If residual radioactive labeling corresponding to an activity greater than 10% of the most radioactive SLN was present, we proceeded with the excision of the remaining SLNs.

## Results

Our study, conducted between January and October 2021, included 11 patients with breast cancer, with a mean age of 49.5 years (range: 29-70 years). In these patients, a total of 34 SLNs were identified and resected, demonstrating a high detection rate of 94.1%.

The combined use of ICG and Tc99m revealed a discordance between the two methods. Indeed, 94.1% of SLNs were ICG positive, while only 67.6% were Tc99m positive. Among the 4 metastatic SLNs identified, 3 were detected by both methods, while one micrometastatic SLN was detected only by ICG.

Notably, all discordant SLNs (26.5%) were Tc99m negative but ICG positive, highlighting the ability of ICG to detect SLNs missed by Tc99m. No SLNs were negative by both techniques, and no complications related to ICG use were observed.

Table 1 Number of sentinel lymph nodes per patient.

GS	ICG	Tc
0	0	1
1 (2)	2	4
2 (3)	3	3
3 (3)	3	1
4 (1)	1	1
5 (1)	1	0
6 (1)	1	1

GS: sentinel lymph node; ICG: indocyanine; Tc: Technetium 99.

## Discussion

### Advantages of ICG Compared to Tc99m

The use of ICG for SLN detection in breast cancer offers a promising alternative to Tc99m. ICG has advantages such as greater accessibility, no radioactive waste, and excellent tolerability.

While the meta-analysis by White et al. (2023) emphasizes the superiority of ICG over patent blue and its non-inferiority, or even superiority, to Tc99m, our study, with a concordance rate of 90.6% between ICG and Tc99m, demonstrates results comparable to those of other studies like Ballardini et al. (2013) with 93.5%. These results suggest that ICG, with adequate expertise, can rival Tc99m in terms of accuracy and reliability. [9][11][13]

However, determining the optimal dose of ICG remains a challenge, and further research is needed to establish a standardized protocol.

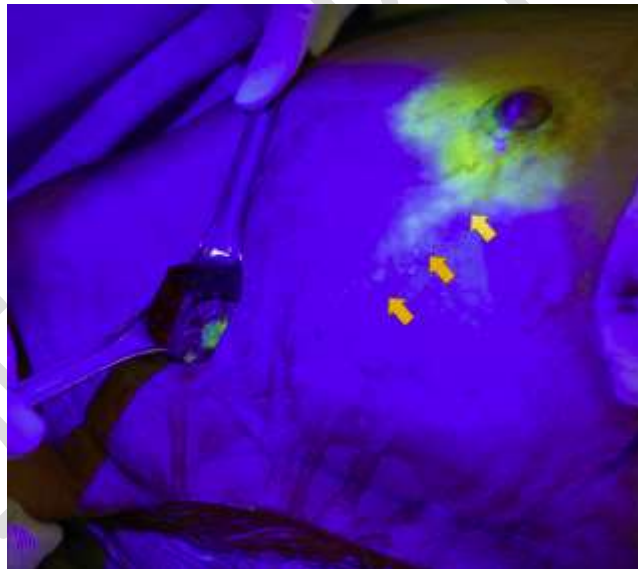


Figure 1. A percutaneously observable lymphatic flow line (arrow).

### ICG Injection Dose

Determining the optimal ICG dose for reliable SLN detection remains a challenge. Our study used a dose of 0.4 mL at 5 mg/mL, similar to that used in other research. However, the literature reports variable injection protocols, with doses ranging from 0.05 mg to 1.25 mg/kg of body weight, and sometimes contradictory results. [10][11]

This lack of consensus can be partly attributed to the quenching phenomenon, where ICG fluorescence decreases at high concentrations. This phenomenon could explain why some studies report decreased SLN detection with higher ICG doses. [13]

Our study, with a limited sample size, did not allow us to assess the impact of the ICG dose on SLN detection. Future research, including a larger number of patients and exploring different ICG doses, is needed to determine the optimal dose considering the quenching phenomenon and individual patient characteristics, such as body weight and tumor size. The ultimate goal is to establish a standardized protocol for ICG injection, ensuring more reliable and comparable results across studies.

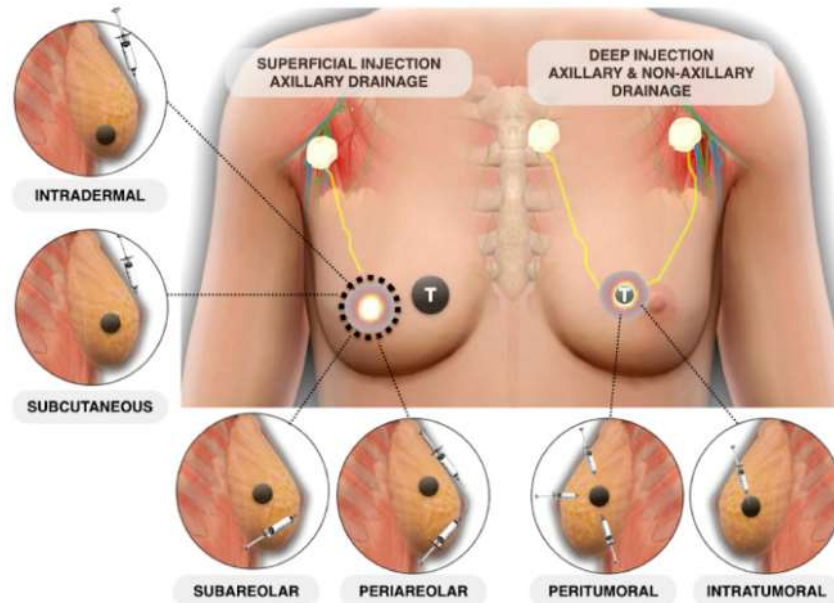


Figure 2 illustrates potential radiotracer injection sites and techniques for sentinel lymph node mapping and biopsy. Superficial injections, shown on the left, primarily result in drainage to the axillary lymph nodes. On the right, injections into deeper tumors (T) can lead to drainage to both axillary and non-axillary lymph nodes (14)

### ICG vs. Tc99m Concordance Rate and ICG Detection Performance

Our study revealed a concordance rate of 67.6% between ICG and Tc99m for SLN detection in breast cancer. This result is lower than those reported in several previous meta-analyses, notably that of White et al. (2023), which demonstrated the non-inferiority, or even superiority, of ICG compared to Tc99m and patent blue. [9][10]

In our analysis, we observed a high rate of Tc99m false negatives (6%), i.e., cases where the SLN was not detected by Tc99m but was identified by ICG. This rate is comparable to that reported by Samorani et al. (2015) (22.3%), suggesting that ICG might be more sensitive than Tc99m in SLN detection. This observation is particularly concerning, as false negatives can lead to underestimation of disease stage and inadequate treatment. [12][13]

Although our study did not perform a separate analysis by case and by node, as recommended by the meta-analysis of White et al. (2023), our overall results suggest that ICG could be an interesting alternative to Tc99m for SLN detection. However, the limited size of our sample (11 patients) limits the scope of our conclusions. [9]

Several factors could explain the variation in concordance rates between studies, including surgeon experience, study duration, intraoperative ICG contamination, and differences in injection protocols. Future studies, with larger sample sizes and using standardized methodology, are needed to more accurately assess the performance of ICG and Tc99m in SLN detection. [9][10]

Table 2 : Main studies comparing ICG and Tc in the detection of GS in breast cancer.

Study	No. of patients	GS	ICG+/Tc+	ICG+/Tc-	ICG-/Tc+	ICG-/Tc-
Ballardini and al. (2013)	134	246	93,5 %	6,1 %	0,4 %	0
Samorani and al. (2015)	301	458	76,7 %	22,3 %	1 %	0
Guenane and al. (2016)	40	53	90,6 %	0 %	9,4 %	0
Akhdamch and al.	11	34	67,6 %	26,5 %	6 %	0

ICG: indocyanine; Tc: Technetium 99; GS: sentinel lymph node; No patients: number of patients included in the study; GS: total number of GS resected.

### Analysis of Discordant SLNs

The analysis of discordant SLNs reveals a predominance of Tc99m false negatives (26.5%) in our study, unlike previous studies where ICG false positives were more frequent. This high rate of Tc99m false negatives is comparable to that observed by Samorani et al. (2015) (22.3%), suggesting better ICG performance [12]. However, the rate of ICG false positives may increase with surgeon experience and sample size, which was not observed in our study, possibly due to the limited sample size and a faster learning curve for ICG. Nevertheless, the recent meta-analysis by White et al. (2023) confirms the superiority of ICG over patent blue and its non-inferiority, or even superiority, to Tc99m, alone or in combination with patent blue. This meta-analysis also demonstrated high consistency in the superiority of ICG over patent blue, with significant differences in most comparisons, thus reinforcing the validity of our results [9][10]. Further studies, ideally randomized controlled trials (RCTs), on larger samples are needed to confirm these observations and assess the clinical impact of Tc99m false negatives, as well as to further explore the potential superior performance of ICG compared to Tc99m. [11][12]

### Conclusion

Our retrospective study, although limited by sample size, highlights the potential interest of ICG as a promising alternative to Tc99m for sentinel lymph node detection in breast cancer. The results suggest increased sensitivity of ICG compared to Tc99m, with a lower false-negative

Abbreviations: SLNB (sentinel lymph node biopsy), ICG (indocyanine green), Tc99m (technetium-99m), SLN (sentinel lymph node), NIR (near-infrared).

### References :

- [1] Gary H Lyman et al. American Society of Clinical Oncology guideline recommendations for sentinel lymph node biopsy in early-stage breast cancer
- [2] Saint-paul-de-vence. Recommandation pour la pratique clinique cancer du sein ; 2005 ; p.342-79.
- [3] Gill G, et al. Sentinel-lymph-node-based management or routine axillary clearance? One-year outcomes of sentinel node biopsy versus axillary clearance (SNAC): a randomized controlled surgical trial. *Ann Surg Oncol* 2009;16:266–75.
- [4] Barranger E, Classe JM, Clough KB, Giard S, Houvenaeghel G, Nos C. Veille bibliographique et recommandation. *Chirurgie du sein et axillaire. RPC NiceSaint-Paul de Vence* 2011. *Oncologie* 2011;13:727–54

- [5] Krag DN, et al. Surgical resection and radiolocalization of the sentinel lymph node in breast cancer using a gamma probe. *Surg Oncol* 1993;2(6):335-9 [discussion 340]
- [6] Kim T, Giuliano AE, Lyman GH. Lymphatic mapping and sentinel lymph node biopsy in early-stage breast carcinoma: a metaanalysis. *Cancer* 2006;106(1):4-16.
- [7] Sugie T, et al. A novel method for sentinel lymph node biopsy by indocyanine green fluorescence technique in breast cancer *Cancers (Basel)* 2010;2(2):713—20
- [8] Yamamoto S, et al. Intraoperative detection of sentinel lymph nodes in breast cancer patients using ultrasonography-guided direct indocyanine green dye-marking by real-time virtual sonography constructed with three-dimensional computed tomography-lymphography. *Breast* 2013;22(5):933—7.
- [9] White KP, Sinagra D, Dip F, Rosenthal RJ, Mueller EA, Lo Menzo E, Rancati A. Indocyanine green fluorescence versus blue dye, technetium-99M, and the dual-marker combination of technetium-99M p blue dye for sentinel lymph node detection in early breast cancer—meta-analysis including consistency analysis. *Surgery*. 2024 Jan 1;175:963-73.
- [10] Goonawardena J, Yong C, Law M. Use of indocyanine green fluorescence compared to radioisotope for sentinel lymph node biopsy in early-stage breast cancer: systematic review and meta-analysis. *Am J Surg*. 2020;220:665e676.
- [11] Ballardini B, Santoro L, Sangalli C, et al. The indocyanine green method is equivalent to the 99mTc-labeled radiotracer method for identifying the sentinel node in breast cancer: a concordance and validation study. *Eur J Surg Oncol* 2013;39(12): 1332—6.
- [12] Samorani D, Fogacci T, Panzini I, et al. The use of indocyanine green to detect sentinel nodes in breast cancer: a prospective study. *Eur J Surg Oncol* 2015;41(1):64—70.
- [13] Y. Guenane \*, M. Gorj, V. Nguyen, et al. Évaluation du vert d'Indocyanine versus Technétium dans la détection du ganglion sentinelle dans le cancer du sein. *Annales de Chirurgie Plastique Esthétique*. Volume 61, Issue 6, December 2016, Pages 806-810
- [14] Francesco Giammarile MD, PhD, Sergi Vidal-Sicart MD, et al. Sentinel Lymph Node Methods in Breast Cancer. *Seminars in Nuclear Medicine*. Volume 52, Issue 5, September 2022, Pages 551-560.