

A Rare Tumorous Presentation of Endobronchial Tuberculosis: Clinical Insights and Case Analysis

Abstract:

Endobronchial tuberculosis (EBTB) is a rare manifestation of pulmonary tuberculosis characterized by bronchial inflammation, often presenting with tumor-like masses in the airways. Misdiagnosis, particularly as lung cancer or bronchial asthma, is common due to its atypical presentation. We present a case of a 38-year-old female with persistent cough, wheezing, and constitutional symptoms, initially misdiagnosed with community-acquired pneumonia. Despite broad-spectrum antibiotics, there was no improvement. Imaging revealed right upper lobe collapse and a suspicious lesion, prompting a PET-CT scan that indicated a neoplastic or infectious etiology. Bronchoscopy confirmed a friable growth in the right main bronchus, with subsequent biopsy and bronchoalveolar lavage revealing *Mycobacterium tuberculosis*. Prompt initiation of anti-tuberculosis therapy led to symptom resolution. This case underscores the importance of considering tuberculosis in patients with persistent respiratory symptoms, even without prior TB history.

Keywords: Endobronchial tuberculosis, tumorous variant, bronchoscopy, anti-tuberculosis therapy

INTRODUCTION

Endobronchial tuberculosis (EBTB) is a manifestation of pulmonary tuberculosis involving bronchial inflammation. A rare and serious condition, EBTB often presents a distinctive clinical challenge, particularly with its tumorous variant. This variant is characterized by tumor-like masses in the bronchial airways, an infrequent and atypical presentation that complicates diagnosis. The unique tumorous features of EBTB often lead to misdiagnosis, frequently being mistaken for lung cancer (1)(2) or bronchial asthma (3)(4, 20-21). Delays in diagnosing EBTB can result in airway stenosis and other serious complications. Patients with EBTB typically require therapeutic bronchoscopy to address these issues and reverse the consequences (5)(6)(7).

CASE PRESENTATION

A 38-year-old female presented with a persistent cough and occasional wheezing, which she had been experiencing for the past four months. These symptoms were associated with fatigue and anorexia. Her medical history revealed no previous respiratory conditions. On examination, general physical examination was normal. Respiratory system examination revealed decreased air entry was noted in the right infraclavicular area of her chest, accompanied by a monophonic wheeze. The chest X-ray revealed a heterogeneous opacity in the right upper zone. The patient was initially diagnosed with community-acquired pneumonia and treated with broad-spectrum antibiotics outside the hospital, but there was no improvement in their condition. Routine laboratory investigations were within normal limits. Sputum for AFB was negative.

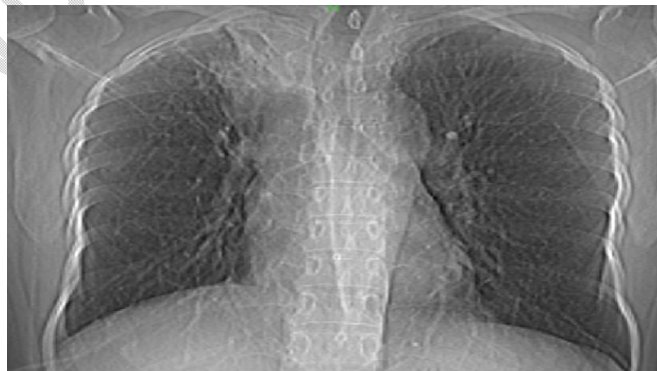


Figure 1- chest X-ray showing a heterogeneous opacity in the right upper zone.

A CECT scan of the chest showed a collapse of the anterior and apical segments of the right upper lobe, sparing the posterior segment. There was a cut-off of the right upper lobar bronchus, with mildly enlarged right hilar and paratracheal lymph nodes. An ill-defined lesion with heterogeneous enhancement was noted at the right hilum around the upper lobe bronchus, measuring approximately 2.2 x 2 x 1.2 cm. The remaining lung fields appeared normal with no parenchymal lesions. These findings suggested a neoplastic or infectious etiology (Figure 2).

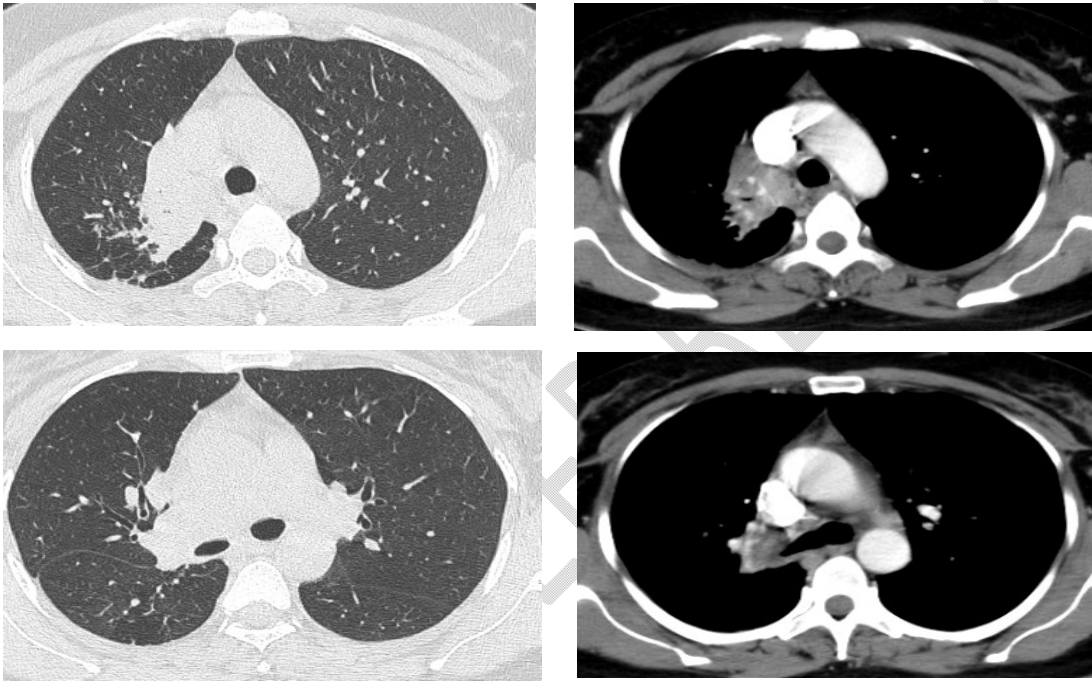


Figure 2- CECT scan of the chest shows right upper lobe collapse, bronchus obstruction, mildly enlarged lymph nodes, heterogeneous lesion at right hilum (2.2 x 2 x 1.2 cm). No other lung abnormalities. Likely neoplastic or infectious.

Due to suspicion of bronchogenic carcinoma, a PET-CT scan was performed. PET-CT scan revealed an FDG-avid, heterogeneously enhancing, consolidation-like lesion in the suprahilar region of the right upper lobe, causing a cut-off of the right upper lobar bronchus and containing necrotic areas and cavitations. Mildly enlarged, mildly FDG-avid right hilar and right paratracheal nodes were also seen. The remaining lung fields appeared normal with no parenchymal lesions. These findings continued to suggest a neoplastic or infectious etiology (figure 3).

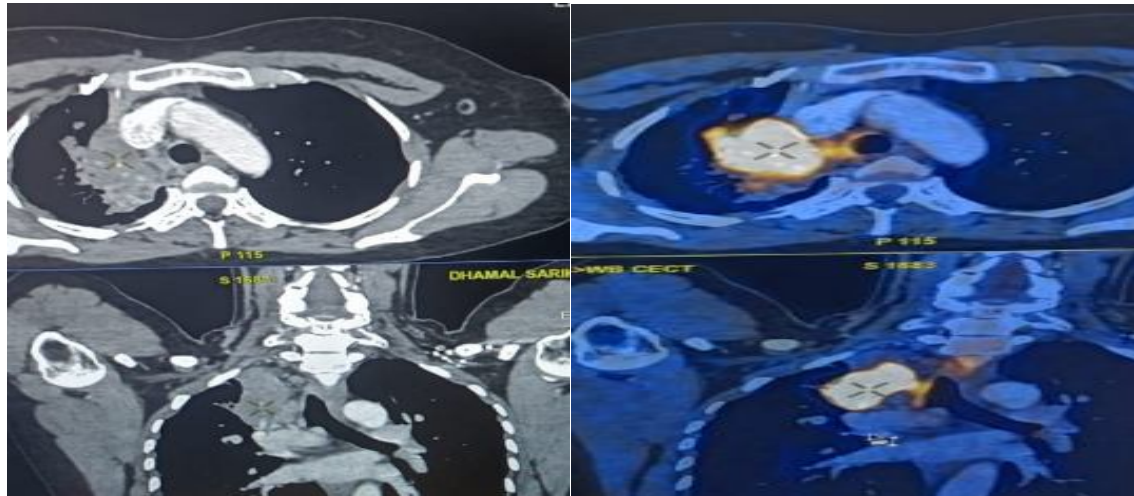


Figure 3- PET-CT scan showing FDG avid lesion in right upper lobe causing bronchus obstruction, with necrotic areas and cavitations. Mildly enlarged right hilar and paratracheal nodes. No other lung abnormalities. Likely neoplastic or infectious.

To obtain a definitive diagnosis, a bronchoscopy was performed, revealing a thick, white, friable growth in the right main bronchus and narrowing of the right upper lobe bronchus. All other bronchial segments appeared normal. Bronchoalveolar lavage (BAL) was conducted, and a biopsy was obtained from the lesion site for histopathological examination (HPE) (figure 4).

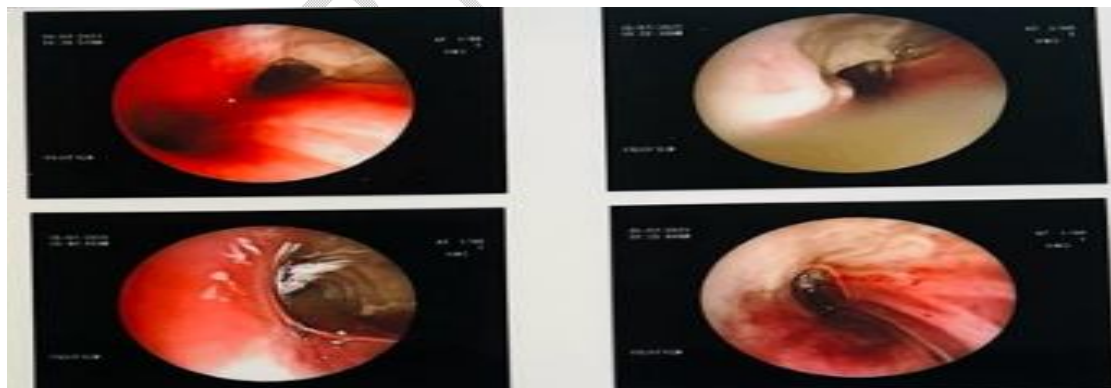


Figure 4- Bronchoscopy shows a thick, friable growth in right main bronchus with narrowing of right upper lobe bronchus. BAL and biopsy sent for HPE.

Histopathological examination of the endobronchial mass revealed a granuloma with multinucleated giant cells and central caseous necrosis. An acid-fast stain demonstrated thin, rod-like mycobacteria.

Additionally, The bronchoalveolar lavage sample showed positive results for acid-fast bacilli (AFB), and nucleic acid amplification using GeneXpert detected a low positive signal for Mycobacterium tuberculosis with no rifampicin resistance observed. Additionally, culture on Löwenstein-Jensen medium confirmed the presence of the Mycobacterium tuberculosis complex. This combination of findings led to the diagnosis of endobronchial tuberculosis (EBTB), specifically the tumorous variant, which mimicked a neoplastic process due to its presentation and radiological findings.

Given the diagnosis, a tailored treatment regimen was initiated, consisting of a full course of antitubercular therapy and adjunctive corticosteroids to address the inflammatory component of the disease. The patient was closely monitored for response to treatment, and her symptoms gradually improved.

This case underscores the importance of comprehensive diagnostic workup in patients with persistent respiratory symptoms, as well as the need for considering tuberculosis in the differential diagnosis, even in the absence of a prior history of TB or other significant risk factors.

DISCUSSION

The incidence of endobronchial tuberculosis (EBTB) is reported to be between 5.8% and 30% of all cases of Mycobacterium tuberculosis (MTB) (8) . Children appear to be at a higher risk of developing EBTB compared to adults (9). It is suspected that EBTB remains underdiagnosed because fiberoptic bronchoscopy (FB) is not routinely performed on all patients with tuberculosis (10) . Morrone and Abe reported an EBTB incidence as high as 91% in patients with sputum stains positive for acid-fast bacilli (AFB)(11) . In some instances, patients with an endobronchial mass may exhibit localized wheezing or rhonchi, which can be mistaken for bronchial asthma (12)(13).

In approximately 10% to 20% of patients with endobronchial tuberculosis (EBTB), chest radiographs may show no abnormalities (10).

Contrast-enhanced computed tomography (CECT) is recognized as superior to conventional chest radiography. It aids in localizing disease and assessing parenchymal and lymph node involvement. Multiple studies have demonstrated that chest CT has a sensitivity of over 95% in detecting endobronchial tuberculosis (EBTB) (14).

Bronchoscopy and biopsy are essential for diagnosing EBTB, with biopsy yields for diagnosing the condition ranging from 30% to 84% (15).

Histopathological findings are crucial for early diagnosis and initiating prompt treatment (16). However, in our case, diagnosis was confirmed through culture and nucleic acid amplification of bronchoalveolar lavage. Pulmonary function tests (PFT) typically reveal a restrictive lung disease pattern in individuals with EBTB. PFT was not conducted in our patient (5)(15).

Common complications of EBTB include bronchial stenosis and the formation of strictures. Stenosis in larger airways can potentially lead to respiratory compromise, with postobstructive bronchiectasis being a possible sequelae of note (15).

Treatment for EBTB follows the same regimen as pulmonary tuberculosis (15). It includes a fixed-dose combination of four primary drugs: isoniazid, rifampicin, ethambutol, and pyrazinamide for an initial two months, followed by a continuation phase of isoniazid and rifampicin daily for an additional four months. Although corticosteroids have been reported to have beneficial anti-inflammatory effects, they were not administered to our patient. In cases of drug resistance, treatment should be tailored based on susceptibility testing results.

Chung and Lee classified EBTB into seven subtypes: actively caseating, edematous-hyperemic, fibrostenotic, tumorous, granular, ulcerative, and nonspecific bronchitis. All subtypes of EBTB can transform into one another, and the likelihood of healing without sequelae depends on the disease extent and the formation of granular tissue(10) .

Bronchoscopy findings often provide clues to the diagnosis of endobronchial tuberculosis (EBTB); however, it can still be mistaken for lung cancer, especially if

typical granulation tissue is absent (2). In endemic areas, it is essential to rule out EBTB in all cases of endobronchial lesions suspicious for bronchogenic carcinoma. Neither symptoms nor bronchial appearance alone can confirm EBTB, necessitating both tissue and bacteriologic diagnoses(17). The endoscopic appearance of granuloma formation or localized bronchitis can resemble that of a necrotic neoplasm(18).

EBTB rarely resolves without sequelae, with airway stenosis being a common outcome, even in patients with nonspecific bronchitis, leading to severe and symptomatic obstruction(8). While chemotherapy can sometimes yield a favorable response in the early post-treatment period, it does not always prevent the development of airway stenosis (2). Aggressive interventional therapy, such as bronchoplasty or stent placement, can alleviate airway stenosis and improve patient outcomes(19).

CONCLUSION

Endobronchial tuberculosis predominantly affects young females, as observed in our patient. It often goes undiagnosed because AFB smears are negative and diagnostic bronchoscopy is not routinely performed, particularly in developing countries. However, anti-tuberculosis therapy remains the primary treatment choice. Interventional procedures such as bronchoscopic interventions with laser, argon therapy, or stent placement to alleviate scarring and stenosis are viable options, with surgery reserved as a last resort for refractory cases. Clinicians should maintain a high index of suspicion in patients who are AFB smear-negative but present with symptoms and localized wheezing, and consider bronchoscopy in selected cases.

The tumorous variant of EBTB presents additional diagnostic challenges; however, early detection through bronchoscopy and timely treatment with anti-tuberculosis drugs can improve prognosis and prevent complications such as bronchial stenosis.

Disclaimer

Author(s) hereby declare that NO generative AI technologies such as Large Language Models (ChatGPT, COPILOT, etc) and text-to-image generators have been used during writing or editing of manuscripts.

REFERENCES :

1. Kreisel D, Arora N, Weisenberg SA, et al. Tuberculosis presenting as an endobronchial mass. *J Thorac Cardiovasc Surg.* 2007;133:582–584.
2. Van den Brande P, Lambrechts M, Tak G, et al. Endobronchial tuberculosis mimicking lung cancer in elderly patients. *Respir Med.* 1991;85:107–109.
3. Park CS, Him KU, Lee SM, et al. Bronchial hypereactivity in patients with endobronchial tuberculosis. *Respir Med.* 1995;89:419–422.
4. Willians DJ, York EL, Norbert EJ, et al. Endobronchial tuberculosis presenting as asthma. *Chest.* 1988;93:836–838.
5. Lee JH, Chung HS. Bronchoscopic, radiologic and pulmonary function evaluation of endobronchial tuberculosis. *Respirology.* 2000;5:411–417.
6. Mariotta S, Guidi L, Aquilini M, et al. Airway stenosis after tracheo-bronchial tuberculosis. *Respir Med.* 1997;91:107–110.
7. Albert RK, Petty TL. Endobronchial tuberculosis progressing to bronchial stenosis. Fiberopticbronchoscopic manifestations. *Chest.* 1976;70:537–539.
8. Miguel Campos E, Puzo Ardanuy C, Burgue's Mauri C, et al. Tuberculosis bronquial. Estudio de 73 casos. *Arch Bronconeumol.* 2008;44:282–284.
9. Bibi H, Mosheyev A, Shoseyov D, et al. Should bronchoscopy be performed in the evaluation of suspected pediatric pulmonary tuberculosis? *Chest.* 2002;122:1604–1608.
10. Chung HS, Lee JH. Bronchoscopic assessment of the evolution of endobronchial tuberculosis. *Chest.* 2000;117:385–392.
11. Morrone N, Abe NS. Bronchoscopic findings in patients with pulmonary tuberculosis. *J Bronchol.* 2007;14:15–18.
12. Aneja A, Krishnaswamy U, Thyagaraj V, Moideen R, Padmaja M. Endobronchial tuberculosis: two case reports and review of literature. *Case Rep Pulmonol.* 2014;2014:283972.
13. Park MJ, Woo IS, Son JW, et al. Endobronchial tuberculosis with expectoration of tracheal cartilages. *Eur Respir J.* 2000;15:800–802.

14. Im JG, Itoh H, Shim YS, Lee JH, Ahn J, Han MC, Noma S. Pulmonary tuberculosis: CT findings--early active disease and sequential change with antituberculous therapy. *Radiology*. 1993;186:653–660.
15. Kashyap S, Solanki A. Challenges in endobronchial tuberculosis: from diagnosis to management. *Pulm Med*. 2014;2014:594806.
16. Ozkaya S, Bilgin S, Findik S, Kok HC, Yuksel C, Atici AG. Endobronchial tuberculosis: histopathological subsets and microbiological results. *Multidiscip Respir Med*. 2012;7:34.
17. Hoheisel G, Chan BK, Chan CH, et al. Endobronchial tuberculosis: diagnostic features and therapeutic outcome. *Respir Med*. 1994;88:593–597.
18. Matthews JI, Matarese SL, Carperter JL. Endobronchial tuberculosis simulating lung cancer. *Chest*. 1984;86:642–644.
19. Low SY, Hsu A, Eng P. Interventional bronchoscopy for tuberculous tracheobronchial stenosis. *Eur Respir J*. 2004;24:345–347.
20. Barnes D, Gutiérrez Chacoff J, Benegas M, Perea RJ, de Caralt TM, Ramirez J, Vollmer I, Sanchez M. Central airway pathology: clinic features, CT findings with pathologic and virtual endoscopy correlation. *Insights into imaging*. 2017 Apr;8:255-70.
21. Ju WT, Fu Y, Liu Y, Tan YR, Dong MJ, Wang LZ, Li J, Zhong LP. Clinical and pathologic analyses of tuberculosis in the oral cavity: report of 11 cases. *Oral surgery, oral medicine, oral pathology and oral radiology*. 2018 Jan 1;125(1):44-51.

DECLARATION

Ethical Approval:

As per international standards or university standards written ethical approval has been collected and preserved by the author(s).

CONSENT

As per international standards or university standards, patient(s) written consent has been collected and preserved by the author(s).

DATA AND MATERIAL AVAILABILITY

The data and material for the case study has been obtained from hospital records.

UNDER PEER REVIEW