

Case report

"A Rare Tumorous Presentation of Endobronchial Tuberculosis: Clinical Insights and Case Analysis"

ABSTRACT

Background and Objectives:

The tumorous variant of endobronchial tuberculosis (TB) is a rare manifestation that often presents with unusual symptoms, posing challenges for diagnosis. This study aims to contribute to medical literature by presenting a detailed case study of this variant, highlighting the diagnostic methods used and subsequent management strategies.

Case Study:

A patient with a persistent dry cough was extensively evaluated, including radiological imaging showing signs of right upper lobe collapse and an unclear hilum lesion. To confirm the diagnosis, a bronchoscopy was performed, and biopsy samples were taken for histopathological analysis and molecular testing. Careful examination of clinical, radiological, and laboratory data was conducted for accurate diagnosis.

Results:

Histopathological analysis of the biopsy specimens revealed granulomatous lesions, suggesting a tubercular origin and ruling out malignancy. Positive results from the BAL gene Xpert test further confirmed the presence of *Mycobacterium tuberculosis* and its susceptibility to rifampicin. This led to the final diagnosis of the tumorous variant of endobronchial TB. A personalized treatment plan involving antitubercular drugs and steroids was promptly administered.

Discussion:

This case emphasizes the importance of considering rare TB variants in the diagnosis

of patients with nonspecific respiratory symptoms. The combination of various diagnostic tools, including bronchoscopy, histopathology, and molecular testing, played a crucial role in achieving an accurate diagnosis and tailoring appropriate management. Timely intervention is vital for favorable outcomes in distinct tuberculosis presentations.

Conclusion:

The presented case study highlights the significance of being vigilant about rare TB variants when dealing with patients who have nonspecific respiratory symptoms. Utilizing a range of diagnostic techniques is essential for precise diagnosis and effective management. Initiating appropriate treatment in a timely manner is crucial for positive outcomes in unique tuberculosis cases.

Keywords: endobronchial tuberculosis, tumorous variant, granulomatous lesion, bronchoscopy.

INTRODUCTION

Endobronchial tuberculosis (EBTB) is a manifestation of pulmonary tuberculosis involving bronchial inflammation. A rare and serious condition, EBTB often presents a distinctive clinical challenge, particularly with its tumorous variant. This variant is characterized by tumor-like masses in the bronchial airways, an infrequent and atypical presentation that complicates diagnosis. The unique tumorous features of EBTB often lead to misdiagnosis, frequently being mistaken for lung cancer (1)(2)(3) or bronchial asthma (4)(5). Due to the decreasing incidence of tuberculosis and the atypical nature of EBTB, it is often underdiagnosed. Delays in diagnosing EBTB can result in airway stenosis and other serious complications. Patients with EBTB typically require therapeutic bronchoscopy to address these issues and reverse the consequences (6)(7)(8)(9).

CASE PRESENTATION

A 38-year-old female presented with a persistent cough and occasional wheezing, which she had been experiencing for the past four months. Her medical history revealed no previous respiratory conditions. On physical examination, decreased air entry was noted on the right side of her chest, accompanied by a monophonic wheeze. Initial investigations included a high-resolution CT (HRCT) of the thorax, which showed a consolidation-like lesion in the suprahilar region of the right upper lobe (RUL). This lesion was causing a cut-off of the right upper lobar bronchus, with mildly enlarged right hilar and paratracheal lymph nodes.

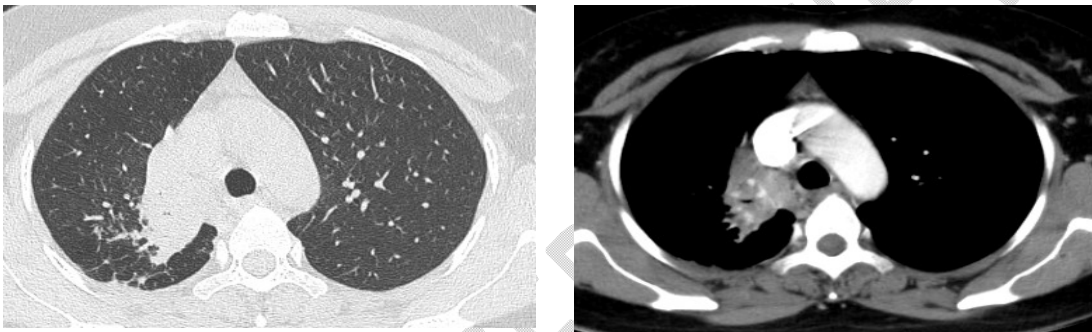


Figure 1- consolidation-like lesion in the suprahilar region of the right upper lobe

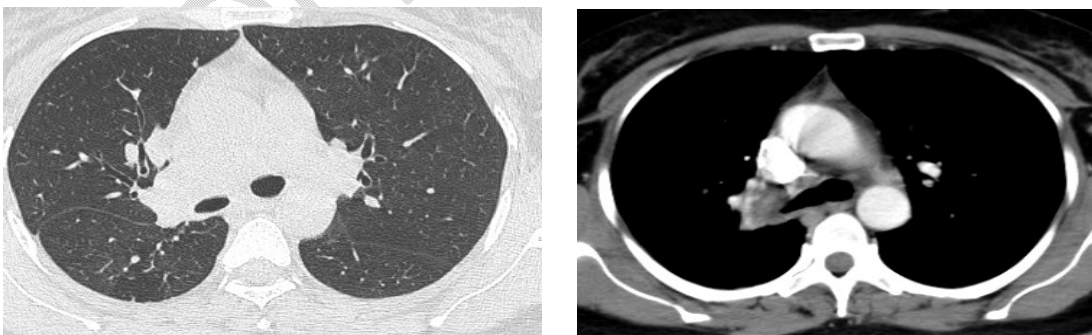


Figure 2- cut-off of the right upper lobar bronchus, with mildly enlarged right hilar and paratracheal lymph nodes

Further diagnostic evaluation with a PET-CT scan revealed increased uptake in the consolidation-like lesion, raising the possibility of an infectious or neoplastic pathology. To obtain a definitive diagnosis, a bronchoscopy was performed, which identified a thick, white, friable growth in the right main bronchus. The bronchoscope was unable to pass through the RUL bronchus, necessitating a biopsy and bronchoalveolar lavage (BAL) for further analysis.

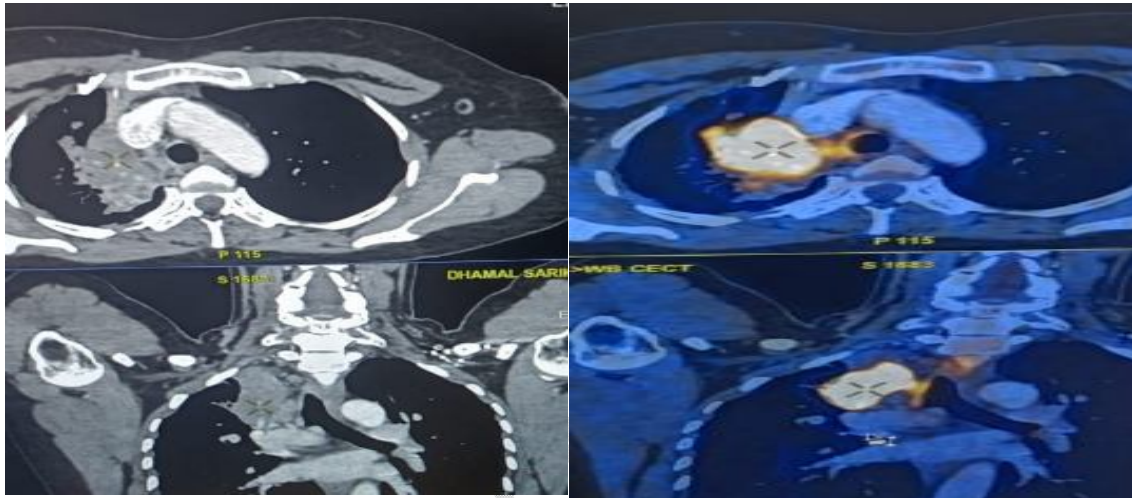


Figure 3- increased uptake in the consolidation-like lesion.

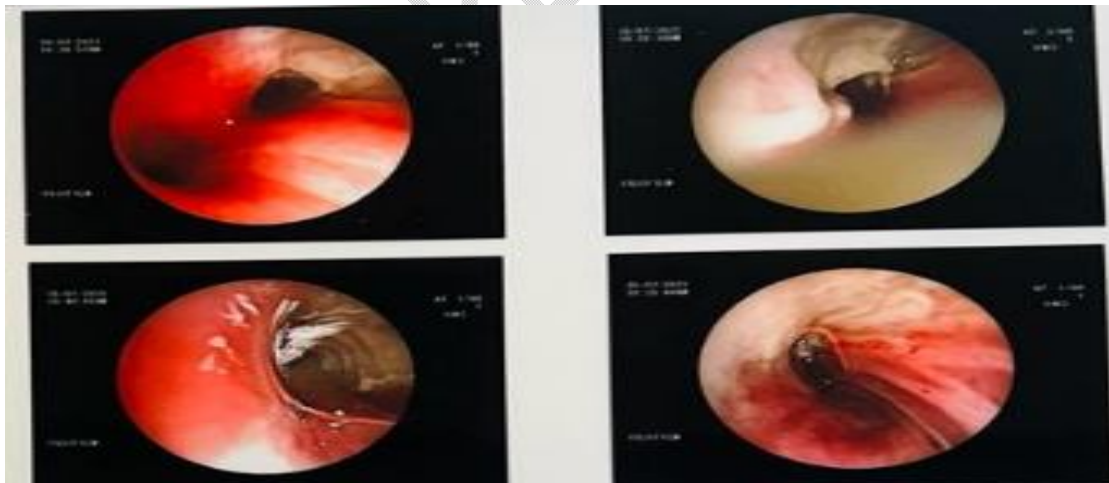


Figure 4- A thick, white, friable growth in the right main bronchus.

Histopathological examination of the biopsy samples indicated granulomatous inflammation, and acid-fast bacilli (AFB) testing was positive. Additionally, the BAL sample underwent GeneXpert testing, which confirmed the presence of

Mycobacterium tuberculosis and indicated that the strain was sensitive to rifampicin. This combination of findings led to the diagnosis of endobronchial tuberculosis (EBTB), specifically the tumorous variant, which mimicked a neoplastic process due to its presentation and radiological findings.

Given the diagnosis, a tailored treatment regimen was initiated, consisting of a full course of antitubercular therapy and adjunctive corticosteroids to address the inflammatory component of the disease. The patient was closely monitored for response to treatment, and her symptoms gradually improved. This case underscores the importance of comprehensive diagnostic workup in patients with persistent respiratory symptoms, as well as the need for considering tuberculosis in the differential diagnosis, even in the absence of a prior history of TB or other significant risk factors.

DISCUSSION

The incidence of endobronchial tuberculosis (EBTB) is reported to be between 5.8% and 30% of all cases of Mycobacterium tuberculosis (MTB) (10) . Children appear to be at a higher risk of developing EBTB compared to adults (11). It is suspected that EBTB remains underdiagnosed because fiberoptic bronchoscopy (FB) is not routinely performed on all patients with tuberculosis (12) . Morrone and Abe reported an EBTB incidence as high as 91% in patients with sputum stains positive for acid-fast bacilli (AFB)(13) . All patients in their study underwent FB, which is not a common practice, contributing to the condition being underrecognized, underdiagnosed, and underreported.

Although many patients with AFB-positive sputum may have EBTB, not all EBTB patients exhibit AFB-positive sputum. This discrepancy may be because MTB is not initially suspected, or airway narrowing makes expectoration of the organism difficult . Additionally, EBTB might be more frequent among females, who may cough or expectorate less due to cultural reasons (2)(7)(12) . In both of our cases, AFB stains on the sputum were negative, necessitating bronchoscopy for diagnosis. At the initial presentation, MTB was not suspected in our patients.

There is limited data on the clinical manifestation of endobronchial tuberculosis (EBTB). The most common symptom is a barking cough, which is nonspecific, as are chest pain, blood-streaked sputum, generalized weakness, dyspnea, and fever. Localized wheeze or rhonchi may also be present, potentially leading to misdiagnosis as bronchial asthma or an endobronchial mass (1)(3)(4)(5)(7). Interestingly, Park et al. described coughing up bronchial cartilage as a specific feature of EBTB (14).

The pathology of EBTB is not fully understood, but potential sources include direct implantation of bacilli into the bronchial wall from an adjacent parenchymal lesion, direct airway infiltration from an adjacent tuberculous mediastinal lymph node, erosion or protrusion of an intrathoracic tuberculous lymph node into the bronchus, hematogenous spread, and possible extension from a peribronchial lesion via lymphatic drainage (1). In one of our cases, an intrathoracic lymph node appeared to have eroded into the airway.

Studies indicate that the posterior segment of the upper lobes is the most common site for EBTB (7), although other bronchial locations have been reported (10). Middle and lower lobes are also frequently involved, supporting the implantation theory for EBTB due to gravity. Delays in diagnosing EBTB are partly due to the lack of radiographic findings on standard chest X-rays (7). Diagnosis primarily relies on fiberoptic bronchoscopy (FB). Chung and Lee (12) classified EBTB into seven subtypes: actively caseating, edematous-hyperemic, fibrostenotic, tumorous, granular, ulcerative, and nonspecific bronchitis. All subtypes of EBTB can transform into one another, and the likelihood of healing without sequelae depends on the disease extent and the formation of granular tissue.

Bronchoscopy findings often provide clues to the diagnosis of endobronchial tuberculosis (EBTB); however, it can still be mistaken for lung cancer, especially if typical granulation tissue is absent (2). In endemic areas, it is essential to rule out EBTB in all cases of endobronchial lesions suspicious for bronchogenic carcinoma. Neither symptoms nor bronchial appearance alone can confirm EBTB, necessitating both tissue and bacteriologic diagnoses(15). The endoscopic appearance of granuloma formation or localized bronchitis can resemble that of a necrotic neoplasm(16).

EBTB rarely resolves without sequelae, with airway stenosis being a common outcome, even in patients with nonspecific bronchitis, leading to severe and symptomatic obstruction(8)(16). While chemotherapy can sometimes yield a favorable response in the early post-treatment period, it does not always prevent the development of airway stenosis (2)(9)(12)(17). Oral steroids have not been effective in preventing tracheal stenosis(18)(19). Aggressive interventional therapy, such as bronchoplasty or stent placement, can alleviate airway stenosis and improve patient outcomes(8)(20).

CONCLUSION

Endobronchial tuberculosis (EBTB) is suspected to be underrecognized and underreported. The primary diagnostic tool remains fiberoptic bronchoscopy (FB), especially when the condition is suspected, and the acid-fast bacilli (AFB) smear is negative. Although antituberculous therapy is effective, airway stenosis often results despite the use of steroids. Therapeutic bronchoscopy, including bronchoplasty or stent placement, can help alleviate this stenosis. The tumorous variant of EBTB presents additional diagnostic challenges; however, early detection through bronchoscopy and timely treatment with anti-tuberculosis drugs can improve prognosis and prevent complications such as bronchial stenosis..

DECLARATION

1) ETHICS APPROVAL AND CONSENT OF PARTICIPATION

Ethical committee approval is not taken as it is a case study which is an observational study.

2) CONSENT FOR PARTICIPATION

Consent was taken from the patient

3) DATA AND MATERIAL AVAILABILITY

The data and material for the case study has been obtained from hospital records.

REFERENCES :

1. Kreisel D, Arora N, Weisenberg SA, et al. Tuberculosis presenting as an endobronchial mass. *J Thorac Cardiovasc Surg.* 2007;133:582–584.
2. Ip MSM, So SY, Lam WK, et al. Endobronchial tuberculosis revisited. *Chest.* 1986;89:727–730.
3. Van den Brande P, Lambrechts M, Tak G, et al. Endobronchial tuberculosis mimicking lung cancer in elderly patients. *Respir Med.* 1991;85:107–109.
4. Park CS, Him KU, Lee SM, et al. Bronchial hypereactivity in patients with endobronchial tuberculosis. *Respir Med.* 1995;89:419–422.
5. Willians DJ, York EL, Norbert EJ, et al. Endobronchial tuberculosis presenting as asthma. *Chest.* 1988;93: 836–838.
6. Lee JH, Chung HS. Bronchoscopic, radiologic and pulmonary function evaluation of endobronchial tuberculosis. *Respirology.* 2000;5:411–417.
7. Lee JH, Park SS, Lee DH, et al. Endobronchial tuberculosis. Clinical and bronchoscopic features in 121 cases. *Chest.* 1992;102:990–994.
8. Mariotta S, Guidi L, Aquilini M, et al. Airway stenosis after tracheo-bronchial tuberculosis. *Respir Med.* 1997; 91:107–110.
9. Albert RK, Petty TL. Endobronchial tuberculosis progressing to bronchial stenosis. Fiberopticbronchoscopic manifestations. *Chest.* 1976;70:537–539.
10. Miguel Campos E, Puzo Ardanuy C, Burgue's Mauri C, et al. Tuberculosis bronquial. Estudio de 73 casos. *Arch Bronconeumol.* 2008;44:282–284.
11. Bibi H, Mosheyev A, Shoseyov D, et al. Should bronchoscopy be performed in the evaluation of suspected pediatric pulmonary tuberculosis? *Chest.* 2002;122:1604–1608.

12. Chung HS, Lee JH. Bronchoscopic assessment of the evolution of endobronchial tuberculosis. *Chest*. 2000; 117:385–392.
13. Morrone N, Abe NS. Bronchoscopic findings in patients with pulmonary tuberculosis. *J Bronchol*. 2007; 14:15–18.
14. Park MJ, Woo IS, Son JW, et al. Endobronchial tuberculosis with expectoration of tracheal cartilages. *Eur Respir J*. 2000;15:800–802.
15. Hoheisel G, Chan BK, Chan CH, et al. Endobronchial tuberculosis: diagnostic features and therapeutic outcome. *Respir Med*. 1994;88:593–597.
16. Matthews JI, Matarese SL, Carperter JL. Endobronchial tuberculosis simulating lung cancer. *Chest*. 1984; 86:642–644.
17. Kim YH, Kim HT, Lee KS, et al. Serial fiberopticbronchoscopic observations of endobronchial tuberculosis before and early after antituberculosis chemotherapy. *Chest*. 1993;1003:673–677.
18. Nemir RL, Cardona J, Vaziri F, et al. Prednisone as an adjunct in the chemotherapy of lymph node-bronchial tuberculosis in childhood, a double blind study. *Am Rev Respir Dis*. 1963;88:189–198.
19. Tagarro A, Barrio MI, Marti´nez C, et al. Fibrobroncoscopia en la tuberculosis endobronquial. *An Pediatr (Barc)*. 2004;61:314–319.
20. Low SY, Hsu A, Eng P. Interventional bronchoscopy for tuberculous tracheobronchial stenosis. *Eur Respir J*. 2004;24:345–347.