

Case report

PNEUMOSINUS DILATANS OF THE FRONTAL AND ETHMOID SINUSES PRESENTING WITH EXOPHTHALMOS: A CASE REPORT

ABSTRACT

Aims : Pneumosinus Dilatans (PSD) is a rare condition characterized by an enlargement of the paranasal sinuses.

Presentation of Case : We report a case of a 21-year-old male patient coming for a swelling of the frontal region and exophthalmos. The CT scan shows a pneumosinus dilatans of the frontal and ethmoid sinuses with an exophthalmos with chronic rhinosinusitis with polyps and had an endoscopic sinus surgery. The follow-up shows a regression of the swelling and persistent mild exophthalmos after a few months.

Discussion : Pneumosinus Dilatans is a rare condition and its clinical presentation varies from asymptomatic patients to rhinologists with ocular symptoms. The aetiology and mechanism remain unclear and could be associated with other conditions. CT scan shows an enlarged sinus and may assess any other associated disorders. The treatment vary from non-surgical to surgical treatment which could be the endoscopic or external approach.

Conclusion : Several theories on the etiology of PSD exist but its true etiology remains unclear. Because of the clinical heterogeneity, which varies from an asymptomatic to a condition with rhinological, ocular and neurological symptoms, the treatment depends on the clinical manifestations.

Keywords: Pneumosinus dilatans, exophthalmos, frontal sinus, ethmoid sinus, case report (Arial, inclined, 10 font, justified)

1. INTRODUCTION

Pneumosinus dilatans (PSD) is a rare and benign pathology of the paranasal sinuses. The first case was first described in 1898 by Meyes as an enlargement of the paranasal sinuses but the term "pneumosinus dilatans" was given by Benjamin two decades later. Because of its variable presentation, from asymptomatic patients or only presenting some cosmetic concerns, the diagnosis is likely underestimate [1,2]. We report a case of pneumosinus dilatans involving the frontal and ethmoid sinuses with an exophthalmos.

2. PRESENTATION OF CASE

We report the case of a 21-year-old male patient who presented to our department for progressive exophthalmos of the left eye developing over a one-year period. He had been diagnosed with chronic rhino-sinusitis with nasal polyps, for which he had surgery two years before his admittance in our department. He had also been following medical treatment, based on topical corticosteroids, ever since his diagnosis. No trauma or other personal or familial medical history was noted.

Aside from exophthalmos, the patient also complained of permanent nasal obstruction, anosmia, and recurrent headaches. There were no other symptoms, particularly no decrease in visual acuity, no epistaxis, and no signs of neurological impairment.

Physical examination found an exophthalmos of the left eye, along with swelling in the ipsilateral frontal region (Fig. 1A & B). Nasal endoscopy found polyps in both nasal cavities, coming from the middle meatus and reaching the middle turbinate in the right nasal fossa, and the inferior turbinate in the left one. There were no oculomotor disorders, and the visual acuity in both eyes was normal.

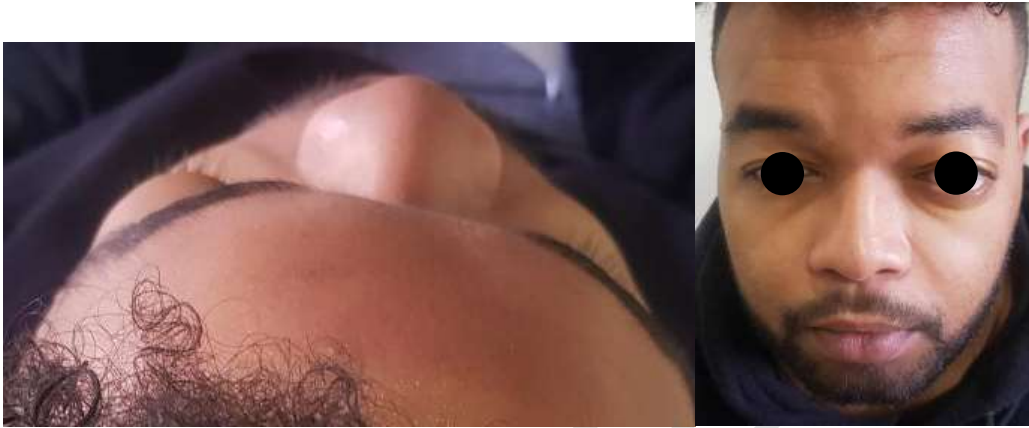


Fig.1A Picture from the top showing (left image) a swelling of the left forehead region with exophthalmos. 1B Photography taken from the front (right image) showing the exophthalmos.

Computed Tomography (CT) scanning of the nose and paranasal sinuses found enormous distension of the ethmoid cells, extending to the maxillary sinus, the left orbit and the left compartment of the frontal sinus, as well as ipsilateral frontal endocranial extension, with thinning of cortical margins evoking a pneumosinus dilatans of the frontal and ethmoid sinuses (Fig. 2 and 3). This sinus distension displaced surrounding tissues as the orbital content, on the medial oculomotor muscle and the ocular globe, causing a grade II exophthalmos. Moreover, there was a seemingly polypoid opacification of the ethmoid, maxillary and sphenoid sinuses, more marked in the left sinuses.

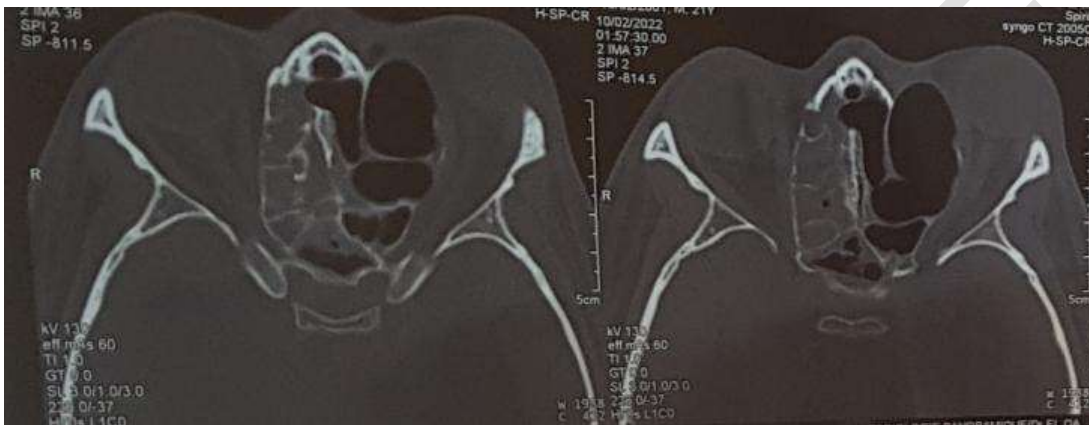
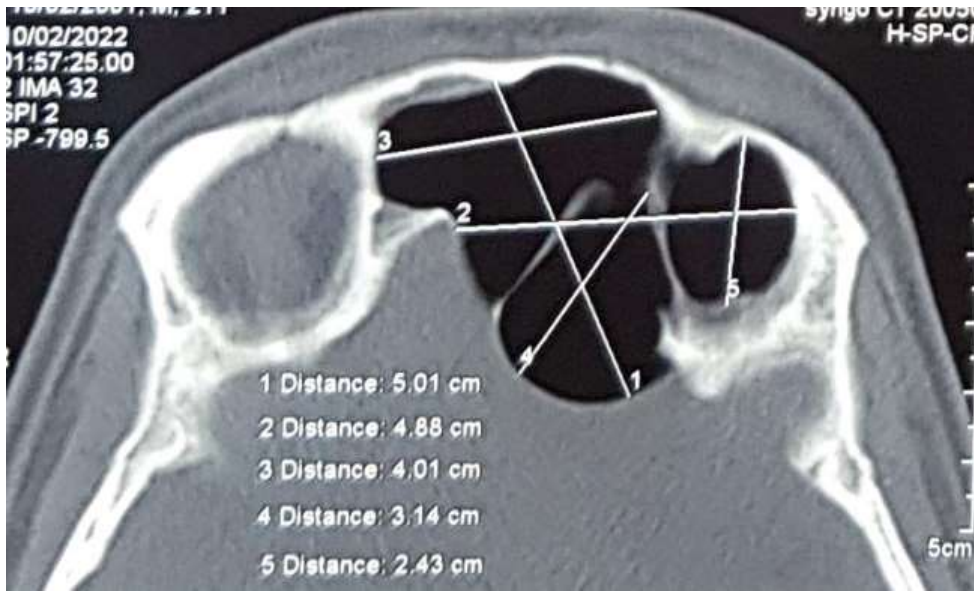


Fig.2 and 3 CT axial image revealing the enlargement of the frontal and ethmoid sinuses on the left side with exophthalmos.

The patient had an endoscopic sinus surgery with middle antrostomy, anterior and posterior ethmoidectomy and DRAF I with polypectomy. The surgery shows polyps reaching the level of the frontal ostium and the ethmoid sinus. The swollen frontal region regressed after few months with persistence of a mild exophthalmos. (Fig 4A & 4B)

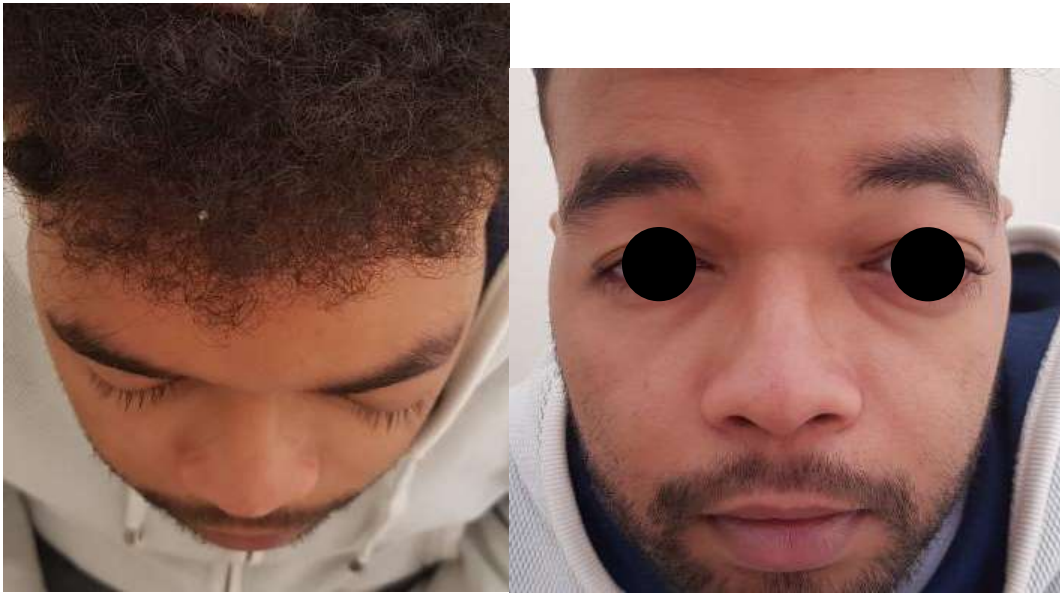

Fig.4A Post-operative picture from the top showing (left image) the regression of the swelling. 4B Post-operative picture taken from the front (right image) showing the mild persistent exophthalmos.

3. DISCUSSION

Pneumosinus dilatans, or PSD, also called pneumocele, is a rare condition and its pathogenesis remains unclear. It refers to an enlargement of paranasal sinuses containing air. PSD usually affects both sexes at any age but is more frequent in young men, in their twenties to forties [2]. Less than 200 articles have been documented in literature and the majority of patients were males [3]. The frontal sinus is the most commonly involved. The mechanism, aetiology and management of patients with PSD remains undefined, even the first case was described more than one century ago [4]. The presentation of this condition varies from asymptomatic patients to rhinological symptoms with nasal obstruction or visual disorders as progressive decreased vision or patients with cosmetics signs with swelling. PSD could be associated with other pathologies such as meningioma, arachnoid cyst or chronic rhinosinusitis or could be considered as isolated [2,5]. The clinical features depend on the sinus involved and the size of the enlarged sinus. According to frontal sinus, the most common presentation is a frontal "Cromagnon-like swelling" [3,5]. Maxillary PSD is also associated with cheek swelling, while ethmoid and sphenoid involvement have been linked with ocular symptoms, from blurred vision to loss of vision [6].

The most accepted theory involves a one-way valve mechanism with air-trapping in the sinus despite in-vivo demonstration because of an obstruction lesion such as a polyp or inflamed mucosa. This leads to increased pressure in the sinus and result in a bony deformity [3,6,7].

Computed tomography scan shows the enlarged sinus and helps to assess any associated conditions. MRI could be more useful for looking for intracranial lesion [5,8].

The treatment of patients with PSD varies from a no surgical intervention, as the majority only present aesthetics complaints, to a surgical treatment, which could be endoscopic sinus surgery or external bicoronal approach [1,9].

4. CONCLUSION

Pneumosinus dilatans is a rare condition and its evidence and etiology remain uncertain. Furthermore, an exophthalmos secondary to a PSD is even more uncommon. As PSD could remain asymptomatic, a systematic physical examination with neurological, nasal cavity and complete eye examination, with acuity testing is useful to look for any surrounding

tissues involvement. CT scan imaging and MRI help to make the diagnosis but also assess any associated condition, and eliminate differential diagnoses. A surgical intervention could be taken for deteriorating vision with orbital or intracranial involvement.

Ethical Approval:

As per international standards or university standards written ethical approval has been collected and preserved by the author(s).

Consent

As per international standards or university standards, patient(s) written consent has been collected and preserved by the author(s).

ABBREVIATIONS

PSD PneumoSinus Dilatans

Disclaimer (Artificial intelligence)

Option 1:

Author(s) hereby declare that NO generative AI technologies such as Large Language Models (ChatGPT, COPILOT, etc) and text-to-image generators have been used during writing or editing of manuscripts.

Option 2:

Author(s) hereby declare that generative AI technologies such as Large Language Models, etc have been used during writing or editing of manuscripts. This explanation will include the name, version, model, and source of the generative AI technology and as well as all input prompts provided to the generative AI technology

Details of the AI usage are given below:

- 1.
- 2.
- 3.

REFERENCES

1. Singh H, Ramakrishnan N, Sarin D. Pneumosinus Dilatans. Med J Armed Forces India. juill 2007;63(3):300- 1. [https://doi.org/10.1016/S0377-1237\(07\)80166-3](https://doi.org/10.1016/S0377-1237(07)80166-3)
2. Seigell S, Singhal S, Gupta N, Verma RR, Gulati A. Pneumosinus Dilatans: A Myriad of Symptomology. Indian J Otolaryngol Head Neck Surg. oct 2022;74(S2):1305- 9. <https://doi.org/10.1007/s12070-021-02418-x>
3. Ricci JA. Pneumosinus Dilatans: Over 100 Years Without an Etiology. Journal of Oral and Maxillofacial Surgery. juill 2017;75(7):1519- 26. <https://doi.org/10.1016/j.joms.2017.02.010>

4. Lloyd GA. Orbital pneumosinus dilatans. Clin Radiol. juill 1985;36(4):381- 6. [https://doi.org/10.1016/s0009-9260\(85\)80308-1](https://doi.org/10.1016/s0009-9260(85)80308-1)
5. Desai NS, Saboo SS, Khandelwal A, Ricci JA. Pneumosinus Dilatans: Is It More Than an Aesthetic Concern? Journal of Craniofacial Surgery. mars 2014;25(2):418- 21. <https://doi.org/10.1097/SCS.0000000000000694>
6. Walker JL, Jones NS. Pneumosinus dilatans of the frontal sinuses: two cases and a discussion of its aetiology. J Laryngol Otol. mai 2002;116(5):382- 5. <https://doi.org/10.1258/0022215021910852>
7. Al-Essa RS, Alsaleh SA, Alsuhaibani AH. Non-axial proptosis secondary to pneumosinus dilatans of the maxillary sinus. Saudi Journal of Ophthalmology. juill 2018;32(3):238- 40. <https://doi.org/10.1016/j.sjopt.2018.01.004>
8. Yazici B, Erdogmus B, Guclu E, Ozturk O. Pneumosinus dilatans of the ethmoid sinus presenting with exophthalmus: a case report and review of the literature. Dentomaxillofacial Radiology. févr 2007;36(2):105- 6. <https://doi.org/10.1259/dmfr/58933699>
9. Tellado MG, Méndez R, López-Cedrún JL, Fantini M, Martín-Sastre R, Somoza I, et al. Pneumosinus dilatans of the frontal and ethmoidal sinuses: case report. Journal of Cranio-Maxillofacial Surgery. févr 2002;30(1):62- 4. <https://doi.org/10.1054/jcms.2001.0269>

UNDER PEER REVIEW