

# The Outcome of a Single Stage Repair for Proximal Hypospadias in Otherwise Healthy Child at Mymensingh Medical College Hospital

## ABSTRACT

**Background:** Hypospadias is a birth defect that involves the development of a penile urethra that opens on the ventral side of the penis. Proximal hypospadias is one of the most severe forms of hypospadias that is generally associated with chordee. Hypospadias surgery, especially in the proximal location, is challenging, and many operations have been proposed, including one-stage and two-stage operations. **Objectives:** The aim of the study was to evaluate the success rate and safety of a single-stage surgery in children with proximal hypospadias and to determine the complications. **Materials and Methods:** This interventional study was conducted on forty patients, aged between one and twelve years, who had proximal hypospadias and were admitted to Mymensingh Medical College Hospital between January 2014 and April 2015. A one-step operation with tabularized incised plate urethroplasty (TIPU) was done. Patients' demographic data, intraoperative details, and postoperative outcomes were recorded within 3 months after the operation. **Results:** The common age at surgery was 2-4 years, and they were 40% of the total patients. There was Haematoma in 5% of cases, a devitalized skin flap in 7.5% of cases, and stent blockage in 10% of cases during the immediate postoperative period. In our 3-month follow-up, all the patients had conical glans and cylindrical penises. Meatal stenosis and narrow stream were noted in 5 percent of patients but were relieved with meatal dilatation. Urethrocutaneous fistulas remained in 7.5% of cases. **Conclusion:** TIPU repair of proximal hypospadias is safe, effective, yields good results, and has low risks of complications in otherwise healthy children. It is a less risky and more viable method that helps to exclude extra steps in the process.

**Keywords:** Hypospadias, urethroplasty, Haematoma, Urethrocutaneous, Pediatric.

## INTRODUCTION

“Hypospadias is a developmental anomaly characterized by a urethral meatus that opens on the ventral surface of the penis, proximal to the end of the glans, anywhere along the shaft of the penis, from glans to scrotum, or even in the perineum. It is one of the commonest congenital anomalies of the male genitalia occurring in approximately 1 in 300 live male births”.

<sup>(1)</sup>“Different anatomic presentations can be observed. The position of the urethral meatus can be classified as anterior or distal (glanular, coronal, or subcoronal; 60-65% of cases), middle (midpenile; 20-30% of cases), or posterior or proximal (posterior penile, penoscrotal, scrotal, or perineal 10-15% of cases). The subcoronal position is the most common. Proximal cases are considered severe and can be associated with chordee. The term chordee derives from the Greek word chorda, which means "string" or "rope" and indicates the ventral curvature of the penis”.

<sup>(2)</sup>“The chordee is itself a direct consequence of the abnormal proximal division of the corpus spongiosum and the subsequent of the ventral tissue sitting in the triangular defect. Chordee is related to the tethering of the ventral hypoplastic skin onto the underlying structures, the fan-shaped lateral and upward extension of the divided corpus spongiosum, hypoplastic distal urethra and asymmetric development of the corpora cavernosa”.

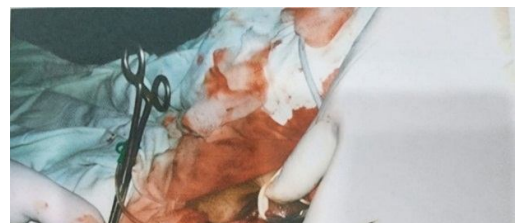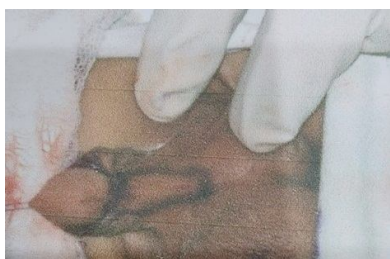
<sup>(3)</sup>“The most commonly used classification of hypospadias is Barcat's, and it is based on the location of the urethral meatus after correction of the associated ventral curvature of the penis. Proximal hypospadias include proximal penile, penoscrotal, scrotal and perineal types in which the site of the urethral meatus is respectively the proximal third of the penis, root of penis, scrotum or between the genital swellings and below the genital swellings. Proximal hypospadias are usually associated with scrotal malformations, such as penoscrotal synaechia, hypoplasia, bifid scrotum and high scrotum implantation”.

<sup>(4,26,27,28)</sup>“The developmental, psychosocial, anesthetic and surgical factors considered suggest that the period between six and eighteen months is the optimal time for elective hypospadias repair”.

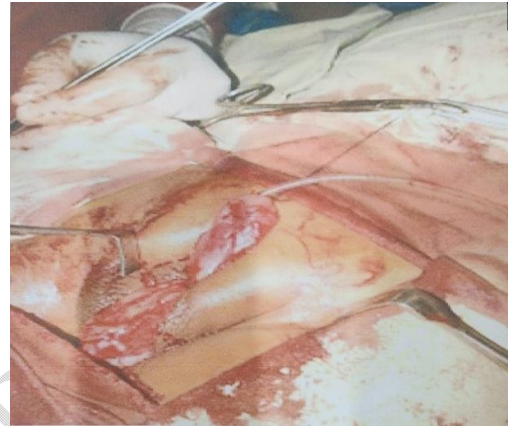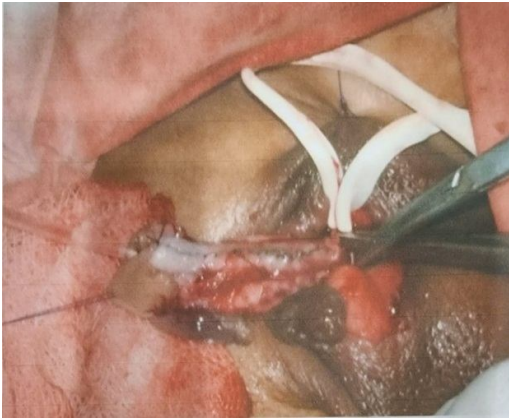<sup>(5)</sup>“The modern surgical repair of hypospadias requires an experienced dedicated specialist, whether a paediatric urologist/surgeon, a plastic surgeon (or an adult reconstructive urologist). This is not surgery for the occasional operator, therefore a volume of at least 40-50 cases per year is desirable. With advances in surgical techniques and suture materials, use of optical magnification and microsurgical instrumentation, hypospadias repair has developed into a safe and reliable procedure, with a very high reported success rate. Dedicated paediatric facilities and paediatric anaesthetic support are essential to the success of short-stay surgery in very young children”.

<sup>(6)</sup>“The surgical reconstruction of distal penile hypospadias in a single stage is the standard practice for repairing anterior hypospadias. Unfortunately, it is not simple to extrapolate the same principle to posterior hypospadias. Numerous surgical techniques have been described for

proximal hypospadias repair that can be broadly classified as single or multi-stage procedures. The multi-stage technique was formerly adopted for its simplicity and safety more than for its effectiveness, but a single-stage repair is used by many surgeons and achieves a high success rate, being safe and effective”.<sup>(7)</sup>“One stage hypospadias repair has evolved and is now the standard treatment and one stage urethroplasty with paramental foreskin flap (OUPF) was first described by Tomohiko Koyanagi as a single stage technique that is applicable to all types of proximal hypospadias. The technique appeared to provide an ideal treatment for severe proximal hypospadias, however reported complications were high. The technique was modified to improve the blood supply to the neourethral flaps. The modified technique was found to achieve nearly normal phallic cosmetic appearance with a low complication rate”.<sup>(5)</sup>“Spectrum of defect of proximal hypospadias are prepenile scrotum or bifid scrotum with normal or small penis. Proximal hypospadias repair still represents a major challenge for the paediatric and urologist surgeons proven by the high number of surgical techniques available, none without complications. Many patients suffer a high number of interventions with poor function and aesthetic results. One stage repair has the advantage of using skin that is unscarred from previous surgical procedures, with undisturbed blood supply and decrease number of hospitalization days but it is also dependent of surgeon's expertise and family request. On the other hand is often associated with re-intervention to correct complications in severe cases and poor cosmetic results. Two stage repair is usually chosen in severe primary proximal hypospadias of revisional hypospadias. The assessment of hypospadias severity is based on meatal position, quality of the urethra and urethral plate, and presence or absence of penile chordee. In general, hypospadias surgery involves three main steps: straightening of the penis (correction of chordee), reconstruction of the missing urethra (urethroplasty), and reconstruction of the tissues forming the ventral radius of the penis (glans, corpus spongiosum, and skin). Surgeons conduct both a preoperative assessment based on the clinical site of the meatus and an intra-operative assessment based on the position of the meatus after straightening of the penis”.<sup>(8)</sup>“A major advantage of single stage repair of proximal hypospadias is that all major dissection is performed in virgin, untouched tissue allowing neourethral reconstruction without any scar tissue affecting vascularity. It has the added advantage that the dissection needed permits simultaneous repair of associated penoscrotal transposition, if present. Thus, all aspects of severe proximal hypospadias can be corrected at one setting”.<sup>(9)</sup>“Penoscrotal transposition (PST) is usually associated with more severe forms of hypospadias. To prevent compromising the blood supply to the neourethra or the skin covering the penile shaft, scrotoplasty is usually deferred until the hypospadias repair is completed. The preputial flaps used in the onlay island flap. Transverse preputial island flap (TPIF) urethroplasty and other modifications remain on the blood supply from the dorsum of the penile base. The blood supply of the Snodgrass neourethra comes from both the subcutaneous tissue beneath the urethral plate and the secondary layer coverage of subcutaneous tissue from the prepuce. A deep circumferential incision all around the penile base is described in the Glenn and Anderson scrotoplasty. This may lead to devascularization of the penile shaft and preputial flap, thereby compromising circulation to the flap and the skin of the shaft of the penis. Ehrlich and Sardino noted a change that keeps a broad strip of skin at the dorsal base of the male organ for the purpose of vascularizing the subcutaneous layer of the penis. Therefore, making a logical assumption, we decided to use the Snodgrass hypospadias repair with Ehrlich and the scardino modification of PST repair in one step”.<sup>(10)</sup> “Contemplating proximal hypospadias repair poses many challenges, as the release of ventral curvature and the simultaneous reconstruction of the urethra and skin represents an ongoing dilemma. No current evidence suggests the superiority of one surgical technique over another. There is still no consensus among hypospadiologists about whether a single or multi-stage operation is the optimal treatment for proximal hypospadias”.<sup>(7)</sup>In this study current data were presented to evaluate the safety and outcome of a single stage repair of proximal hypospadias. So it was performed this interventional study which may provide helpful surgical management in patients with proximal hypospadias.

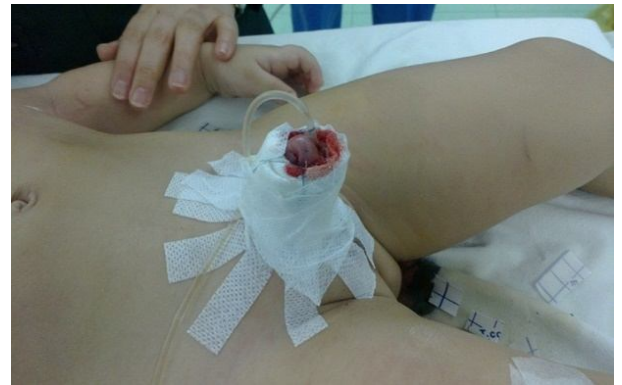
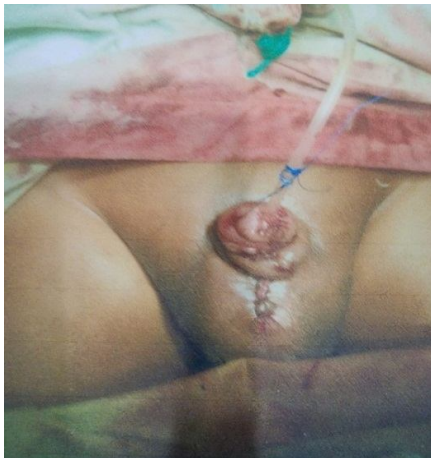
*Figure 1: U shaped incision mark of a proximal hypospadias. Figure 2: Forming Neourethra.*



*Figure 3: Formation of the Urethral Tube up to tip glans.*

*Figure 4: Taking Tunica vaginalis flap.*



*Figure 5: Complete orthoplasty, urethroplasty and re-surfacing of skin.*

*Figure 6: Povidon iodine soaked gauze dressing.*

## **MATERIALS AND METHODS**

This study was an interventional study. The patients were selected purposively by sampling method. A total number of 40 patients who were admitted in Pediatric Surgery Department in Mymensingh Medical College Hospital

(MMCH) as routine admission in outpatient department (OPD) with the complaints of proximal hypospadias were selected for this study. Follow-up period was 3 months. Results were considered satisfactory when the boy achieves a glanular meatus, single forward stream, unimpeded voiding, good cosmesis, and no need for secondary surgery for the urethra. This study was conducted at the Department of Paediatric Surgery, Mymensingh Medical College, Mymensingh, Bangladesh. At January 2014 - April, 2015.

### **Objectives:**

#### **General objectives:**

- To assess the outcome and safety of a single stage repair in managing proximal hypospadias in otherwise healthy child.

#### **Specific objectives:**

- To decide the option of a single stage repair in managing proximal hypospadias in otherwise healthy child.
- To identify the complication(s) of a single stage repair in managing proximal hypospadias in otherwise healthy child.

#### **Inclusion criteria**

- Patients in age group ranging from 1 to 12 years old having proximal hypospadias.
- Perineal skin good and thick.
- Intact urethral plate.

#### **Exclusion criteria**

- Patients having other than proximal hypospadias.
- Perineal skin poor and thin.
- Urethral plate not intact.
- Patients having intersex abnormality.
- Patients having life-threatening co-morbid condition.

#### **Procedure of Data Collection:**

Data were collected in data collection sheet (Appendix-1) after obtaining written consent of the parents/guardians in the consent form (Appendix-2). All these data were gathered systematically. After collecting detailed history of each patient, diagnosis was confirmed by clinical examinations and relevant investigations.

#### **Statistical analysis:**

Data were analyzed to obtain the result by standard statistical formula by using computer based software, Statistical Package for Social Science (SPSS, version 12.0) and taking help of the resource personnel.

## **RESULTS and DISCUSSION**

**Table 1:** Distribution of patients by age (N=40)

Age in years	Frequency	percentage
0-2	16	40.00
2-4	8	20.00
4-6	6	15.00
6-8	4	10.00
8-10	4	10.00
10-12	2	5.00
Total	40	100.00

Table 1 showed Number of patient (N=40) shows maximum incidence within 0-2 years' in age were 16 (40.00%), 2-4 years 8 (20.00%), 4-6 years 6 (15.00%), 6-8 years 4 (10.00%), 8-10 years 4 (10.00%) and 10-12 years 2 (5.00%).

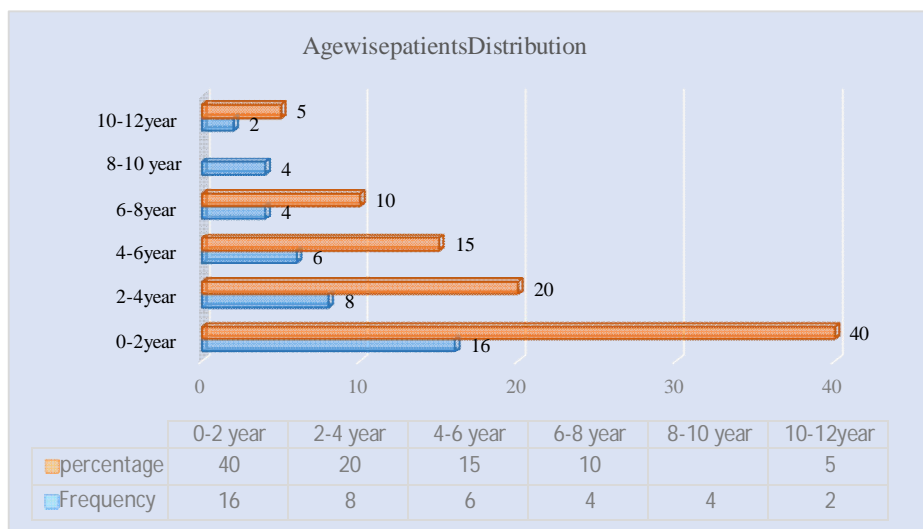


Figure 7: Bar chart showed distribution of the patients by age in two group (N=40)

Table 2: Immediate post-operative complications.

Type	Frequency	Percentage%
Hematoma	2	0.5
Devitalized skin flap	3	7.50
Stent blockage	4	10

Table 2 showed immediate postoperative complications. Haematoma were in 2 (05%), devitalized skin flap were in 03 (7.5%), stent blockage were in 04 (10%). Reassurance of the parents in all the cases and haematoma & devitalized skin flaps were observed on 3rd POD and were managed conservatively by local wound care. Stent blockage cases were 5th POD onwards and managed by repeated bladder wash with normal saline.

**Table 3: Outcome after urethroplasty**

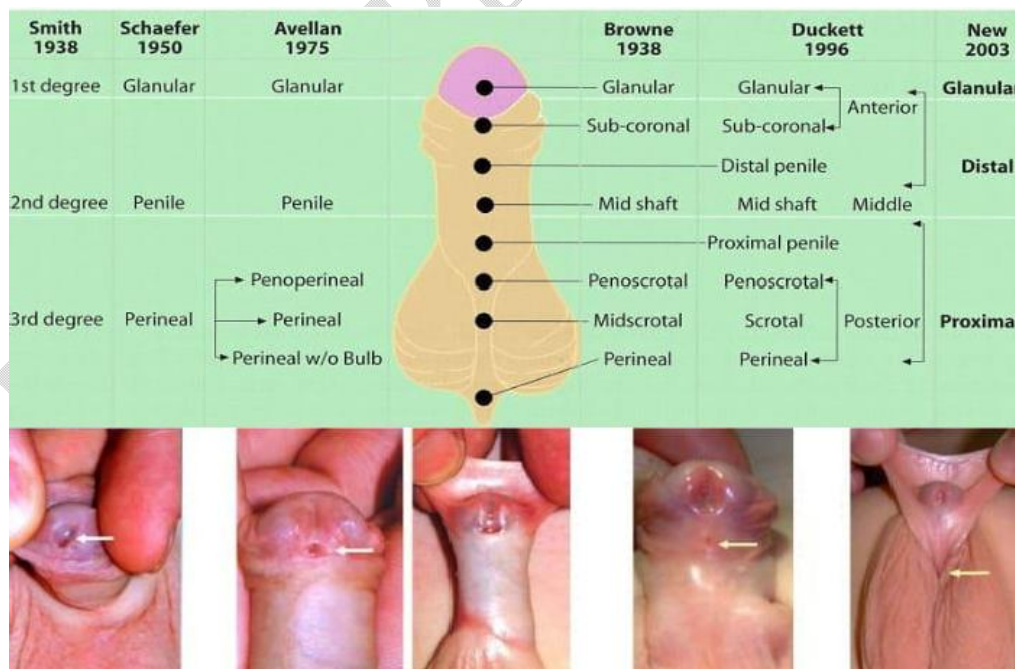
Followup period	Conical Glans	Cylindrical penis	Meatal stenosis	Narrow stream	U-Cfistula
1 <sup>st</sup> months	100%	100%	5%	5%	7.5%
2 <sup>nd</sup> months	100%	100%	5%	5%	7.5%
3 <sup>rd</sup> months	100%	100%	0%	0%	7.5%

Table 3 showed outcome after urethroplasty. Glans were conical and penis were cylindrical in shape in all cases 40 (100%) upto 3rd month followup, meatal stenosis with narrow stream urinary flow were in 2 (05%) in 1st and 2nd month followup but regular meatal dilatation relieved the problem in 3rd month followup, u-cfistula were in 3 (7.5%) cases and regular urethral dilatation proximal to fistula and controlled micturition training with manual closure of fistula opening couldn't overcome it. Parents were reassured and advised for redo urethroplasty.

**Classification**

- The anterior form: glandular, coronal and distal penile.
- The middle form: "midshaft" and proximal penile.
- The posterior form: penoscrotal, scrotal and perineal.

Other classifications are listed in the following figure.



*Figure: 8: Glandular hypospadias, Coronal Hypospadias, Midshaft Hypospadias, Penoscrotal Hypospadias.*

Proximal hypospadias has been known to be a challenging issue that has faced pediatric urologists for quite some time now, with a higher potential for complications than other hypospadias types.<sup>(1)</sup> Despite the efforts to improve the technique of this surgery, there is no proof for the multiple manifestations of this deformity. The issue of the one-stage versus the multiple-stage repair processes has remained an area of discussion, with critics of the one-stage pointing to premature conclusions after chordee release and higher overall complication rates. On the other hand, multiple-stage procedures also pose their own difficulties, such as multiple surgical and anesthetic procedures, operating on relatively ischemic scar tissue, and mental aspects of the given treatment for patients and their families. However, various one-stage procedures are still practiced in many centers, including in proximal hypospadias.<sup>(1)</sup> This work aimed at establishing a one-stage operative repair for the treatment of complex proximal hypospadias with a marked chordee, contrary to two-stage surgery. The reason for making this decision was that the risk of a second surgery to correct complications would be less than initially intending to perform two operations combined and risking a third surgery in cases of complications. This approach is consistent with several authors over the past three decades<sup>(5,9,12)</sup>. Unlike several previous studies, which showed a higher complication rate with one-stage repair, this study has given a different impression. In total, there were 40 patients in the study, whose ages varied from 1 year to 12 years, with a mean age of 4 years.  $3 \pm 3.08$  years, which agrees with a study.<sup>(8)</sup> Peak incidence of age at surgery were 2-4 years 40% (Tab-1). The distribution of proximal hypospadias anomalies was as follows: among them, 26 (65%) patients had proximal penile hypospadias with chordee, 8 (20%) had proximal penile hypospadias with torsion, and 6 (15%) had penoscrotal hypospadias with bifid scrotum, which is consistent with studies.<sup>(1,13)</sup> (Dia- 1) The early post-operative complications included Haematoma at 5%, skin flap necrosis at 7.5%, and stent blockade at 10% (Tab-2), as recorded by a study.<sup>(1)</sup> These complications include blockage of the stent, which was controlled using normal saline irrigation. Meatal stenosis after surgery was observed in 2 cases (05%) and treated with meatal dilation with the help of lubricated erythromycin eye ointment, which is supported by a study.<sup>(14)</sup> In the 3rd month follow-up, the glans were conical and the penis was cylindrical in all the cases (100%). Meatal stenosis with narrow stream urinary flow was noted in 2 (05%) cases in the first and second months of follow-up, but there was improvement in the third month after regular meatal dilatation. Urethrocuteaneous fistula was observed in 3 (7.5%) cases, and despite periodic urethral dilatation proximal to the fistula and controlled micturition training with the manual closure of the fistula opening, the problem could not be managed successfully (Tab-3). These findings agree with a study<sup>(1)</sup> but contradict by a study<sup>(5)</sup> because of the limitations of the study. The mean hospital stay in this study was 15±1 day, with a range of 14–16 days in 32 (80%) of the cases and 16–18 days in 8 (20%) cases, which was in parallel to the findings of a study<sup>(14)</sup> (Fig-6). A study<sup>(15)</sup> also underlined that shortening a hospital stay not only has the effect of reducing costs, but it also reduces cross-infection risk without affecting morbidity. Good outcomes were obtained with 37 (92.5%) of the patients, 5 of whom experienced complications (Tab-3). Three patients had urethrocuteaneous fistulas at the coronal sulcus, and two patients had meatal stenosis, which was managed by regular meatal dilation for 3 months as described by a study.<sup>(1)</sup>

The surgical technique used in all the cases of the study was tabularized incised plate urethroplasty (TIPU) for single-stage repair of proximal hypospadias. Primary success, which was considered to be reasonable cosmetic genital appearance, glanular meatus of a permissible size, and normal urinary stream, was achieved in 37 (92.5%). The overall complication rate was 7.5% (3 cases), which is in agreement with a study<sup>(16)</sup>, who described an 8% complication rate for proximal hypospadias with the modified Koyanagi repair. These outcomes differ from a study<sup>(17)</sup> that identified a complication rate of 47% or another one<sup>(18)</sup> that found a complication rate of 50%. Further, the findings do not agree with studies<sup>(19,20)</sup>, in which authors documented complication rates of 20% and 19%, respectively, using the modified Koyanagi technique. Two studies<sup>(21,22)</sup> recorded lower complication rates of 7% and 12%, respectively, by using a tubularized dorsal lateral preputial flap and a transverse preputial island onlay flap, respectively, which are in line with the results of this study. Differently, the results are not in line with the study<sup>(23)</sup>, which described a 42% complication rate using Glassberg's modification of Duckett's technique to treat proximal penile hypospadias, probably because of methodological restrictions. Complication rates of 90%, 38%, and 33% were reported by a study<sup>(24)</sup> using double-faced tubularized island flap, tubularized island flap, and onlay island flap techniques, respectively, with proximal penile hypospadias, different from a study<sup>(7)</sup>. Another study<sup>(17)</sup> described a technique of hypospadias repair by paramental-based flaps that extend distally around the distal shaft into the inner layer of the prepuce. Despite the theoretical appeal of severe proximal hypospadias, Koyanagi's series of 44 patients described a 6.88% requirement for secondary surgery. A study<sup>(18)</sup> described the rate of 50% of patients requiring additional operations using this technique as being due to the lack of blood flow to the neourethral flaps caused by the liberalization of the skin flaps from the lateral and dorsal circulation, so that the flaps are totally dependent on the circulation from the region of the urethral meatus only. Further, the septum also consists of two anastomoses, the dorsal and the ventral, which may lead to fistula formation<sup>(25)</sup>. However, the higher success rate noted in the present study using the TIPU technique, 92.5%, can be attributed to the maintenance of lateral blood supply to the skin flaps as opposed to relying solely on the microvasculature originating from the urethral meatus region and corpus spongiosum. Concerning fistulae in hypospadias surgery, the reinforcement interposition layer plays an important role in terms

of mechanical barrier and mechanical support, as well as avoiding suture line superimposition. <sup>(15)</sup>

Therefore, the TIPU technique applied at a single stage for proximal hypospadias in otherwise healthy children proved to be an effective intervention with a low percentage of complications, 7%–5%, which were correctable. These results mirror some of the earlier works but differ from others, thus pointing to the fact that management of this multifaceted disorder remains a struggle and exhibits substantial variations.

## CONCLUSION

The TIPU (Tabularized incised plate urethroplasty) one stage repair of proximal hypospadias is an innovative technique and fulfills many criteria for predictable successful surgical results. Great care should be given to meticulous dissection, optical magnification, use of fine sutures and delicate instruments. The use of tunica vaginalis wrap as a cover for the urethroplasty improves the results. Due to the severity of these abnormalities, proximal hypospadias often requires more extensive reconstruction to achieve a successful repair. Familiarity with a variety of techniques and adherence to surgical principle, such as maintaining adequate vascular supply and multilayer closure, can achieve both a cosmetically and functionally satisfactory result.

### Ethical Approval and Consent:

Prior to commencement of this study the Thesis and Ethical review committee of Mymensingh Medical College and Hospital approved the thesis protocol. The objective of the study, the nature of the disease, the investigations, treatment modalities and potential complications regarding proximal hypospadias in otherwise health child and its advantages were explained to patient's parents and informed consent was taken.

## LIMITATIONS OF THE STUDY

Study was purposive with small sample size. Short duration of study.

Study was conducted in a single tertiary hospital

### Disclaimer (Artificial intelligence)

#### Option 1:

Author(s) hereby declare that NO generative AI technologies such as Large Language Models (ChatGPT, COPILOT, etc) and text-to-image generators have been used during writing or editing of manuscripts.

#### Option 2:

Author(s) hereby declare that generative AI technologies such as Large Language Models, etc have been used during writing or editing of manuscripts. This explanation will include the name, version, model, and source of the generative AI technology and as well as all input prompts provided to the generative AI technology

Details of the AI usage are given below:

- 1.
- 2.
- 3.

## REFERENCES

1. Hassan MK, Paul AC, Khair MA, Saha RK, Hanif A, Chowdhury ASMJ. Single Stage Urethroplasty for Proximal Hypospadias with Chordee. *Faridpur Med Coll J.* 2011;6(2):66-69.
2. Giannantoni A. Hypospadias Classification and Repair: The Riddle of the Sphinx. *Eur Urol.* 2011;60(6):1190-1192.
3. Gearhart JP, Rink RC, Mouriquand PDE. *Paediatric Urology.* 2nd ed. Philadelphia: Saunders Elsevier; 2010.
4. Arap S, Mitre AI. Penoscrotalhypospedias. *Braz J Urol.* 2000;26(3):304-314.
5. Elsaied A, Saied B, El-Ghazaly M. Modified Koyanagi Technique in Management of Proximal Hypospadias. *Ann Pediatr Surg.* 2010;6(1):22-26.
6. Manzoni G, Bracka A, Palminteri E, Marrocco G. Hypospadias surgery: when, what and by whom? *BJU Int.* 2004;94(8):1188-1195.
7. Badawy H, Fahmy A. Single- vs. multi-stage repair of proximal hypospadias: The dilemma continues. *Arab J Urol.* 2013;11(2):174-181.
8. Spataru RI, Bratu N, Ivanov M. Severe proximal hypospadias repair—one stage versus two stage repair. *JurnalulPediatriului.* 2013;16(63-64):54-57.
9. Jayanthi VR, Emir H, Nitahara K, Danismend N, Koff SA. The modified Koyanagi hypospadias repair for the one-stage repair of proximal hypospadias. *J Urol.* 2000;164(3 Pt 2):973-976.
10. ElGanainy EO, Abdelsalam YM, Gadelmoula MM, Shalaby MM. Combined Mathieu and Snodgrass urethroplasty for hypospadias repair: A prospective randomized study. *Int J Urol.* 2010;17(7):661-665.
11. Rynja SP, de Jong TPV, Bosch JLHR, de Kort LMO. Functional, cosmetic and psychosexual results in adult men who underwent hypospadias correction in childhood. *J Pediatr Urol.* 2011;7(5):504-515.
12. Springer A, Krois W, Horcher E. Trends in Hypospadias Surgery: Results of a Worldwide Survey. *Eur Urol.* 2011;60(6):1184-1189.

13. Hadidi AT. Lateral based flap: A single stage urethral reconstruction for proximal hypospadias. *J Pediatr Surg.* 2009;44(4):797-801.
  14. Singh RB, Pavithran NM. Partially de-epithelialized preputial flap (triangular soft tissue flap): an aid to prevent coronal urethrocutaneous fistulae. *PediatrSurg Int.* 2003;19(7):551-553.
  15. Elkassaby M, Shahin MM, El-Sayaad IM, Arnos AA. Comparative study between modified Koyanagi and Snodgrass techniques in management of proximal types of hypospadias. *J Taibah Univ Med Sci.* 2013;8(2):97-104.
  16. Hayashi Y, Kojima Y, Mizuno K, et al. Neo-modified Koyanagi technique for the single-stage repair of proximal hypospadias. *J Pediatr Urol.* 2007;3(3):239-242.
  17. Koyanagi T, Matsuno T, Nonomura K, Sakakibara N. Complete repair of severe penoscrotal hypospadias in 1 stage: experience with urethral mobilization, wing flap-flap urethroplasty and "glanulomeatoplasty". *J Urol.* 1983;130(6):1150-1154.
  18. Glassberg KI, Hansbrough F, Horowitz M. The Koyanagi-Nonomura 1-stage bucket repair of severe hypospadias with and without penoscrotal transposition. *J Urol.* 1998;160(3 Pt 2):1104-1107.
  19. Emir H, Jayanthi VR, Nitahara K, Danismend N, Koff SA. Modification of the Koyanagi technique for the single stage repair of proximal hypospadias. *J Urol.* 2000;164(3 Pt 2):973-976.
  20. Elhalaby EA. One-stage feminizing genitoplasty in patients with congenital adrenal hyperplasia. *Ann Pediatr Surg.* 2006;2(2):88-98.
  21. Joseph VT. One-stage surgical correction of proximal hypospadias. *Ann Acad Med Singap.* 2003;32(1):106-111.
  22. Kuyumcuoglu U, Eryildirim B, Faydaci G, Tarhan F, Ozgöl A. The comparison of belt-fuqua and 'TIPU' techniques in proximal penile hypospadias cases: retrospective analysis of 65 cases. *IntUrolNephrol.* 2009;41(4):755-759.
  23. Zaontz MR, Dean GE. Glanular hypospadias repair. *UrolClin North Am.* 2002;29(2):291-298.
  24. Demirbilek S, Kanmaz T, Aydin G, Yücesan S. Outcomes of one-stage techniques for proximal hypospadias repair. *Urology.* 2001;58(2):267-270.
  25. Zaidi RH, Casanova NF, Haydar B, Voepel-Lewis T, Wan JH. Urethrocutaneous fistula following hypospadias repair: regional anesthesia and other factors. *PaediatrAnaesth.* 2015;25(11):1144-1150.
- 26 Elmaadawy, Mohamed Ibrahim Ahmed, Osama Mostafa Elgamal, Mohamed Adel Omar, and Samir Abd El Hakim El-Gamal. 2022. "Evaluation of Preputial and Buccal Mucosal Grafts in Two-Stage Repair of Severe Proximal Hypospadias". *Journal of Advances in Medicine and Medical Research* 34 (22):335-48. <https://doi.org/10.9734/jammr/2022/v34i224821>.
- 27 Salle, J. P., Sayed, S., Salle, A., Bagli, D., Farhat, W., Koyle, M., & Lorenzo, A. J. (2016). Proximal hypospadias: a persistent challenge. Single institution outcome analysis of three surgical techniques over a 10-year period. *Journal of pediatric urology*, 12(1), 28-e1.
- 28 Andersson, M., Sjöström, S., Wängqvist, M., Örtqvist, L., Nordenskjöld, A., & Holmdahl, G. (2018). Psychosocial and sexual outcomes in adolescents following surgery for proximal hypospadias in childhood. *The Journal of urology*, 200(6), 1362-1370.

**APPENDIX:**

**Appendix – I**

**Mymensingh Medical College Hospital, Mymensingh.**

**DATA COLLECTION SHEET**

**Title: THE OUTCOME OF A SINGLE STAGE REPAIR FOR PROXIMAL HYOSPEDIAS IN OTHERWISE HEALTHY CHILD"**

**1. Case serial no** : **2. Hospital reg. No** :

**3. Ward/Bed** : **4. Date of data collection** :

**5. Particulars of the patients:**

Name : Age :  
Sex : Father's/Mother's name :  
Informer : Address :  
Date of admission : Date of discharge :

**1. Presenting complains:**

- External urethral opening at abnormal site
- Abnormal looking penis
- Narrow stream of urine
- Deflected flow of urine
- Others.:

**4. Family history** :

Consanguinity : Absent  Present

Father : Affected  Not affected

Other siblings : Affected  Not affected

**5. Treatment history** :

H/O genital operation : Absent  Present

Name of procedure :

Postoperative complications: Absent  Present

**6. Physical Examination :**

General condition :  
Appearance :  
Anaemia :  
Jaundice :  
Dehydration :  
Temperature :  
Pulse :  
Respiratory rate :  
Weight :

**7. Local Examination :**

Shape of glans :  
Prepuce : Normal  Dorsal hood  Circumcised

External urethral meatus : Normal  Narrow  Megameatus

Chordee : Mild chordee

: Skin chordee  Moderate  Severe

Skin of genitalia :

Prepenile Scrotum :

Bifid Scrotum :

**8. Associated anomalies :**

**9. Per-abdominal examination:**

Flanks :

Liver :

Spleen :

Kidney :

Urinary bladder :

**10. Investigations :**

TC of WBC :

DC of WBC :

Hb% :

BT and CT :

S. Creatinine :

Urine for R/M/E & C/S :

USG of whole abdomen :

Special attention to KUB

Chest skiagram :

**11. Operation note :**

Date of operation :

Procedure :

Type of wrap :

Duration of operation :

Suture material :

Size of the stent :

Type of dressing :

**12. Postoperative management:**

Antibiotics :

Analgesics :

Laxative :

**13. Postoperative follow-up:**

Complications	1 <sup>st</sup> POD	2 <sup>nd</sup> POD	3 <sup>rd</sup> POD	4 <sup>th</sup> POD	5 <sup>th</sup> POD	6 <sup>th</sup> POD	7 <sup>th</sup> POD	8 <sup>th</sup> POD	After 1 Month	After 1 Month	After 1 Month
Fever											
Haematoma in penile shaft											
Stent blockage											
Condition of glans & skin											
Wound condition:											
Healthy, devitalized or partial disruption											
U-C fistula											
Meatal stenosis											

**14. Hospital stay:**

---

Signature of investigator

**Appendix - II**

**Consent form**

(Verbally translated into bangle)

I....., hereby give my well informed consent for participation of my child in the study conducted by Dr. Md. Sakhawat Hossain of department of Paediatric Surgery, Mymensingh Medical College Hospital, Mymensingh. I have fully understood that participation in this study will bring fruitful medical information for my child and many in the future.

I am convinced that participation in this study my child will not be exposed to any physical, psychological, social or legal risk. The privacy and confidentiality of my child and that of myself will be safeguarded and our anonymity will be protected. I would not claim any monetary benefit for this,

Signature/Thumb impression

(Parent/legal guardian)

Date: .....