

Diagnostic Value of Fiberoptic Bronchoscopy in Non-Resolving Pneumonia: Case Series and Implications

Abstract

Non-resolving or slowly resolving pneumonia presents a significant diagnostic challenge, characterized by persistent radiographic abnormalities despite appropriate antibiotic therapy. This study explores the pivotal role of Fiberoptic Bronchoscopy (FOB) in diagnosing and managing non-resolving pneumonia. Through detailed case presentations, the study illustrates how FOB facilitates precise sampling and identification of underlying causes such as malignancies, infections, and other pulmonary conditions. FOB's ability to provide cytological, microbiological, and pathological insights proves essential in guiding targeted treatment strategies, ultimately improving patient outcomes. The cases discussed underscore the importance of FOB in resolving diagnostic uncertainties, particularly in complex clinical scenarios where standard treatments fail.

Keywords: non-resolving pneumonia, fiberoptic bronchoscopy, adenocarcinoma, Mycobacterium tuberculosis,

INTRODUCTION

The terms "non-resolving" or "slowly resolving" pneumonia are frequently used to describe the persistence of radiographic abnormalities beyond the expected timeframe (1). Non-resolving pneumonia is defined as a clinical condition where focal infiltrates associated with acute pulmonary infection do not improve or worsen after at least 10 days of antibiotic treatment, or when radiographic opacities do not resolve within 12 weeks (2). A frequent reason for pulmonary consultation is the lack of adequate understanding regarding the expected progression and outcome of community-acquired or hospital-acquired pneumonia. This uncertainty complicates patient selection and the timing of further evaluations. Non-resolving pneumonia represents 10% to 15% of nosocomial cases and is believed to account for about 15% of inpatient pulmonary consultations and 8% of bronchoscopies(3). Evaluating patients with non-resolving pneumonia is highly challenging. It necessitates an aggressive approach to avoid delays in diagnosis and treatment, as delays can increase mortality rates by 3% to 5% for both community-acquired and hospital-acquired pneumonia(4,9,10). Common causes of non-resolving pneumonia include incorrect diagnosis, inadequate antibiotic therapy, impaired host defence, atypical organisms, resistant pathogens, non-infectious causes, tuberculosis, and endobronchial lesions. Persistent or incomplete resolution of pneumonia, despite treatment, necessitates more aggressive evaluation. Microbiological, cytological, and histopathological tests of specimens can help diagnose the underlying cause(4). The fiberoptic bronchoscope is highly beneficial as it facilitates early and accurate diagnosis of non-resolving pneumonia, helping to differentiate between pyogenic causes and ruling out bronchogenic carcinoma(5). Among the various diagnostic methods available to physicians, fiberoptic bronchoscopy stands out as a highly effective tool for diagnosing non-resolving pneumonia. Its success rate in determining the cause of non-resolving or slowly resolving pneumonia ranges from 70% to 86% according to some studies. In this study, our goal was to establish the role of fiberoptic bronchoscopy in diagnosing the aetiology of non-resolving or slowly resolving pneumonia(1).

Case presentation :

CASE 1

A 60-year-old female was admitted due to a three-month history of worsening dry cough, decreased appetite, and a recent weight loss of 2 kg. Previously treated with azithromycin + beta-lactam and levofloxacin + colistin for right lower lobe pneumonia, she had inconclusive results from sputum cultures and gene xpert tests. Initial imaging including chest x-ray and CT scans showed consolidation in the right lower lobe, along with multiple nodular consolidations and enlarged mediastinal lymph nodes. Despite multiple antibiotic courses, subsequent CT scans indicated worsening lung opacification and increased lymph node size. The patient had a past history of sputum-positive pulmonary tuberculosis five years ago, with no significant family history. Physical examination revealed normal vital signs but notable respiratory findings including crepitations, tubular bronchial breath sounds, increased vocal resonance, positive egophony, and whispered pectoriloquy in specific lung areas. PET-CT scan revealed FDG-avid large consolidation-like lesions in the right lower lobe, multiple opacities in the right upper and left lower lobes, and FDG-avid enlarged lymph nodes. Skeletal lesions were noted in the sacral ala, right acetabulum, and right ischium. Fiberoptic bronchoscopy and Endobronchial Ultrasound-guided Transbronchial Needle Aspiration (EBUS-TBNA) were performed, with samples collected for cytology, culture, gene xpert testing, and histopathological examination. The evaluation confirmed a diagnosis of non-small cell carcinoma, likely adenocarcinoma, with BAL fluid testing positive for epithelial malignancy, supporting the cytological findings.

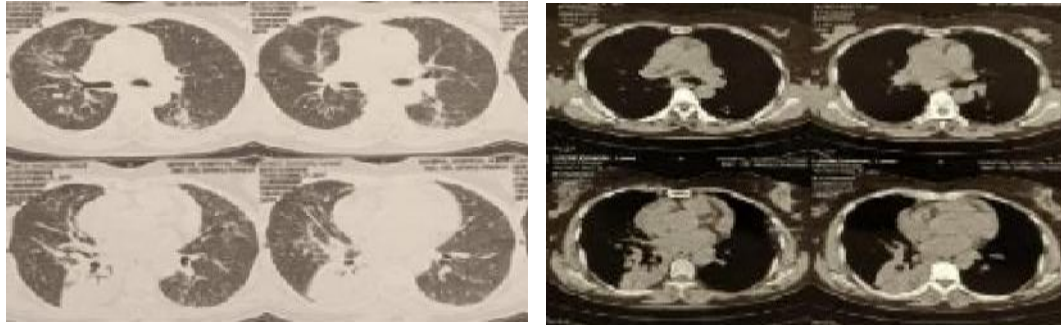


FIGURE 1 : CT scan of chest on February 2023 showing consolidation in the right lower lobe, along with multiple nodular consolidations and enlarged mediastinal lymph nodes.

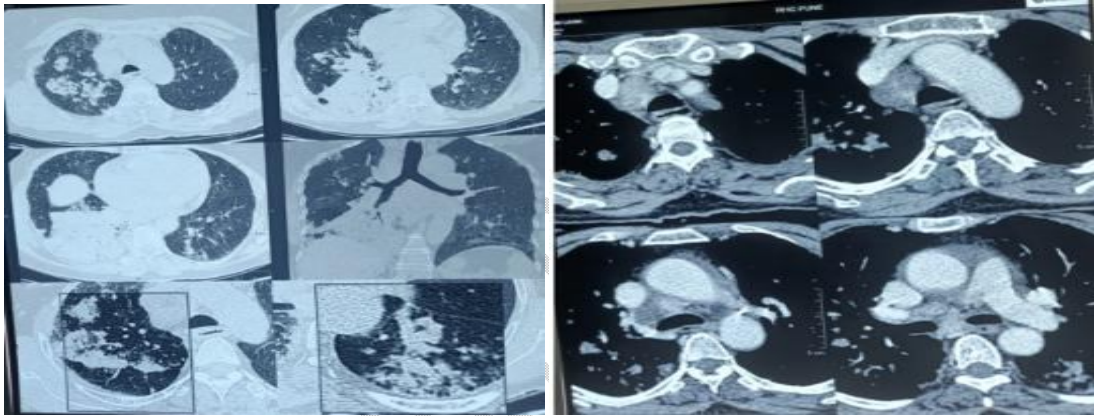


Figure 2: CT scan of the chest on May 2023 showing worsening lung opacification and increased lymph node size.

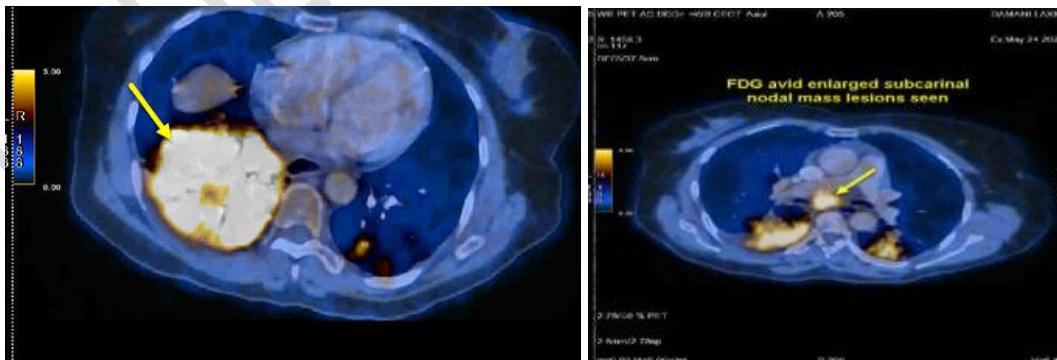


FIGURE 3 : PET-CT scan of chest on May 2023 showing FDG-avid large consolidation-like lesions in the right lower lobe, multiple opacities in the right upper and left lower lobes, and FDG-avid enlarged lymph nodes.

CASE 2

A 58-year-old male presented with progressive dyspnea on exertion, escalating from Grade 2 to Grade 3 on the Modified Medical Research Council (MMRC) scale over three months. He denied symptoms such as cough, fever, hemoptysis, weight loss, loss of appetite, or chest pain. A chronic bidi smoker for two decades, he had a history of COPD for 15 years with irregular treatment. In December 2022, he was diagnosed with bilateral lower lobe pneumonia, with initial sputum acid-fast bacilli (AFB) and culture tests yielding negative results. Despite antibiotic therapy, follow-up imaging a month later revealed persistent lung opacities involving the right middle and lower lobes, as well as the left lower lobe. On physical examination, he exhibited a normal temperature, heart rate, and blood pressure, with oxygen saturation at 94% on room air and no other systemic abnormalities noted. Respiratory auscultation revealed normal vesicular breath sounds with crepitations in the right and left infrascapular regions, along with findings of increased vocal resonance, positive egophony and whispered pectoriloquy in the right infrascapular area. Fiberoptic bronchoscopy and bronchoalveolar lavage (BAL) sample analysis were performed, revealing no bacterial growth, an AFB smear score of +3, and positive gene xpert results for *Mycobacterium tuberculosis* without rifampicin resistance. Initial line probe assay (LPA) testing indicated sensitivity to rifampicin and isoniazid, guiding the commencement of targeted anti-tubercular therapy.

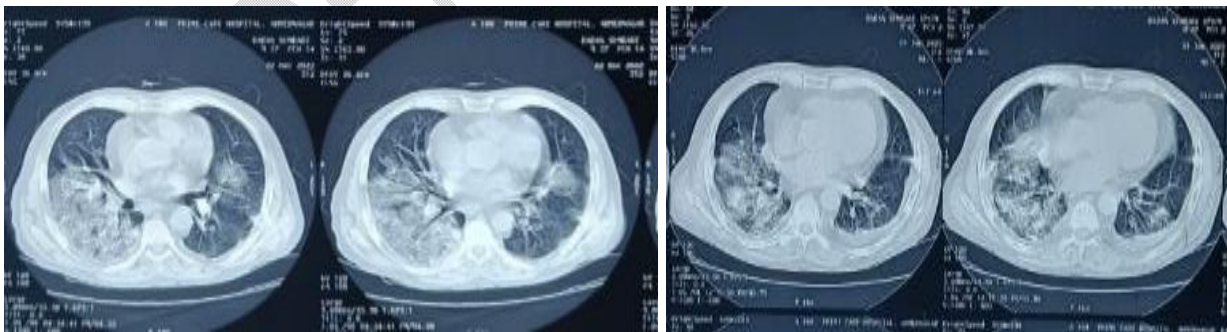


FIGURE 4.a- CT THORAX ON 22nd DEC 2022

FIGURE 4.b- CT THORAX ON 1st JAN 2023

FIGURE 4- In December 2022, a CT scan revealed bilateral lower lobe pneumonia. Subsequent imaging on January 1, 2023, showed persistent lung opacities affecting the right middle and lower lobes, as well as the left lower lobe.

CASE 3

An 86-year-old female presented with a month-long history of low-grade fever, persistent cough with yellow sputum, decreased appetite, and unintentional weight loss of 2 kg. She had a background of childhood bronchial asthma and was previously hospitalized for bilateral lower lobe pneumonia in December 2022, during which initial investigations including sputum culture and AFB testing were inconclusive. Despite a course of Piperacillin-Tazobactam and Azithromycin, she declined bronchoscopy at the time and was discharged. Upon readmission with similar symptoms, imaging revealed extensive consolidation and persistent opacification across both lower lobes, lingula, right middle lobe (RML), and right upper lobe (RUL). Physical examination indicated fever, tachycardia, tachypnea, and hypoxemia, with auscultation revealing crepitations and findings suggestive of right-sided consolidation. Subsequent Fiberoptic Bronchoscopy (FOB) with bronchoalveolar lavage (BAL) confirmed the presence of *Mycobacterium tuberculosis*, sensitive to rifampicin and isoniazid, highlighting FOB's role in diagnosing and managing refractory pneumonia cases, especially in the context of atypical presentations and initial diagnostic challenges.

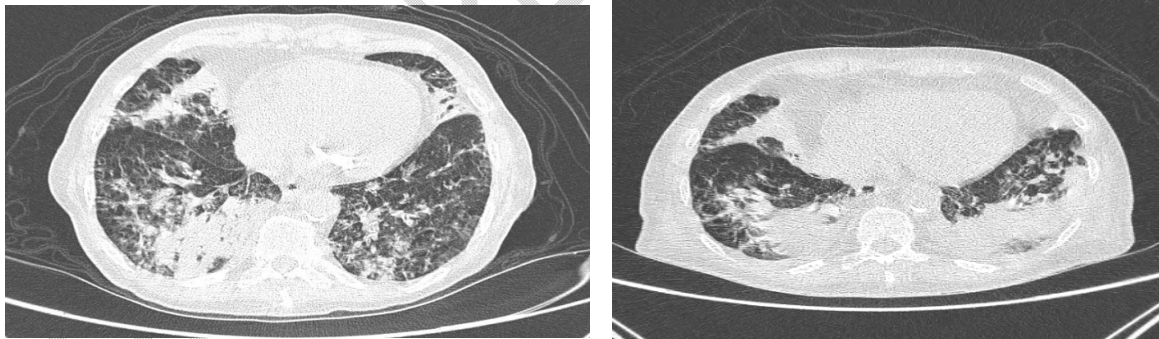


FIGURE 5.a-CT THORAX ON 11/12/2022 **FIGURE 5.b-CT THORAX ON 04/04/2023**

FIGURE 5 – CT thorax showing Collapse consolidation is observed in the posterobasal and lateral segments of both lower lobes, with patchy consolidation in the basal segments of both lower lobes, lingula, RML, and posterior basal segment of the RUL. There is also an increase in consolidation compared to the previous CT.

DISCUSSION

Non-resolving or slowly resolving pneumonia is a common clinical challenge for pulmonologists and remains a significant concern in daily clinical practice. Amberson was the first person to describe the term “unresolved organizing or protracted pneumonia” in 1943(1). There is a lack of uniformity regarding the definition of non-resolving pneumonia, but in many studies, the entity of “slow resolution” has been defined as failure of radiographic resolution by 50% in 2 weeks or failure of complete resolution by one month despite adequate antibiotic therapy (3). Chalmers et al. reported that if clinical improvement is not observed by the third day, the diagnosis should be reassessed(2).

The first case of a 60-year-old woman with non-resolving pneumonia despite multiple antibiotic treatments highlights the challenges that Fiberoptic Bronchoscopy (FOB) addresses in such situations. When standard treatments fail and imaging shows persistent lung abnormalities, FOB becomes essential for identifying the underlying cause. In this instance, FOB allowed doctors to collect precise samples for detailed analysis, revealing adenocarcinoma—a type of lung cancer that mimicked pneumonia symptoms. This diagnostic clarity was crucial in guiding timely and appropriate treatment strategies.

Bronchoscopy plays a crucial role in diagnosing malignancies associated with non-resolving pneumonia by enabling direct visualization of the bronchial tree and facilitating tissue sampling techniques such as bronchial biopsies, bronchoalveolar lavage (BAL), and endobronchial ultrasound-guided transbronchial needle aspiration (EBUS-TBNA). Non-resolving pneumonia in these cases often originates from airway obstruction caused by cancer. Additionally, conditions like pulmonary embolism and infections resistant to standard treatments can also contribute. Therefore, bronchoscopy, complemented by CT-guided biopsy when necessary, functions as an essential diagnostic tool for effectively identifying and managing non-resolving or slowly resolving pneumonia in complex clinical scenarios (6). The procedure also allows for bronchoalveolar lavage (BAL), enabling cytological, microbiological, and pathological examinations that guide targeted treatment. Additionally, it facilitates the

removal of mucus plugs or obstructive material, enhancing airway clearance and promoting the resolution of pneumonia(7).

The second case of a 58-year-old male with chronic obstructive pulmonary disease (COPD) and a history of bilateral lower lobe pneumonia. Despite initial antibiotic therapy, persistent opacifications necessitated FOB, which revealed *Mycobacterium tuberculosis* infection confirmed by positive gene expert testing. This enabled prompt initiation of appropriate anti-tubercular treatment based on drug sensitivity results, illustrating FOB's critical role in diagnosing and managing infectious etiologies in complex pulmonary conditions. Similarly, in the third case of an 86-year-old female with recurrent pneumonia, FOB was instrumental in diagnosing *Mycobacterium tuberculosis* infection after initial treatments failed to resolve symptoms. Despite negative initial sputum cultures and AFB tests, FOB-guided BAL sample analysis using gene xpert identified tuberculosis with sensitivity to rifampicin and isoniazid. This precise diagnosis facilitated targeted antimicrobial therapy, underscoring FOB's utility in detecting latent infections and guiding effective treatment decisions in elderly patients with recurrent pneumonia. These cases emphasize FOB's vital role in resolving diagnostic uncertainties and improving patient outcomes in challenging NRP presentations.

Overall, fiberoptic bronchoscopy is a valuable tool in the diagnostic and therapeutic management of non-resolving pneumonia, providing critical insights that aid in accurate diagnosis and effective treatment. Particularly in cases where sputum smear tests are negative for pulmonary tuberculosis, fiberoptic bronchoscopy becomes essential. It helps identify underlying causes of persistent pneumonia, with pulmonary tuberculosis being a common aetiology (1). Since tuberculosis is endemic in India, fiberoptic bronchoscopy provides a higher diagnostic yield for endobronchial tuberculosis. Silver et al. identified tuberculosis as the cause of non-resolving pneumonia in 5.7% of cases through the culture of bronchoalveolar lavage (BAL) fluid(15). Jacomelli et al. in their previous study have also demonstrated the good utility of bronchoscopy for the diagnosis of pulmonary tuberculosis in patients with negative sputum smear microscopy results (1). Any delay in diagnosing tuberculosis in such patients can increase the risk of developing drug-resistant forms of the disease. Accurate diagnosis and appropriate treatment are crucial in such cases, as

any mistake in either can significantly impact the prognosis of tuberculosis, particularly in India (1).

CONCLUSION

Fiber-optic bronchoscopy emerges as a crucial diagnostic tool, contributing significantly to enhancing diagnostic accuracy in cases of non-resolving pneumonia.

CONSENT

As per international standards or university standards, patient(s) written consent has been collected and preserved by the author(s).

ETHICAL APPROVAL

As per international standards or university standards written ethical approval has been collected and preserved by the author(s).

COMPETING INTERESTS

Authors have declared that they have no known competing financial interests non-financial interests OR personal relationships that could have appeared to influence the work reported in this paper.

Disclaimer (Artificial intelligence)

Author(s) hereby declare that NO generative AI technologies such as Large Language Models (ChatGPT, COPILOT, etc) and text-to-image generators have been used during the writing or editing of manuscripts.

REFERENCES

1. Mishra G. Role of Fiberoptic Bronchoscopy in Non-Resolving Pneumonia [Internet]. 2017 [cited 2024 Jun 14]. Available from: https://www.academia.edu/64318170/Role_of_Fiberoptic_Bronchoscopy_in_Non_Resolving_Pneumonia
2. Madhavi KV, Praveena S, Praveen JV, Kumar S. Role of fiberoptic bronchoscopy in early diagnosis of non-resolving pneumonia. *Panacea J Med Sci.* 2023;13:423-426. doi:10.18231/j.pjms.2023.080
3. Ost D, Fein A, Feinsilver SH. Nonresolving pneumonia - UpToDate [Internet]. [cited 2024 Jun 25]. Available from: <https://www.uptodate.com/contents/nonresolving-pneumonia>
4. Chaudhuri A, Mukherjee S, Nandi S, Bhuniya S, Tapadar S, Saha M. A study on non-resolving pneumonia with special reference to role of fiberoptic bronchoscopy. *Lung India.* 2013;30(1):27-32.
5. Balakrishnan RK, Mishra G, Ghorpade SV. Role of Fiberoptic Bronchoscopy in Non-Resolving Pneumonia. *Natl J Med Res.* 2016;6(4):316–20.
6. Arab T, Malekzadegan MR, Morante J, Cervellione KL, Fein AM. Nonresolving pneumonia in the setting of malignancy. *Curr Opin Pulm Med.* 2019;25(4):331-335. doi:10.1097/mcp.0000000000000588
7. B Jaiprakash. V Varkey, K Anithakumari. Etiology and out-come of non-resolving Pneumonia. *Journal of Asso of Phy-sicians of India*,2012;60:20-23
8. Ferretti GR, Jankowski A, Rodiere M, Brichon PY, Brambilla C, Lantuejoul S. CT-guided biopsy of non resolving focal airspace consolidation. *J Thorac Imaging.* 2008;23:7–12.
- 9 Wang L, Xie Q, Xu S, Li H, Zhang L, Ai J, Liu Q, Chu C, Zhang X, Zhang W, Huang L. The role of flexible bronchoscopy in children with *Mycoplasma pneumoniae* pneumonia. *Pediatric Research.* 2023 Jan;93(1):198-206.

10 Chaulagain CP, Pilichowska M, Brinckerhoff L, Tabb M, Erban JK. Secondary pulmonary alveolar proteinosis in hematologic malignancies. Hematology/Oncology and Stem Cell Therapy. 2014 Dec 1;7(4):127-35.

UNDER PEER REVIEW