

# **Idiopathic Pericardial Tamponade in the Absence of Predisposing Factors: A Diagnostic Conundrum and Therapeutic Approach**

## **Abstract:**

Pericardial effusion, while not uncommon, poses significant diagnostic and therapeutic challenges, particularly when presenting as tamponade, especially in young individuals without identifiable risk factors. We present a compelling case of a 19-year-old with acute dyspnea ultimately diagnosed with idiopathic pericardial tamponade. Despite a comprehensive evaluation ruling out infectious, neoplastic, and autoimmune etiologies, the underlying cause remained elusive. Urgent intervention via ultrasound-guided pericardiocentesis revealed hemorrhagic fluid, underscoring the critical role of timely management. Treatment with aspirin and colchicine resulted in symptom resolution, highlighting the efficacy of this therapeutic approach. Long-term follow-up demonstrated no recurrence, emphasizing the favorable prognosis associated with conservative management. This case underscores the importance of a systematic diagnostic approach and the need for further research to elucidate the pathophysiology and refine treatment strategies for this perplexing condition

**Key words:** Pericardial effusion, tamponade, idiopathic, non-steroid anti-inflammatory drugs, colchicine, pericardiocentesis.

## **Introduction:**

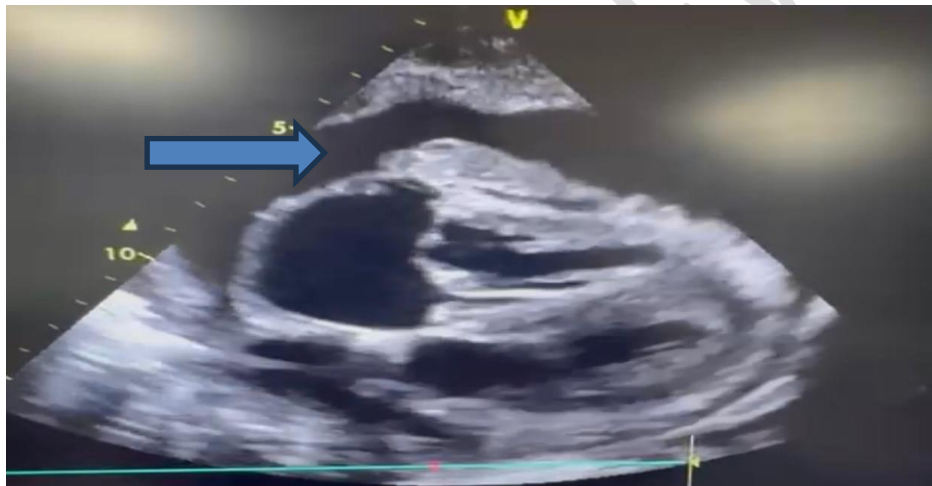
Introduction: The pericardium is formed of 2 pericardial layers, a thick visceral layer also called the epicardium when it adheres to the myocardium, and a fibrous layer, which constitutes a sac containing fluid between the 2 layers that must not exceed 50 mL in physiological situations [1]. In certain pathological situations, pericardial fluid may accumulate and form a pericardial effusion with different aspects, quantities, and biochemistry. These situations may involve infectious causes, such as tuberculosis and viral infections or parasitic diseases, or non-infectious causes, such as neoplasms, metabolic diseases, inflammatory diseases, traumas, or after an invasive or surgical procedure [1][2]. This effusion can also be idiopathic in origin. Pericardial disease can lead to tamponade regardless of the cause and can have life-threatening consequences [2]. Cardiac tamponade is rarely observed in cases of effusion or pericarditis of idiopathic origin [1]. This discussion focuses on a rare case of idiopathic tamponade in a young adult, emphasizing diagnostic challenges, management strategies, and potential implications for clinical practice.

## **Case presentation:**

A 19-year-old young adult, with no significant medical history, particularly no underlying heart disease or acute joint rheumatism, no history of flu-like syndrome or tuberculosis exposure, no autoimmune disease or malignancies, and without modifiable cardiovascular risk factors, presented to the emergency department with acute dyspnea for 7 days. His symptoms began 15 days before admission with acute dyspnea on intense exertion, which worsened 7 days later, becoming present at rest without chest pain, cough, fever, or other associated symptoms. Vital signs on admission noted a blood pressure of 104/62 mmHg, heart

rate of 95 beats/minute, respiratory rate of 27 breaths/minute, oxygen saturation of 98% on room air, afebrile at 37°C, without jugular vein distention or lower limb edema. General examination revealed no cutaneous mucosal pallor or skin signs, cardiovascular examination noted muffled heart sounds, pleuropulmonary examination revealed bilateral pleural effusion, abdominal examination showed no splenomegaly or hepatomegaly, lymph node examination was negative, the osteoarticular examination was unremarkable, and urogenital examination was normal.

An emergency electrocardiogram showed regular sinus rhythm at 80 beats/minute, fixed and constant PR interval of 140 ms, low voltage QRS complexes, and no ST-T abnormalities. A frontal chest X-ray revealed cardiomegaly and bilateral moderate pleural effusion, predominantly on the right side. Transthoracic echocardiography (TTE) demonstrated circumferential large pericardial effusion, significant variations in mitral and aortic flows, and collapse of the right heart chambers, while left ventricular function was preserved with normal ejection fraction (FIGURE 1). A cervico-thoraco-abdomino-pelvic computed tomography (CT) scan showed large pericardial effusion, moderate right-sided pleural effusion, and mild left-sided pleural effusion, without other abnormalities (FIGURES 2 AND 3).

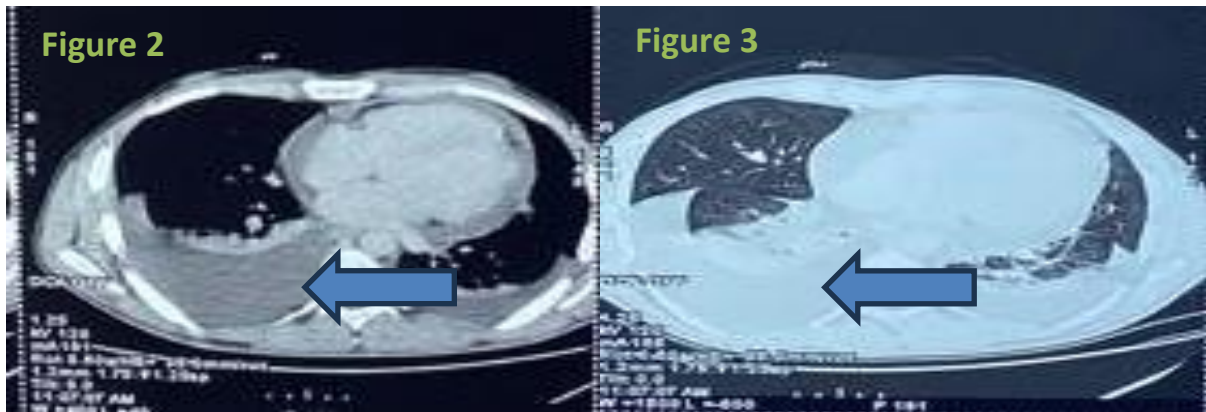


**Figure 1 : TTE showing a large pericardial effusion predominant in front of the right cavities with collapses of right ventricular.**

Laboratory findings revealed:

- Hemoglobin: 12.7 g/dL Platelets: 449,000/mm<sup>3</sup>.
- Leucocytes: 9,190/mm<sup>3</sup> Neutrophils: 5,780/mm<sup>3</sup> Lymphocytes: 1,830/mm<sup>3</sup>.
- Monocytes : 1,000/mm<sup>3</sup> Eosinophils: 520/mm<sup>3</sup>.
- 1st-hour sedimentation rate: 60 mm CRP: 46.30 mg/L Procalcitonin: 0.04 ng/mL.
- Troponin high-sensitive: negative.
- Normal coagulation profile.
- Normal renal and electrolyte balance.
- No hepatic cytolysis.
- Negative COVID-19 serology.
- Negative CMV, EBV, HSV, HIV, HCV, HBV, and syphilis serologies.
- Exhaustive negative immunological panel.
- Negative tumor markers.

- Negative Genexpert in sputum and expectorations.



**Figures 2 and 3: Thoracic CT showing pleural effusion.**

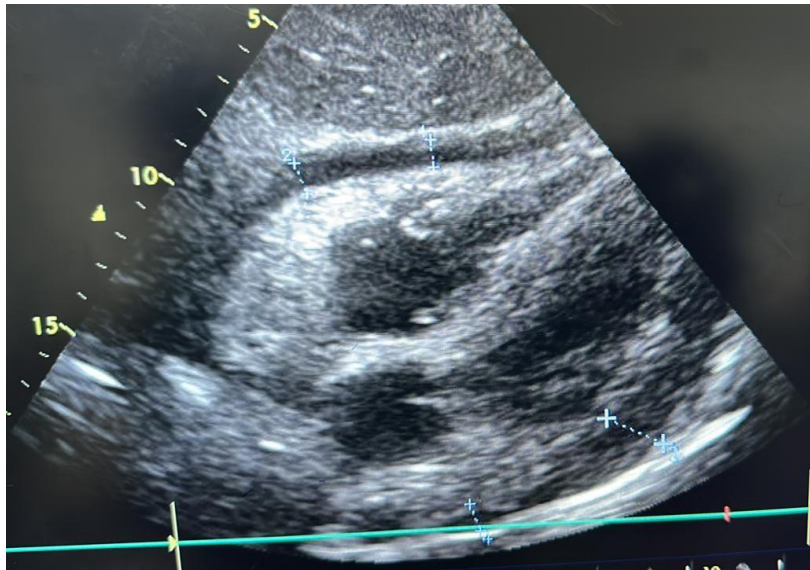
Twelve hours after admission, the patient developed cardiac tamponade with a blood pressure of 91/50 mmHg and a heart rate of 118 beats/minute, along with increased effusion on TTE and significant variations in mitral, aortic, and tricuspid flows, indicating tamponade. Given this clinical picture, ultrasound-guided subxiphoid pericardiocentesis under local anesthesia was performed for diagnostic and therapeutic purposes, yielding 750 mL of hemorrhagic fluid, along with ultrasound-guided pleural puncture.

Analysis of the pericardial fluid revealed:

- Red blood cells: 236,000/mm<sup>3</sup>
- White blood cells: 5,300/mm<sup>3</sup> (92% lymphocytes)
- Protein: 60 g/L
- Negative culture
- Negative tuberculosis search

Pleural fluid results were similar. The pulmonology team did not recommend an evacuative pleural puncture.

The etiological diagnosis favored idiopathic origin.



**Figure 4: TTE showing the reduction of the pericardial effusion's size.**

The patient was treated with aspirin 1 g three times daily for symptom relief, with gradual tapering every 2 weeks by 500 mg until cessation, and colchicine 1 mg/day for a weight of 75 kg for 3 months. During hospitalization, effusion was moderate for the first 3 days post-puncture, then decreased to mild on the 4th day, confirmed by subsequent echocardiography, with symptom resolution after puncture. The patient was discharged on the 7th day.

Weekly follow-up showed no recurrence, and the patient remained clinically asymptomatic even after cessation of colchicine.

### **Discussion:**

The main pericardial disease remains pericarditis, which affects all ages [3]. In the absence of myocardial ischemia, pericardial effusion and pericarditis lead to an emergency department visit in 5% of cases [4]. The etiologies of effusion are highly variable, both infectious and non-infectious. When the etiology is undetermined, it is considered idiopathic effusion or pericarditis. While common in high-income countries, it remains rare in Africa, with a percentage of 15% [5] [6] [1]. However, its association with tamponade is rare, especially in young individuals.

Idiopathic pericardial effusion refers to fluid accumulation in the pericardial space without an identifiable underlying cause [4]. Idiopathic or viral pericarditis presents a high risk of recurrence in one-third of patients [5].

Despite advancements in diagnostic modalities, a significant proportion of pericardial effusions remain idiopathic, posing diagnostic dilemmas and therapeutic uncertainties [7]. Our case underscores the importance of a comprehensive diagnostic approach in evaluating pericardial effusions, considering infectious, inflammatory, neoplastic, and autoimmune etiologies, among others.

The clinical presentation of idiopathic pericardial effusion is widely variable, ranging from asymptomatic incidental findings, or dyspnea to life-threatening cardiac tamponade, it depends on the onset of symptoms, size, distribution, and hemodynamic effects [8]. In our

case, the patient presented with acute dyspnea, reflecting the hemodynamic compromise associated with tamponade physiology. The absence of predisposing factors or underlying systemic diseases highlights the cryptogenic nature of the pericardial effusion, necessitating a thorough diagnostic workup to rule out potential etiologies [1] [4] [9].

Diagnostic evaluation of pericardial effusion typically involves a combination of imaging modalities, laboratory tests, and invasive procedures [6]. Eisenberg and al. found that chest radiographs may suggest the diagnosis of pericardial effusion by the presence of a predominant left-sided pleural effusion or a pericardial fat stripe, but do not confirm the diagnosis [10]. Transthoracic echocardiography (TTE) serves as the initial imaging modality of choice for assessing pericardial effusion size, hemodynamic impact, and associated cardiac abnormalities [11]. Our case demonstrated a circumferential large pericardial effusion with echocardiographic signs of tamponade, prompting urgent intervention.

Pericardiocentesis remains the cornerstone of both diagnostic and therapeutic management in cases of cardiac tamponade [3] [1] [2]. Ultrasound-guided pericardiocentesis allows for precise localization of the effusion and reduces procedural complications [12]. Mercé et al. concluded that pericardial drainage procedures have low benefits in terms of diagnosis and therapeutic in patients with large pericardial effusion without tamponade [13]. In our case, pericardiocentesis yielded hemorrhagic fluid, consistent with the hemodynamic instability and tamponade physiology observed clinically.

The management of idiopathic pericardial effusion is primarily empirical, given the lack of specific guidelines and the heterogeneous nature of the condition [8]. The principal goals of the management are releasing symptomatic, preventing recurrence, and avoiding complications. Nonsteroidal anti-inflammatory drugs, colchicine, and corticosteroids are commonly used pharmacological agents to reduce inflammation and prevent reaccumulation of fluid [1] [3] [7] [14] [15]. Our patient received aspirin and colchicine with favorable clinical outcomes, demonstrating the efficacy of this therapeutic approach. In a prospective cohort study including all consecutive cases of idiopathic chronic large pericardial effusions without evidence of pericarditis, Imazio et al. demonstrate that the risk of cardiac tamponade is 2.2% per year and effusion's recurrence, complications survival was better in patients treated conservatively [9].

Long-term follow-up is crucial in patients with idiopathic pericardial effusion to monitor for recurrence, assess treatment response, and detect potential complications [1]. Regular clinical evaluations and serial imaging studies are recommended to ensure ongoing disease surveillance and optimize patient outcomes. Our patient remained asymptomatic during follow-up, suggesting successful management and resolution of the pericardial effusion. Imazio and al. suggest that the evolution of idiopathic chronic large pericardial effusions is usually benign; this is due to the effusion size's reduction in about 40% of cases [9].

### **Conclusion:**

Idiopathic pericardial effusion leading to cardiac tamponade represents a diagnostic and therapeutic challenge in clinical practice. A systematic approach integrating clinical evaluation, imaging studies, and invasive procedures is essential for accurate diagnosis and optimal management. Further research is warranted to elucidate the underlying pathophysiological mechanisms and refine treatment strategies for this enigmatic condition.

### **Ethics approval and consent to participate:**

As per international standards or university standards written ethical approval has been collected and preserved by the author(s).

### **Consent for publication:**

As per international standards or university standards, patient written consent has been collected and preserved by the authors.

### **Availability of data and materials:**

Not applicable.

### **References:**

1. Adler Y, Charron P, Imazio M, et al. 2015 ESC Guidelines for the diagnosis and management of pericardial diseases. *Eur Heart J*. 2015;36(42):2921-2964. doi:10.1093/eurheartj/ehv318
2. Risti AD, Imazio M, Adler Y, et al. Triage strategy for urgent management of cardiac tamponade: a position statement of the European Society of Cardiology Working Group on Myocardial and Pericardial Diseases. *Eur Heart J*. 2014;35(34):2279-2284. doi:10.1093/eurheartj/ehu217
3. Schwier NC, Cornelio CK, Epperson TM. Managing acute and recurrent idiopathic pericarditis. *JAAPA*. 2020;33(1):16-22. doi:10.1097/01.JAA.0000615468.46936.6d
4. Blank N, Lorenz HM. Idiopathic Pericarditis—an Autoinflammatory Disease? *Curr Rheumatol Rep*. 2019;21(5):18. doi:10.1007/s11926-019-0820-2
5. Imazio M, Gaita F, LeWinter M. Evaluation and Treatment of Pericarditis: A Systematic Review. *JAMA*. 2015;314(14):1498. doi:10.1001/jama.2015.12763
6. Lazaros G, Vlachopoulos C, Lazarou E, Tsioufis K. New Approaches to Management of Pericardial Effusions. *Curr Cardiol Rep*. 2021;23(8):106. doi:10.1007/s11886-021-01539-7
7. Lilly LS. Treatment of Acute and Recurrent Idiopathic Pericarditis. *Circulation*. 2013;127(16):1723-1726. doi:10.1161/CIRCULATIONAHA.111.066365
8. Imazio M, Adler Y. Management of pericardial effusion. *Eur Heart J*. 2013;34(16):1186-1197. doi:10.1093/eurheartj/ehs372
9. Imazio M, Lazaros G, Valenti A, et al. Outcomes of idiopathic chronic large pericardial effusion. *Heart*. 2019;105(6):477-481. doi:10.1136/heartjnl-2018-313532
10. Eisenberg MJ, Dunn MM, Kanth N, Gamsu G, Schiller NB. Diagnostic value of chest radiography for pericardial effusion. *J Am Coll Cardiol*. 1993;22(2):588-593. doi:10.1016/0735-1097(93)90069-D

11. Pérez-Casares A, Cesar S, Brunet-Garcia L, Sanchez-de-Toledo J. Echocardiographic Evaluation of Pericardial Effusion and Cardiac Tamponade. *Front Pediatr.* 2017;5:79. doi:10.3389/fped.2017.00079
12. Jung HO. Pericardial Effusion and Pericardiocentesis: Role of Echocardiography. *Korean Circ J.* 2012;42(11):725. doi:10.4070/kcj.2012.42.11.725
13. Mercé J, Sagristà-Sauleda J, Permanyer-Miralda G, Soler-Soler J. Should pericardial drainage be performed routinely in patients who have a large pericardial effusion without tamponade? *Am J Med.* 1998;105(2):106-109. doi:10.1016/S0002-9343(98)00192-2
14. Kim SR, Kim EK, Cho J, et al. Effect of Anti-Inflammatory Drugs on Clinical Outcomes in Patients With Malignant Pericardial Effusion. *J Am Coll Cardiol.* 2020;76(13):1551-1561. doi:10.1016/j.jacc.2020.08.003
15. Shah SR, Alweis R, Shah SA, et al. Effects of colchicine on pericardial diseases: a review of the literature and current evidence. *J Community Hosp Intern Med Perspect.* 2016;6(3):31957. doi:10.3402/jchimp.v6.31957