

**Case report**  
**An intriguing case of Diffuse Sclerosing Variant of Papillary Thyroid Carcinoma: Case report**

**Abstract**

**Aims:** Papillary thyroid carcinoma (PTC) is the most common type of thyroid cancer, representing approximately 80% of all thyroid malignancies. Diffuse sclerosing variant (DSV) accounts for only 2% of all PTC. We present a case of this rare variant in an old lady and subsequently delve into the current understanding of DSV of PTC, drawing insights from various scholarly articles to illuminate its clinical significance, diagnostic challenges, and therapeutic implications.

**Presentation of Case:** A 55-year-old lady presented with swelling in the right side of her neck. On examination, the swelling measured 2.5 x 2.5 cm, firm and moving with deglutition. Ultrasonography confirmed that the bulky right lobe of the thyroid replaced with cysts and nodules, leading to right hemithyroidectomy. Histomorphology confirmed DSV of PTC, following which underwent completion thyroidectomy with node dissection and adjuvant chemotherapy.

**Discussion:** DSV of PTC usually presents in middle-aged to older adults, with a slight female predominance. Being a rare variant, the diagnosis remains a major challenge. It is generally associated with a favourable prognosis, with low lymph node metastasis rates and distant spread. Surgical resection remains the main cornerstone of treatment, with adjuvant therapy reserved for high-risk cases.

**Conclusion:** DSV of PTC represents a rare and distinct variant of thyroid cancer with unique features. A multimodal approach is required for accurate diagnosis and treatment. More research in this field is required to explain the molecular mechanisms driving DSV and also novel therapeutic targets for this rare variant.

**Keywords**

Carcinoma  
Thyroid cancer, papillary  
Thyroid disease  
Thyroid gland  
Thyroid neoplasms  
Thyroid nodule

**1. Introduction**

Papillary thyroid carcinoma (PTC) is the most common type of thyroid cancer, representing approximately 80% of all thyroid malignancies. Within the spectrum of PTC, there exists a rare and distinct variant known as diffuse sclerosing variant (DSV) which accounts for 2% of all PTC(1)Despite its rarity, DSV of PTC presents unique clinical, histopathological, and molecular characteristics that merit attention and further investigation(2)(13)We present a case of this rare variant in an old lady and subsequently delve into the current understanding of DSV of PTC, drawing

insights from various scholarly articles to illuminate its clinical significance, diagnostic challenges, and therapeutic implications.

## **2. Case presentation**

A 55-year-old lady presented with swelling in front of her neck for three years. On examination, the swelling was on the right side of the neck, measuring 2.5 x 2.5 cm. It was firm, rounded and moving with deglutition. She did not have any features of thyrotoxicosis. The haematological and biochemical tests were normal. Her free T3, free T4 and Thyroid stimulating hormone (TSH) were within normal limits. On ultrasonography, the right lobe of the thyroid was bulky (TIRADS 4) and replaced with cysts and nodules. The largest hypoechoic nodule (27x 23 X 22 mm) with wall calcification and punctate echogenic foci was noted at the junction of the isthmus and right lobe. Another 24 X 24 X 21 mm hypoechoic nodule was noted in the right lobe. The enlarged right lobe displaced the trachea to the left. Left lobe was essentially normal with mildly heterogenous echotexture. (Fig.1)

The patient subsequently underwent a right hemithyroidectomy. Intraoperatively, it was noted that the thyroid was bulky, extending behind the oesophagus and was adherent to the surrounding structures including the strap muscles. On gross examination, the right lobe measured 5.5 x 4.5 cm. The cut section was gritty and showed a solid cystic lesion. There were areas of haemorrhage and calcifications.(Fig.2)

The histopathological examination showed an unencapsulated diffusely infiltrating tumour arranged in complex branching papillae with fibrovascular cores. The tumour cells lining the papillae showed nuclear enlargement, elongation and overlapping. The nuclear membranes were irregular and nuclear grooves were identified. There was chromatin clearing and margination. The background had diffuse areas of sclerosis with calcification and formation of psammoma bodies. The focal area showed features of lymphocytic thyroiditis with atrophic thyroid follicles and lymphomononuclear cell infiltrate. Uninvolved thyroid follicles were seen in the periphery which were lined by flattened cuboidal cells. (Fig.3a-d)

A histomorphological diagnosis of diffuse sclerosing variant of papillary thyroid carcinoma was given with a pathological TNM staging pT3a considering the involvement of strap muscles by the tumour.

She was subsequently transferred to a tertiary care centre wherein she underwent completion thyroidectomy with neck node dissection. The post-operative period was uneventful, and she was started on chemotherapy.

## **3. Discussion**

DSV of PTC is a rare and distinct variant existing within the spectrum of PTC. (1)Despite its rarity, DSV of PTC presents unique clinical, histopathological, and molecular characteristics which create numerous problems in the differential diagnosis for the pathologist and have been the subject of much interest. (2)

DSV of PTC typically presents in middle-aged to older adults, with a slight female predominance. Clinically, patients may present with a palpable thyroid nodule or symptoms related to compression of adjacent structures, such as dysphagia or dyspnoea. However, distinguishing DSV from other variants of PTC solely based on clinical presentation is challenging due to its nonspecific symptoms and indolent nature.(3)

Histologically, DSV of PTC is characterized by diffuse sclerosis, which manifests as extensive fibrosis within the thyroid parenchyma. This fibrotic stroma imparts a firm consistency to the tumour, often leading to a misdiagnosis of benign thyroid disease on fine-needle aspiration cytology (FNAC) (4)(5) (12)The presence of classic nuclear features of PTC, including nuclear enlargement, grooves, and pseudoinclusions, is crucial for accurate diagnosis. Additionally, immunohistochemical staining for thyroid-specific markers, such as thyroglobulin and thyroid transcription factor-1 (TTF-1), aids in confirming the thyroid origin of the tumour (11).

Despite the distinct histological features, DSV of PTC shares molecular alterations with conventional PTC, including BRAFV600E mutations, RET/PTC rearrangements, and RAS mutations. However, some studies have suggested a higher prevalence of BRAFV600E mutations in DSV compared to other variants of PTC. The role of these molecular alterations in the pathogenesis and clinical behaviour of DSV warrants further investigation to elucidate potential therapeutic targets and prognostic implications.(6)(7)

The diagnosis of DSV of PTC poses several challenges due to its rarity and overlapping features with other thyroid neoplasms. Differential diagnoses include a nodular sclerosing variant of PTC, sclerosing mucoepidermoid carcinoma with eosinophilia, and a fibrosing variant of Hashimoto thyroiditis. Accurate diagnosis relies on comprehensive histopathological evaluation, including ancillary techniques such as immunohistochemistry and molecular testing. Collaboration between pathologists, radiologists, and clinicians is essential to ensure accurate diagnosis and optimal management of patients with DSV of PTC.

DSV of PTC presents with more advanced clinicopathological features, such as large-volume nodal metastases and lymphovascular invasion, compared to classic PTC and Tall cell PTC. Despite aggressive initial management, nearly half of the patients develop recurrence. However, with successful salvage surgery, disease-specific survival remains excellent. (8,9) However, the impact of extensive fibrosis on disease progression and treatment response remains uncertain. Limited data suggest that DSV may be less responsive to radioactive iodine (RAI) therapy compared to conventional PTC, highlighting the importance of individualized treatment approaches based on the tumour's molecular profile and clinical characteristics. Surgical resection remains the cornerstone of treatment, with adjuvant therapy reserved for high-risk cases. Also, DSV patients share the same recurrence rate compared to high-risk PTC patients. Despite aggressive surgical approaches, the recurrence rate in the first 5 years requires careful ongoing surveillance, similar to the follow-up of high-risk PTC patients.(10)

Despite advancements in the understanding of DSV of PTC, many questions remain unanswered regarding its pathogenesis, optimal diagnostic approach, and therapeutic strategies. Prospective studies with larger cohorts of patients are needed to further delineate the clinical behaviour and molecular underpinnings of DSV. Additionally, the development of targeted therapies directed against specific molecular alterations may offer promising avenues for improving outcomes in patients with DSV of PTC.

#### 4. Conclusion

In conclusion, DSV of PTC represents a rare and distinct variant of thyroid cancer characterized by diffuse sclerosis and unique histopathological features. Although it poses diagnostic challenges due to its rarity and overlapping characteristics with other thyroid neoplasms, a comprehensive approach incorporating histopathological evaluation, immunohistochemistry, and molecular testing is essential for accurate diagnosis and optimal management. Further research is warranted to elucidate the molecular mechanisms driving DSV and identify novel therapeutic targets for this rare variant of PTC.

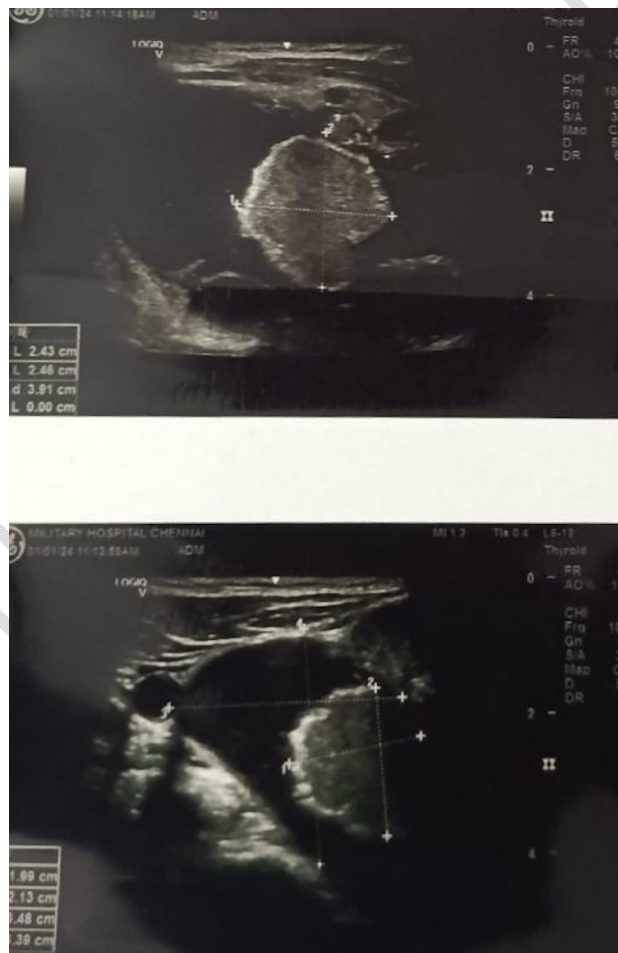

Fig.1 – Ultrasonography of the right lobe thyroid showing a solid and cystic

lesion(TIRADS 4). The hypoechoic nodule with wall calcification and punctate echogenic foci.

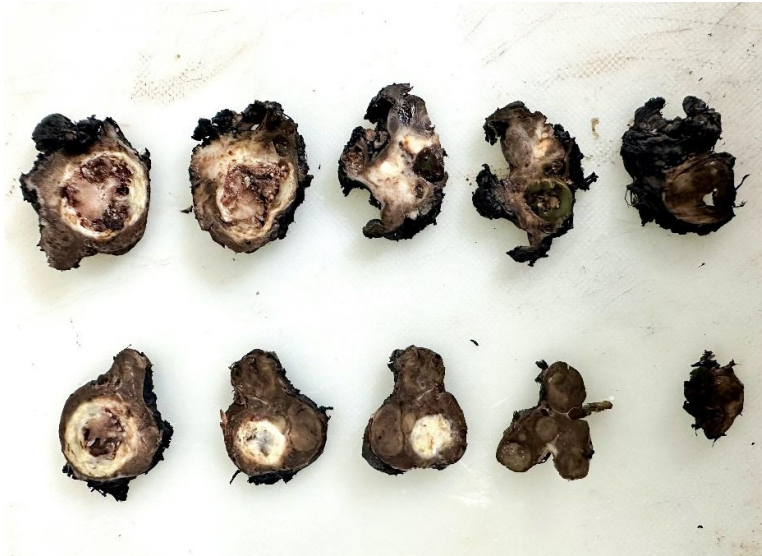

Fig.2 – Serial sections of the right hemithyroidectomy specimen showing an ill circumscribed solid and cystic lesion with areas of necrosis

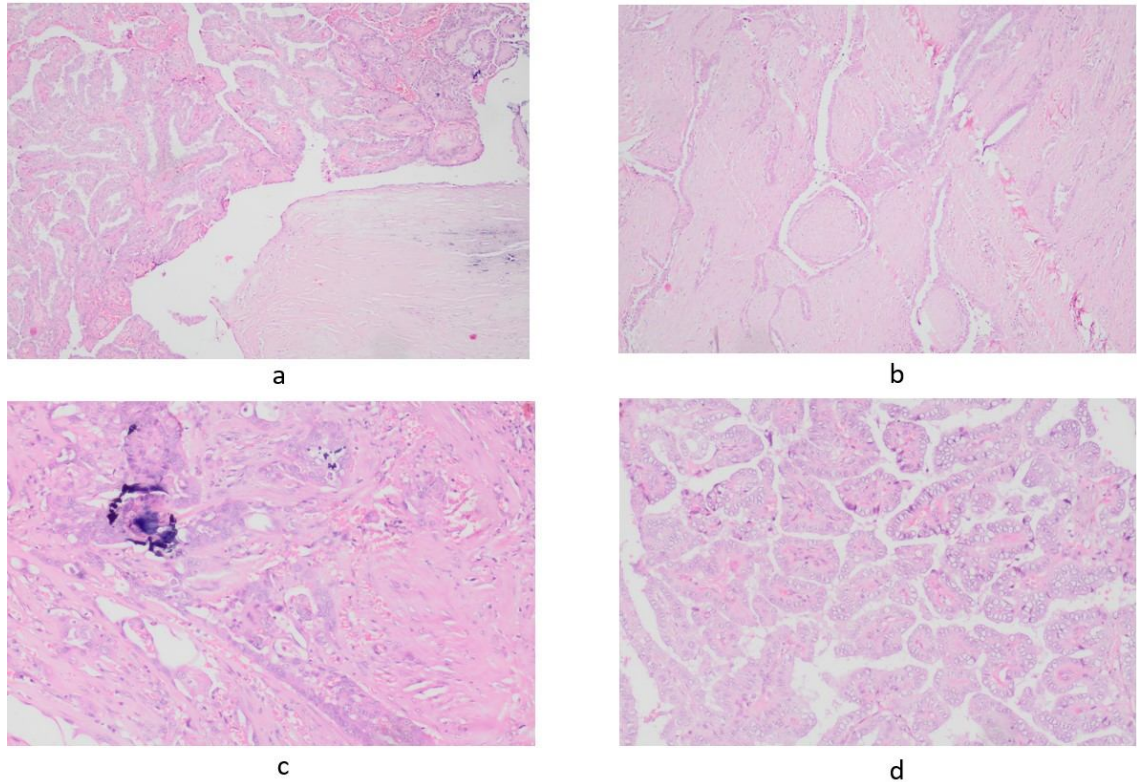


Fig.3a-d – Histomorphological features of the specimen showing Psammoma body (H&E 40X) and papillae lined by cells having classical nuclear features of papillary thyroid carcinoma (H&E 40X)

**Disclaimer (Artificial intelligence) – No AI technologies used during writing or editing of manuscripts.**

Option 1:

Author(s) hereby declare that NO generative AI technologies such as Large Language Models (ChatGPT, COPILOT, etc) and text-to-image generators have been used during writing or editing of manuscripts.

Option 2:

Author(s) hereby declare that generative AI technologies such as Large Language Models, etc have been used during writing or editing of manuscripts. This explanation will include the name, version, model, and source of the generative AI technology and as well as all input prompts provided to the generative AI technology

Details of the AI usage are given below:

- 1.
- 2.

3.

**Ethical Approval - Written informed consent from the patient and approval taken from the ethical committee.**

### **References**

1. Yeh MW, Wu JX. Diffuse Sclerosing Papillary Thyroid Cancer: Excellent Survival Despite Frequent Nodal Metastases. *Ann Surg Oncol*. 2023;30(8):4568.
2. Houas J, Ghammam M, Chouchane L, Abdessaied N, Omri M El, Bellakhdher M, et al. An unusual presentation of diffuse sclerosing variant of papillary thyroid carcinoma. *Egypt J Otolaryngol*. 2022;38(1):10–3.
3. Cavaco D, Martins AF, Cabrera R, Vilar H, Leite V. Diffuse sclerosing variant of papillary thyroid carcinoma: outcomes of 33 cases. *Eur Thyroid J*. 2022;11(1).
4. Takagi N, Hirokawa M, Nobuoka Y, Higuchi M, Kuma S, Miyauchi A. Diffuse sclerosing variant of papillary thyroid carcinoma: A study of fine needle aspiration cytology in 20 patients. *Cytopathology*. 2014;25(3):199–204.
5. Ji YL, Jung HS, Han BK, Eun YK, Seok SK, Ji YK, et al. Diffuse sclerosing variant of papillary carcinoma of the thyroid: Imaging and cytologic findings. *Thyroid*. 2007;17(6):567–73.
6. Pillai S, Gopalan V, Smith RA, Lam AKY. Diffuse sclerosing variant of papillary thyroid carcinoma-an update of its clinicopathological features and molecular biology. *Crit Rev Oncol Hematol*. 2015;94(1):64–73.
7. Thompson LDR, Wieneke JA, Heffess CS. Diffuse sclerosing variant of papillary thyroid carcinoma: A clinicopathologic and immunophenotypic analysis of 22 cases. *Endocr Pathol*. 2005;16(4):331–48.
8. Scholfield DW, Fitzgerald CW et al. Diffuse Sclerosing Papillary Thyroid Carcinoma: Clinicopathological Characteristics and Prognostic Implications Compared with Classic and Tall Cell Papillary Thyroid Cancer. *Ann Surg Oncol*. 2023 Aug;30(8):4761-4770.
9. Simon A Holoubek , Huan Yan et al. Aggressive variants of papillary thyroid microcarcinoma are associated with high-risk features, but not decreased survival. *Surgery*. 2020 Jan;167(1):19-27.
10. Chereau N, Giudicelli X, Pattou F, Lifante JC, Triponez F, Mirallié E, et al. Diffuse sclerosing variant of papillary thyroid carcinoma is associated with aggressive histopathological features and a poor outcome: Results of a large multicentric study. *J Clin Endocrinol Metab*. 2016;101(12):4603–10.
11. Elemam , Ibrahim Bakhit Y., Eman Abd elgadir M. Elshariff, Mohammed Abdelgader Elsheikh, Tiblyan Abd Almajed Altaher, Ghanem Mohammed

- Mahjaf, Waha Ismail Yahia Abdelmula, and Babbiker Mohammed Taher Gorish. 2024. "Immunohistochemical Expression of P63 in Ovarian Tumors Among Sudanese Women". International Research Journal of Oncology 7 (1):14-20. <https://journalirjo.com/index.php/IRJO/article/view/145>.
12. Chow SM, Chan JK, Law SC, Tang DL, Ho CM, Cheung WY, Wong IS, Lau WH. Diffuse sclerosing variant of papillary thyroid carcinoma—clinical features and outcome. European Journal of Surgical Oncology (EJSO). 2003 Jun 1;29(5):446-9.
  13. Pillai S, Gopalan V, Smith RA, Lam AK. Diffuse sclerosing variant of papillary thyroid carcinoma—an update of its clinicopathological features and molecular biology. Critical reviews in oncology/hematology. 2015 Apr 1;94(1):64-73.

UNDER PEER REVIEW