

### Short Research Article

## **IN-VITRO ANTIFUNGAL SUSCEPTIBILITY OF MALASSEZIA DERMATITIS IN DOGS**

### **ABSTRACT**

The present study highlights the comparative antifungal efficacy of Ketoconazole, Itraconazole, and Terbinafine against *Malassezia* spp. and to evaluate the antifungal sensitivity of *Malassezia* species isolated from dermatitis cases in dogs in and around Jabalpur, Madhya Pradesh. A total of 50 skin swabs were collected from dogs with dermatological symptoms suggestive of *Malassezia* spp., out of which 37 swabs were successfully isolated and showed good growth on Sabouraud's Dextrose Agar (SDA) during primary isolation from the skin swabs. Based on *in-vitro* antifungal susceptibility studies, it can be concluded that Ketoconazole, Itraconazole, Fluconazole and Terbinafine were found to be effective against *Malassezia* dermatitis and can be advocated as the drug of choice for the treatment of *Malassezia* dermatitis in dogs.

**Keywords:** dermatitis, *Malassezia* spp. Ketoconazole, Itraconazole, Terbinafine, Fluconazole, dogs

### **1. INTRODUCTION**

Skin problems in dogs are one of the most common and difficult problems encountered by veterinarians in small-animal practice [1]. Dogs are susceptible to various skin problems such as parasitic, fungal, bacterial and viral skin diseases or allergies of various origins. Different factors related to climate that determine the incidence of skin diseases include cold, heat, light, sunshine, and humidity. Several studies from India and abroad have indicated that skin affections make up to 12-75% of the small animal population [2].

*Malassezia* dermatitis is an inflammatory skin condition that affects dogs and is characterized by an overgrowth of the fungus *M. pachydermatison* the skin. This opportunistic pathogen infects the commensal skin in humans and the saprophytic yeast in animals and birds. These fungi are found in the lipid-rich stratum corneum of the skin and vary in size, ranging from 1 to 8 micrometers in diameter. The condition is also known as elephant skin disease and occurs when the protective mechanism

Comment [MF1]: Sample pool is too small

Comment [MF2]: Italics not applied at various places

of the skin is disrupted or the immune system is compromised. Breeds with skin folds are predisposed to *Malassezia* overgrowth. *Malassezia dermatitis* is the most common cutaneous mycotic infection in dogs. This fungus exists in both yeast and mycelial forms, with the mycelial form known as *Malassezia* and the yeast form known as *Pityrosporum*. The genus *Malassezia* belongs to the Phylum *Basidiomycota* and comprises 14 species based on their morphology, biochemical features and molecular analysis [3,4,5,6].

*Malassezia* yeast is known to produce proteolytic enzymes, which can cause damage to the epithelium, leading to the enlargement of ceruminous glands and hyperplasia. This condition often begins in the summer, coinciding with an increase in humidity, and persists throughout the winter. Excessive sebum production, disruption of the epidermal barrier, accumulation of moisture, concurrent dermatitis, atopy, and bacterial skin infections in domestic animals can all promote the proliferation of yeast. *Malassezia dermatitis* can affect animals of any age, breed, or sex [7].

The long-term use of antifungal treatments can cause systemic disturbances, and the increasing resistance of yeast to conventional drugs, the recurrence of the condition, the long duration of treatment, and high treatment costs pose significant challenges for both veterinarians and pet owners. Therefore, it is necessary to develop more economical antifungal agents with minimal side effects to address these challenges. Therefore, the present study aimed to compare the antifungal efficacy of itraconazole and terbinafine against *Malassezia* isolates from dogs with dermatitis.

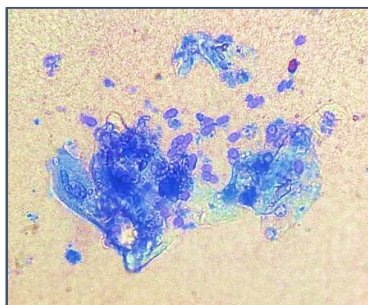
## **2. MATERIALS AND METHODS**

### **2.1. Sample collection**

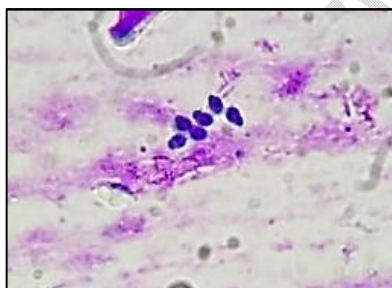
Fifty skin swabs from various lesions were collected from the dogs suspected for malasseziosis based on the clinical signs of pruritus, macule, papule, pustule, alopecia, erythema, rancid odour, scaling, hyperpigmentation and lichenification from the dogs which were brought to the Veterinary Clinical Complex (V.C.C.), Department of Veterinary Medicine, College of Veterinary Science and A.H., N.D.V.S.U., Jabalpur (M.P.).

Sterile cotton swabs moistened with sterile distilled water were used to collect the samples from the suspected dogs. The cotton swab was rolled and rubbed firmly against the entire skin area for 10 seconds from the dogs showing

dermatological problems suggestive of *Malassezia dermatitis*[8]. The swab was then kept in a sterile test tube and stored at -20°C until further laboratory procedure.



**Figure 1. Microscopic examination of acetate tape impression positive for *Malassezia* organism (Methylene blue staining x1000)**



**Figure 2. Microscopic examination of sterile cotton swab smear positive for *Malassezia* organism (Diff-Qik Stain x1000)**

## 2.2. Antifungal agents

Ketoconazole, Itraconazole, Fluconazole and Terbinafine were selected for the present study due to their widespread use in veterinary medicine. Commercial discs are available. Typical concentrations of 10 µg/disc, 25 µg/disc and 50 µg/disc might be used depending on the testing requirements. In the present study, commercially available discs of Ketoconazole (10 µg), Itraconazole (10 µg) and Fluconazole (25 µg) were used whereas for Terbinafine antifungal discs were prepared by the following procedure.

### 2.2.1. Procedure for Preparation of Antifungal Discs

#### A. Materials Required:

1. **Antifungal agents:** Itraconazole/Terbinafine/Ketoconazole/Fluconazole (in tablet or powder form)
2. **Solvent:** Appropriate solvents (e.g., sterile water/ethanol/saline)
3. **Sterile Whatman filter paper discs:** 6 mm in diameter
4. **Sterile forceps**
5. **Sterile petri dishes**
6. **Micropipette and sterile tips**
7. **Laminar flow cabinet**

Comment [MF3]: State in text form

## B. Procedure:

A suspension of the test organism was prepared by the direct colony suspension method. Four distinct and morphologically similar colonies were taken with a sterile cotton swab and transferred into test tubes containing sterile deionized water. After homogenization of the yeast suspension, comparisons were made with the 0.5 McFarland turbidity standards, which is equal to  $1-5 \times 10^6$  CFU/ml [9]. A sterile cotton swab was dipped into the suspension and rotated several times. Excess fluid was removed from the swab by pressing firmly against the inside wall of the tube. The lawn culture was stripped on the SDA plates and the plates were placed in the refrigerator for 2 hours for better absorption of the culture.

### 1. Prepare Stock Solutions

- Weigh an accurate amount of Terbinafine to prepare a stock solution with a known concentration. Dissolve the antifungal powder in an appropriate solvent to make a stock solution. For this, dissolve 250 mg tablet of Terbinafine in 25 ml of saline/distilled water to prepare a 10 mg/ml stock solution.

### 2. Soak Filter Paper Discs

- Place sterile Whatman filter paper discs in a sterile petri dish. Using a micropipette, carefully apply a specific volume of the working solution onto each filter paper disc. For instance, to prepare a 10 µg/disc of Terbinafine concentration, pipette 1 µl of a 10 mg/ml stock solution onto the disc and ensure the solution is evenly distributed across the disc.

### 3. Dry the Discs

- Allow the impregnated discs of Terbinafine and incubated at 37°C overnight and later dried under the laminar airflow. The produced discs have the ability to absorb about 0.01 ml.

#### 4. Store the Discs

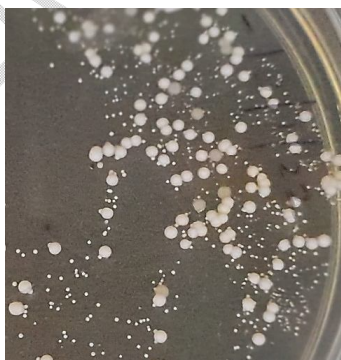- Once dry, store the antifungal discs of Terbinafine in sterile petri dishes or vials at an appropriate temperature (typically 4°C) until use. Ensure that the discs are protected from light and moisture.

#### 5. Label the Discs

- Clearly label each petri-dish or vial with the type of antifungal drug, its concentration and date of preparation.

### 1.3. Isolation and Identification of *Malassezia* yeast

Sterile cotton swabs were used for the collection of samples from dogs which were found positive for *Malassezia* organism. The swabs were inoculated in Sabouraud's Dextrose Agar (SDA). The plates were then incubated at 37°C for 24-72 hours. Colony characters were studied by observing shape, size, colour and consistency of colonies. Identification of species *Malassezia pachydermatis* was based on the macroscopic and microscopic appearance of colonies and its ability to grow on the medium with no lipid supplementation. Pure cultures were preserved at 4°C and the organisms were sub-cultured at two weeks interval [10]. Out of 50 clinical swabs, 37 swabs showed good growth of *Malassezia* organism on SDA.

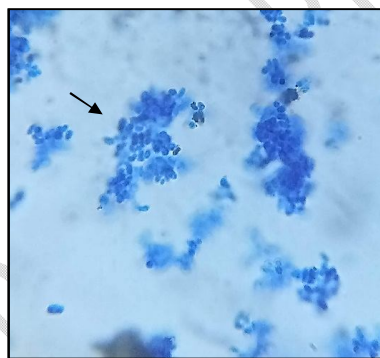


**Figure 3. Colony morphology of *Malassezia* on Sabouraud's Dextrose Agar (SDA) showing smooth, convex, white or creamy coloured colonies**

## 2. RESULTS AND DISCUSSION

Samples collected from dogs with symptoms suggestive of *Malassezia dermatitis* were incubated at 37°C for 7 days on SDA. Growth of *Malassezia* was observed from 4-7 days on SDA. Based on the above results, it can be concluded that SDA is a preferable medium for the isolation of *Malassezia* organism [11]. The colonies of *Malassezia* spp. were macroscopically visible over 3-5 days when incubated at a temperature of 37°C whereas, the growth was weak when incubated at room temperature (25°C). The colonies were raised or high convex and smooth with cream colour initially and later became dry, wrinkled and orange to brown in colour [8].

For microscopic examination, individual colonies were picked up, smeared over clean glass slides stained with Methylene blue solution, air dried and examined under an oil immersion objective (x1000) for the presence of characteristic footprint or peanut shaped organisms (Figure 4).



**Figure 4. Microscopic examination of smear from pure colony showing peanut or footprint shaped blue coloured budding yeasts (Methylene Blue Staining (1000X))**

### **3.1. Antibiogram for *Malassezia* spp. isolates**

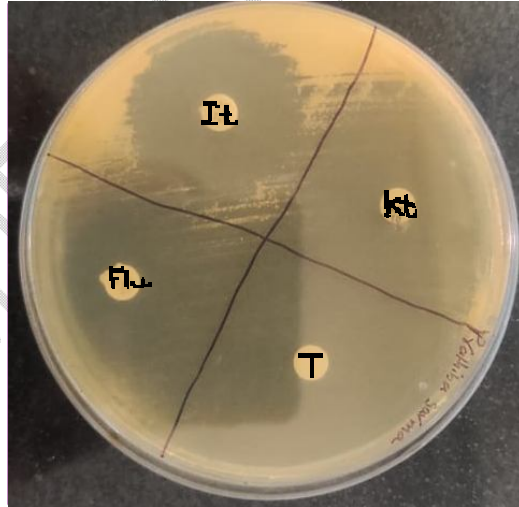
Antifungal susceptibility test was carried out as per the standard disc diffusion method as described by Bauer *et al.* (1966) [11]. Sabouraud's Dextrose Agar (pH 5.6 ± 0.2) was employed for antifungal susceptibility tests. Following antifungal discs with the mentioned concentrations were applied over the plated SDA. Itraconazole (It) 10 µg, Ketoconazole (Kt) 10 µg and Fluconazole (Flu) 25 µg discs were commercially available whereas Terbinafine disc (T) 10 µg was prepared by the procedure of preparation of antifungal discs.

The discs produced were placed at an equal distance from each other over the agar surface and pressed gently to ensure full contact. The antifungal impregnated plates were incubated in the inverted position at 37°C for 48 hrs. The diameter of the bacterial inhibition zone around each applied disc was measured. The interpretation of zone of diameter was carried out according to the standards laid down by Clinical Laboratory Standards Institute (CLSI), formerly known as National Committee for Clinical Laboratory Standards (NCCLS). The diameter of zone of inhibition was translated into sensitive or resistance.

Details of the antifungal susceptibility test of *M. pachydermatis* to antifungal drugs are presented in Table 1.

**Table 1. In-vitro antifungal sensitivity pattern of *Malassezia pachydermatis***

S.no.	Name of the antifungal disc	Zone of inhibition
1.	Ketoconazole	33 mm, 37 mm
2.	Itraconazole	26 mm, 28 mm
3.	Terbinafine	38 mm, 40 mm
3.	Fluconazole	23 mm, 28 mm



**Plate 1. Antifungal sensitivity pattern against *Malassezia* spp.: Zone of inhibition of standard antifungal agents i.e. Terbinafine (T), Ketoconazole (Kt), Itraconazole (It) and Fluconazole (Flu)**

Among the different antifungal agents, the zone of inhibition was highest in Terbinafine (T) followed by Ketoconazole (Kt), Itraconazole (It) and Fluconazole (Flu)

Comment [MF4]: Radius scale not -present

respectively as shown in Table 1 and Plate 1. These findings are in agreement with (Kumaret al., 2011; Seetha et al., 2018; Sihelskaet al., 2019) [8,13,14] who reported that the *Malassezia pachydermatis* isolates showed sensitivity to Ketoconazole, Fluconazole and Itraconazole.

Ketoconazole, Fluconazole and Itraconazole (Imidazoles and triazoles) inhibit the cytochrome P-450 enzyme lanosterol 14 alpha demethylase, preventing the demethylation of lanosterol to ergosterol and thus inhibiting the synthesis of ergosterol, the main sterol in fungal cell membranes. It also leads to complete disappearance of oxidative enzymes in the fungal cell membranes. It also leads to complete disappearance of oxidative enzymes in the fungal cells resulting in intracellular accumulation of toxic levels of hydrogen peroxide. By preventing the synthesis of ergosterol, the agents alter the cell's permeability, resulting in its death [8]. As Ketoconazole can be effective in treating fungal infections, its potential for serious side effects necessitates careful consideration and monitoring. Alternative antifungal agents with better safety profiles are often preferred, especially for long-term use.

Terbinafine is an allylamine antifungal drug. It acts as an inhibitor of enzyme squalene epoxidase. It inhibits the conversion of squalene-to-squalene epoxide and decrease the synthesis of ergosterol. Due to excessive intracellular accumulation of squalene, fungal cell death occurs due to disruption of cell membrane [15].Terbinafine has a high safety margin in humans [16]. It has no inhibitory effect on cytochrome P450 systems therefore, it is considered to be more selective thanazole derivatives such as Ketoconazole.

In the present study, none of the isolates were found resistant to antifungal drugs. All the isolates were susceptible to Ketoconazole, Itraconazole, Fluconazole and Terbinafine. A cent percent sensitivity recorded in this study indicated that any of the above drugs can be suggested for the treatment of *Malassezia pachydermatis* dermatitis in dogs.

Nowadays resistant strains of *Malassezia* yeasts are increasingly detected. Resistance to antifungal drugs in clinical cases for *Malassezia* species is sometimes reported in both human and veterinary medicine. Most studies have shown little evidence for *in-vitro* antifungal resistance, multiple reports have

demonstrated occasional very high anti-fungal MICs in individual *Malassezia* species and strains [17].

### 3.2. Clinical Implications

The results of the present study suggest that Terbinafine was found to be most effective than as compared to Ketoconazole, Itraconazole and Fluconazole against *Malassezia* dermatitis in dogs, based on *in vitro* susceptibility tests. This finding is significant for veterinary practitioners seeking the most efficacious treatment for canines. Thus, they may consider Terbinafine as a first-line treatment option, especially in cases resistant to Ketoconazole and Itraconazole. However, individual variability in response to Terbinafine and Ketoconazole necessitates careful selection and monitoring. Routine antifungal susceptibility testing can guide veterinarians in choosing the most appropriate antifungal therapy, thereby improving clinical outcomes and minimizing the risk of treatment failure.

### 3.3. Future Research

Further clinical trials are required to validate these findings *in vivo*. Investigations into the pharmacokinetics, safety profiles, and long-term efficacy of Itraconazole and Terbinafine in dogs with *Malassezia* dermatitis are essential for developing comprehensive treatment guidelines.

Comment [MF5]: Discussion not present

## 4. CONCLUSION

Terbinafine exhibits superior antifungal activity against *Malassezia pachydermatis* compared to Itraconazole, Fluconazole and Ketoconazole suggesting that it may be a more effective treatment option for *Malassezia* dermatitis in dogs. These findings support the need for further clinical research to optimize the treatment protocols in veterinary dermatology.

## REFERENCES

1. Scott DW, Miller WH, Griffin CE. *Malassezia* dermatitis. In: Muller and Kirk's Small Animal Dermatology, 6th Edn., W.B. Saunders, Philadelphia, USA. 2001; pp 363-374.
2. Sarma K, Mondal DB, Sarvanan M, Kumar M, Vijaykumar H. Incidence of dermatological disorders and its therapeutic management in canines. *IntasPolivet*. 2013; 14: 186-192.

3. Chen T, Hill PB. The biology of *Malassezia* organisms and their ability to induce immune responses and skin disease. *Veterinary Dermatology*.2005;**16**: 4-26.
4. Selvi D, Kshama MA, Ramesh PT. Diagnosis and therapeutic management of elephant skin disease in a geriatric pet with itraconazole pulse therapy. *International Journal of Veterinary Sciences and Animal Husbandry*.2023; 8(5): 130-133.
5. Bond R, Patterson-KaneJC, Lloyd DH. Intradermal test reactivity to*Malassezia pachydermatis*in healthy basset hounds and basset hounds with*Malassezia dermatitis*. *Veterinary Record*. 2002; 151: 105-109.
6. Bond R, Morris DO, Guillot J, Bensignor EJ, Robson D, Mason KV, Kano R, Hill PB. Biology, diagnosis and treatment of *Malassezia* dermatitis in dogs and cats: Clinical Consensus Guidelines of the World Association for Veterinary Dermatology. *Veterinary Dermatology*. 2020; 31: 28–74.
7. Nardoni S, Corazza M, Mancianti F. Diagnostic and clinical features of animal malasseziosis. *Parasitology*. 2008; 4: 227-229.
8. SeethaU, KumarS, Pillai RM, SrinivasMV, AntonyPX, MukhopadhyayHK.*Malassezia* species associated with dermatitis in dogs and their antifungal susceptibility. *International Journal of Current Microbiology and Applied Sciences*. 2018; 7(6): 1994-2007.
9. Yurayart C, Nuchnoul N, Moolkum P, Jirasuksiri S, Niyantham W, Chindamporn A, Kajiwar S, Prapasarakul N. Antifungal agent susceptibilities and interpretation of *M. pachydermatis* and *C. parapsilosis* isolated from dogs with and without seborrhoeic dermatitis skin. 2013; 51(7): 485-493.
10. Valle R. Clinico-diagnostic and therapeutic studies on *Malassezia* dermatitis in dogs. M.V.Sc. thesis (Veterinary Medicine), Sri Venkateswara Veterinary University. 2014; Tirupati.
11. Cafarchia C, Gasser RB, Luciana A, Latrofa MS, Otranto D. Advances in the identification of *Malassezia*, Molecular and Cellular Probes. 2011; 30: 1 – 7.
12. Bauer AW, Kirby WMM, Sherris JC, Turck M. Antibiotic susceptibility testing by a standardized single disc method, *American Journal of Clinical Pathology*. 1966; 45: 493 – 496.
13. Kumar KS, Selvaraj P, Vairamuthu S, Nagarajan B, Nambi AP, Prathaban S. Survey of fungal isolates from canine mycotic dermatitis in Chennai. *Tamil Nadu Journal of Veterinary & Animal Sciences*. 2011; 7(1): 48-50.
14. Sihelska Z, Conkova E, Vaczi P, Harcarova M, Bohmova E. Occurrence of *Malassezia* yeast in dermatologically diseased dogs. *Folia Veterinaria*. 2017; 61(2): 17-21.
15. Lipner SR, Scher RK. Onychomycosis: Treatment and prevention of recurrence. *Journal of the American Academy of Dermatology*. 2019; 80(4): 853-867.
16. McClellanKJ, WisemanLR, MarkhamA. An update of its use in superficial mycoses. *Drugs*. 1999; **58**(1): 179–202.

17. RobsonD, MossS, TrottD, BurtonG, BasettR. Evidence for possible clinically relevant antifungal resistance in *Malassezia pachydermatis*: 10 cases, Dermatology chapter of the AVC Science Week Proceedings. 2010; 2 – 3 July.

UNDER PEER REVIEW