

The Effect of *Cecropia glaziovii* gel on the healing process: influence on the balance between cytokines and growth factors

Abstract:

The physiological regulation of wound healing depends on an interaction between different cells and mediators. *Cecropia glaziovii* is considered a model for the development of phytomedicines for health use due to its pharmacological activities attributed to the presence of flavonoids, procyanidins, catechins, and glycosides. Therefore, the aim of the study was to analyze the anti-inflammatory effects of *Cecropia glaziovii* gel on the healing of skin lesions in an experimental model. For this purpose, a 3% CMC gel incorporated with the 5% aqueous extract of *Cecropia glaziovii* was developed. The experimental stage was performed using a dorsal punch model. The sample was composed of 48 *Wistar* rats, divided into two groups: PC, treated only with base gel, and CEC *Cecropia*, treated with *Cecropia glaziovii* gel. The groups were subdivided into 3, 7, 14, and 21 days of treatment. We performed VEGF- α and TGF- β 1 analyses by immunohistochemistry, IL-10 and IL-12 analyses by flow cytometry, total collagen analysis by polarized light microscopy, macroscopic, and statistical analysis. The treatment provided anti-inflammatory activity acting on the balance of cytokines production and growth factors, stimulating the collagen deposition necessary for the effectiveness of the healing process.

Keywords: *Cecropia glaziovii*, wound healing, VEGF- α , TGF- β 1, IL-10, IL-12.

Introduction

Wound healing is a multifaceted process that occurs in sequential and overlapping phases: hemostasis, inflammation, proliferation, and remodeling (Wang et al., 2017). The physiological regulation is complex and depends on an interaction between different cells and mediators (Sorg et al., 2016). The balance between leukocyte action, growth factors, secretion of cytokines and chemokines are determining factors in all phases of healing (Pristo and Dias, 2012; Sorg et al., 2017).

The purpose of healing is to form a functional tissue structurally similar to that of intact skin (Laureano and Rodrigues, 2011), however, the

exacerbation of the inflammatory response is a factor that can interfere negatively in the healing process (Pristo and Dias, 2012; Sorg et al., 2017). Failure in this process and prolonged healing time increase the costs for healthcare (Vitale et al., 2022; Young and McNaught, 2011). So, effective wound treatment is a challenge for human health, due to improper treatment of wounds may result in bleeding, infection, inflammation and scarring (Sharifi et al., 2021; Ghomi et al., 2022)

In this context, medicinal plants play an important role in wound treatment. Several plants containing substances with immunoregulatory activity and antiinflammatory properties (Das et al., 2016). The genus *Cecropia* (*Urticaceae*), a tree native to Central and South America that consists of 70-80 species, is commonly used in traditional medicine with a wide range of therapeutic applications, including diabetes, hypertension, asthma, anxiety, and inflammation (Rivera-Mondragón et al., 2017).

The species *Cecropia glaziovii*, popularly known as "embaúba-vermelha" or "árvore-da-preguiça" is traditionally used in Latin American folk medicine. It was considered a model for the development of phytomedicines for public health by the Brazilian Health Ministry between 1984 and 1998 (Muller et al., 2016; Tanae et al., 2017). Its pharmacological activities can be attributed to the flavonoids, procyanidins, catechins, and glycosides of its composition. An important anti-inflammatory activity of this species comes in part due to the presence of chlorogenic acid and C-glycosylflavonoids (Stange et al., 2009; Muller et al., 2016; Souccar et al., 2008).

In addition, the use of topical formulations such as gels can assist in the healing process. The gel-forming polymers are able to keep the lesion site hydrated. Additionally, several substances can be incorporated into them, such as the *Cecropia glaziovii* extract (Bini et al., 2021).

For these reasons, the aim of the study was to analyze the antiinflammatory effects of *Cecropia glaziovii* gel on the healing of skin lesions in an experimental model.

Methodology

Obtaining Cecropia glaziovii

The leaves of *Cecropia glaziovii* were collected in Florianópolis, SC, Brazil and identified by Professor Dr. Daniel Falkenberg (UFSC). The material was deposited in the Herbarium of the Federal University of Santa Catarina under registration FLOR 37143.

After collection, the dried leaves were placed in a circulating air oven (3540° C) for three days, they were ground in a knife mill and then stored in a closed container protected from light until the extraction process was carried out (Costa et al., 2011).

The sample of *Cecropia glaziovii* extract, rich in antioxidants, was obtained in partnership with Professor Dr. Flávio Henrique Reginatto from the Study Group on Natural and Synthetic Products (GEPRONAS) at the Federal University of Santa Catarina (UFSC) and is available at the Laboratory of Biopharmaceutical Technology and Analysis at UNICENTRO.

Extract and polymer characterization - spectrophotometry in the UV/VIS region

For characterization of the extract in solution, it was submitted to spectrophotometry in the ultraviolet and visible region (UV/Vis, between 200 and 800 nm) in a spectrophotometer (Cary 100, Agilent). The graph of absorbance vs wavelength was prepared, which serves as a basis for evaluating the extract after incorporation into Cecropia 5% aqueous formulation.

An absorbance peak of 0.990 at a wavelength of 272 nm can be observed.

At the LED wavelength of 627 nm, there was no variation in absorbance, not interfering in the group associated with the gel with the application of LED.

Base-gel formulations

In the study of the gel formulation, it was first evaluated to obtain the base gel, i.e., the gel formation without incorporation of the extracts.

The gel-forming polymer (0.05-20%; w/v) was incorporated into ultrapure water slowly under mechanical stirring.

The polymers carboxymethyl cellulose (CMC) and hydroxypropyl methyl cellulose (HPMC) (K4M) and HPMC (K15M) were used to formulate the base gel. A stirrer "Fistom, model 715, 60 HZ" was used to prepare the polymers.

Distilled water was stirred for 1 minute and the polymers were added gradually at a speed of 500 rpm. After the end of polymer addition, the speed was increased to 850 rpm and maintained for 1 minute, then to 1000 rpm and maintained for another minute. After stirring the gel conformation was observed. The formulation, prepared in triplicate, was kept at rest for 12 hours for complete gelation.

The preservative solution was composed of 0.6g of methylparaben, 0.3g of propylparaben and 9.1ml of propylene glycol, in a suitable container, under stirring, 0.05g of EDTA (chelating agent) was still added to the formulation and then the components were heated until complete solubilization and stored in amber glass containers, protected from light and at room temperature (FORMULÁRIO NACIONAL DA FARMACOPÉIA BRASILEIRA, 2012).

Gel formulation containing C. glaziovii extract

After a resting period of 12 hours, the 5% Cecropia glaziovii extract was incorporated, previously solubilized in water q.s.p. according to the formula shown in table 1.

The components were incorporated into a suitable container under stirring until completely solubilized. Stored in amber glass sheltered from light and at room temperature.

Figure 2 demonstrates the final appearance of the gel formulation containing Cecropia glaziovii.

In vivo study

The experimental induced, randomized research was developed in the Laboratory of Neuroanatomy and Neurophysiology of the Physiotherapy Department of the Midwestern Parana State University - Guarapuava - Paraná, Brazil, after approval by the Ethics Committee on Animal Use of UNICENTRO by the Official Letter N^o. 022/2019 - CEUA/UNICENTRO.

48 female *Rattus Norvegicus*, Wistar lineage, were used. They were provided by the State University of Londrina - UEL, and weighed between 200 and 250 grams. They were allocated in acrylic cages in groups of 3 animals per cage, received food (Nuvital® Nuvilab CR-1) and water, 12hs light/dark cycle, and room temperature of 23 ± 1 °C, following the guidelines of Federal Law No.

6638 and the recommendations of the Brazilian College of Animal Experimentation.

Experimental groups

Experimental test

The animals were previously anesthetized with 80 mg/Kg of Ketamine Hydrochloride and 15 mg/Kg of Xylazine Hydrochloride. After verifying the anesthetic state of the animals by the manual compression test of the tail lower third, the posterior front part of the animals was trichotomized and cleaned with 70% ethanol. Subsequently, the animals received a sterile, 8-mm *punch* that triggered the tissue injury (Bini et al., 2021).

After this surgical procedure, the treatment protocol was performed daily, always maintaining the same time and sequence of groups for application of the protocol.

Application of the gels

The gels were applied using the tip of a stainless steel spatula containing approximately 24 mg of sample. The sample was applied as a layer.

In the positive control group the application of a base gel containing only the gel-forming polymer was performed, and in the *Cecropia glaziovii* group the application of the gel containing the extract of *Cecropia glaziovii*.

Euthanasia

In the periods following the treatments, the animals were anesthetized with 80mg/kg of Ketamine and 15mg/kg of Xylazine. After verifying the anesthetic state, they received a lethal dose of 1ml of Pentobarbital intraperitoneally. This is the recommended method for euthanasia for rodents and other small mammals, present in Resolution 714 of the Federal Council of Veterinary Medicine of June 20, 2002.

Analysis of total collagen using polarized light microscopy

After verifying the animal's death *status* by the whitish coloration of the eyes, lack of spontaneous breathing, and lack of pain reflex, we removed the skin where the scarring process was located utilizing a pair of surgical scissors. After the removal, the specimens were immersed in 10% formalin for 24 hours to maintain morphological characteristics. Subsequently, the specimens were sent for pathological analysis with markers provided by the researcher. The specimens were cut again, divided into two parts, and immersed in paraffin for

histological sections 2µm thick with microtome, from the medial region to the edges. Three histological sections were performed in each specimen for each analysis.

The sections were stained with *Picrosirius green* for collagen verification. Image capture was performed in the Experimental Pathology Laboratory of the Pontifical Catholic University of Paraná (PUCPR), using polarized light microscopy, capture program AxioVs 40x64 V 4.9.1.0 and image analysis program Image-Pro® Plus, The Proven Solution, version 4.5.0.29 for Windows 98/NT/2000. Readings were used in a 40 (400x) objective.

Immunohistochemical analysis (IHC)

The preparation of slides and analysis of the samples by immunohistochemistry was performed at the Laboratory of Tumor Biology, UNIOESTE-PR, under the responsibility of Dr. Carolina Panis.

Samples were fixed in formalin, embedded in paraffin and immunostained with primary antibodies against VEGF-α and TGF-β1 for subsequent microscopic identification based on stained areas and intensity (Panis et al., 2011).

Flow Cytometry

For flow cytometry a portion of tissue lesion from each animal was removed. This content was arranged in 1.5 ml microtubes, kept at rest for 15 minutes, then centrifuged at 3900 RPM for 6 minutes. After centrifugation, the supernatant was separated for further use.

We utilized the Cytometric Bead Array (CBA) - Mouse Inflammation Kit (lot 8114791) for the detection of MCP-1, IL-10, and IL-12p70, following the manufacturer's guidelines. Initially, a serial dilution with tissue lavage was performed, with the mixture containing an equal proportion of the specific *beads* for each cytokine and with the detection reagent. After 2 hours of incubation in the dark, 1 ml of PBS was added and centrifuged at 200g for 5 minutes. Then, the supernatant was discarded and resuspended in 300µl of water. The analysis of the Flow Cytometry samples was performed at the Virology Laboratory of the Carlos Chagas Institute, FIOCRUZ-PARANÁ, under the responsibility of Dr. Guilherme Silveira, using the BD FACSCanto II equipment and FCap Array software v3. The results were allocated in graphs, showing the means and standard deviation.

Macroscopic Analysis

For the evaluation of wound size, all the animals were photographed daily with the aid of a Fujifilm digital camera, Finepix Z, 10.0 Megapixels, without zoom approach at a distance of 20 cm, on a tripod. The images of the wounds were transferred to the computer, where the lesion size area was measured with the software ImageJ®. After quantifying the size of the lesions, the data were arranged and statistically analyzed.

Statistical analysis.

The data were analyzed by the software GraphPad 5®. For non-parametric group analysis we utilized the Kruskal-Wallis test with Dunn's post-test. As for parametric analysis we utilized ANOVA and Tukey's test, with significance level for $p < 0.05$.

Results

Immunohistochemical analysis

Figure 3 shows the immunohistochemical sections with the primary antiVEGF- α and anti-TGF- β 1 antibodies, with microscopic approximation of 100x, representing the PC and CEC groups, subdivided into 3, 7, 14, and 21 days.

Figure 4 shows the mean values for quantitative analysis of Vascular Endothelial Growth Factor Alpha (VEGF- α) and Transforming Growth Factor Beta 1 (TGF- β 1) of the PC and CEC groups at 3, 7, 14, and 21 days of treatment.

In figures 3 and 4, which show the sections with immunohistochemical staining and the mean values for quantitative analysis of VEGF- α and TGF- β 1, respectively, it is possible to observe that the CEC group presented higher amounts of VEGF- α in the first 3 days of treatment, followed by lower amounts in the subsequent days. In relation to TGF- β 1, the CEC group presented higher values in the first 2 days, followed by a decrease on the fourteenth day and on the twenty-first, this value was higher than the PC group again.

Flow cytometry

Figure 5 presents the mean values and standard deviation for quantitative analysis of IL-10 and IL-12p70 in the PC and CEC groups at 3, 7, 14, and 21 days of treatment.

In the analysis of IL-10, it is possible to observe that the CEC group presented higher values in the first 7 days, after that, higher values were observed in the PC group until the twenty-first day. Regarding IL-12, higher values were observed in the CEC group at 3, 7, and 21 days of treatment.

Collagen analysis by polarized light microscopy

The birefringence shows immature collagen in greenish coloration and mature collagen in reddish coloration.

Figure 6 presents the analysis by polarized light through *Picrosirius Green* staining for quantification of immature and mature collagen present in the region of the lesion in all groups at 3, 7, 14, and 21 days.

As immature collagen can be seen in green and mature collagen in red, it is possible to see that mature collagen was more pronounced in the CEC groups, while in the PC groups there was a greater presence of immature collagen, with a greater presence of mature collagen only on the last day of treatment.

Figure 7 presents the photos of the lesions in the PC and CEC groups at the day of the lesion and at 3, 7, 14, and 21 days of treatment.

In the images it can be seen that in the CEC group, the lesions were smaller from the third day of treatment, with complete healing of the wound on the last day of treatment, while in the PC group, the wound was not yet completely healed on the twenty-first day.

Discussion

It was demonstrated for the first time in this study that *Cecropia glaziovii* gel exhibits anti-inflammatory activity on skin lesion in rats and stimulates collagen deposition necessary for the healing process.

The *Cecropia glaziovii* has ethnopharmacological importance due to the metabolites present in the species, mainly due to the presence of chlorogenic acid and the C-glycosylflavonoids (Stange et al., 2009; Muller et al., 2016; Souccar et al., 2008).

In this study, the immunohistochemical analysis of pro-angiogenic molecules (VEGF- α and TGF- β 1), showed higher expression of VEGF- α in the first 3 days of treatment in the CEC group, as well as TGF- β 1. However, TGF- β 1 increased again on the twenty-first day. These growth factors are focal regulators of the healing process. They are released by a variety of activated cells at the site of injury and stimulate cell proliferation and chemoattraction of new cells to the site (Sorg et al., 2017).

During inflammation, activated macrophages increase the production of VEGF- α and this molecule is believed to play a central role in angiogenic processes and is an important factor for endothelial cell migration, necessary for physiological processes such as wound healing (Arjamaa et al., 2017; Lu et al., 2019). As for the TGF- β 1, it is a pro-migratory and pro-fibrotic growth factor that directly stimulates collagen synthesis and decreases ECM degradation by fibroblasts (Sorg et al., 2017).

Thus, we can believe that the increase of VEGF- α in the first days contributed to the formation of new vessels, stimulating cell migration and greater efficiency of the inflammatory process necessary for damage repair already at the beginning, as well as the increase of TGF- β 1 in the first days. The higher expression of TGF- β 1 on the last day is possibly due to collagen synthesis, characteristic of the final stages of healing.

Regarding the analysis of IL-10 and IL-12 by flow cytometry, we can notice that the CEC group showed higher values of IL-10 in the first 7 days, after which, higher values were observed in the PC group until the twenty-first day. Regarding IL-12, higher values were observed in the CEC group at 3, 7, and 21 days of treatment.

Acute inflammation plays a beneficial role against infection and injury, contributing to wound healing, while chronic inflammation delays and hinders the healing process. Parallel to the acute phase of inflammation resolution and restoration of tissue homeostasis, lipid mediators are produced, highly associated with anti-inflammatory and immunomodulatory properties, which

include inhibition of leukocyte chemotaxis, while inducing increased IL-10 expression (Cymrot et al., 2004; Nesi-reis et al., 2018). This fact was verified in this study in the CEC group, where there was a higher expression of both IL-12 (proinflammatory) and IL-10 (anti-inflammatory) in the first days of treatment, followed by a reduction of these levels until the end of treatment, indicating that the inflammatory process was better controlled in the group that received treatment, contributing to a more efficient healing process.

As for the analysis of collagen, the most abundant protein found in the body and one of the main components of the extracellular matrix, which, in addition to providing tensile strength and structural support to the skin and other tissues, can also act as a signaling molecule in the regulation of all phases of healing, playing an important role in each of them (Kallis and Friedman, 2018), in which fibroblasts are responsible for the production and deposition of a large amount of type III collagen (immature), which subsequently undergoes the process of maturation, with remodeling and replacement of type III collagen fibers by type I collagen fibers (mature). It was observed that both collagen type I and type II were more present in the CEC group at all stages demonstrated. Still, this same group presented collagen type I in a more accentuated form, being a good indication of the efficiency of the healing process, which can be confirmed by the macroscopic analysis (figure 7), which provides images of the lesion status at all stages of healing/treatment, showing that the treatment with *Cecropia glaziovii* gel provided faster healing compared to the group that was treated only with the base gel.

Conclusion

It was demonstrated for the first time that *Cecropia glaziovii* gel presents anti-inflammatory activity on skin lesions, acting directly on the balance of cytokine and growth factor production (IL-10, IL-12, VEGF- α and TGF- β 1), thus stimulating the collagen deposition necessary for the effectiveness of the healing process.

Declarations

Ethical Approval

The experiments were conducted in accordance with the approval by the Ethics Committee on Animal Use of UNICENTRO by the Official Letter N^o. 022/2019 - CEUA/UNICENTRO.

Availability of data and materials

Data can be requested from the corresponding author.

References

Arjamaa, O., Aaltonen, V., Piippo, N., Csont, T., Petrovski, G., Kaarniranta, K., & Kauppinen, A. (2017). Hypoxia and inflammation in the release of VEGF and interleukins from human retinal pigment epithelial cells. *Graefes Arch Clin Exp Ophthalmol*, 255(9), 1757-1762. 10.1007/s00417-017-3711-0

Bini, A.C.D. et al. (2021) Healing Activity of *Ilex paraguariensis* in an Experimental Cicatrization Model. *Res. J. Pharm., Biol. Chem*,12(3) 63-64, 2021. 10.33887/rjpbcs/2021.12.3.8

Costa, G. M., Ortmann, C. F., Schenkel, E. P., & Reginatto, F. H. (2011). An HPLC-DAD method to quantification of main phenolic compounds from leaves of *Cecropia* species. *J. Braz. Chem. Soc.*, 22, 1096-1102. 10.1590/S0103-50532011000600014

Cymrot, M., Percário, S., & Ferreira, L. M. (2004). Comportamento do estresse oxidativo e da capacidade antioxidante total em ratos submetidos a retalhos cutâneos isquêmicos. *Acta Cir Bras*, 19, 18-26. 10.1590/S0102-86502004000100003

Das, U., Behera, S. S., Singh, S., Rizvi, S. I., & Singh, A. K. (2016). Progress in the development and applicability of potential medicinal plant extract-conjugated polymeric constructs for wound healing and tissue regeneration. *Phytotherapy research*, 30(12), 1895-1904. 10.1002/ptr.5700

Formulário Nacional da Farmacopeia Brasileira. Brasil. Ministério da Saúde. Agência Nacional de Vigilância Sanitária. 2.ed. Brasília: Anvisa, 2012.

Ghomi, E. R., Shakiba, M., Ardahaei, A. S., Kenari, M. A., Faraji, M., Ataei, S., Kohansal, P., Jafari, I., Abdouss, M., & Ramakrishna, S. (2022). Innovations in Drug Delivery for Chronic Wound Healing. *Current pharmaceutical design*, 28(5), 340–351. <https://doi.org/10.2174/1381612827666210714102304>

Kallis, P. J., & Friedman, A. J. (2018). Collagen powder in wound healing. *J Drugs Dermatol: JDD*, 17(4), 403-408.

Laureano, A., & Rodrigues, A. M. (2011). Cicatrização de feridas. *Port J Dermatol Venereol.*, 69(3), 355-355. 10.29021/spdv.69.3.71

Lu, E., Li, C., Wang, J., & Zhang, C. (2019). Inflammation and angiogenesis in the corpus luteum. *J. Obstet. Gynaecol. Res*, 45(10), 1967-1974. 10.1111/jog.14076

Mueller, S. D., Florentino, D., Ortmann, C. F., Martins, F. A., Danielski, L. G., Michels, M., ... & Reginatto, F. H. (2016). Anti-inflammatory and antioxidant activities of aqueous extract of *Cecropia glaziovii* leaves. *J. Ethnopharmacol.*, 185, 255-262. 10.1016/j.jep.2016.03.00

Nesi-Reis, V., Lera-Nonose, D. S. S. L., Oyama, J., Silva-Lalucci, M. P. P., Demarchi, I. G., Aristides, S. M. A., ... & Lonardoní, M. V. C. (2018). Contribution of photodynamic therapy in wound healing: A systematic review. *Photodiagnosis Photodyn Ther.*, 21, 294-305. 10.1016/j.pdpdt.2017.12.015

Panis, C., Mazzuco, T. L., Costa, C. Z. F., Victorino, V. J., Tatakihara, V. L. H., Yamauchi, L. M., ... & Pinge-Filho, P. (2011). Trypanosomacruzi: effect of the absence of 5-lipoxygenase (5-LO)-derived leukotrienes on levels of cytokines, nitric oxide and iNOS expression in cardiac tissue in the acute phase of infection in mice. *Exp. Parasitol.*, 127(1), 58-65. 10.1016/j.exppara.2010.06.030

Pristo, I. (2012). Cicatrização de feridas: fases e fatores de influência. *Acta Vet. Bras.*, 6(4), 267-271. 10.21708/avb.2012.6.4.2959

Rivera-Mondragón, A., Ortíz, O. O., Bijttebier, S., Vlietinck, A., Apers, S., Pieters, L., & Caballero-George, C. (2017). Selection of chemical markers for the quality control of medicinal plants of the genus *Cecropia*. *Pharm. Biol.*, *55*(1), 1500-1512. 10.1080/13880209.2017.1307421

Sharifi, S., Hajipour, M. J., Gould, L., & Mahmoudi, M. (2021). Nanomedicine in Healing Chronic Wounds: Opportunities and Challenges. *Molecular pharmaceutics*, *18*(2), 550–575. 10.1021/acs.molpharmaceut.0c00346

Sorg, H., Tilkorn, D. J., Hager, S., Hauser, J., & Mirastschijski, U. (2017). Skin wound healing: an update on the current knowledge and concepts. *Eur. Surg. Res.*, *58*(1-2), 81-94. 10.1159/000454919

Souccar, C., Cysneiros, R. M., Tanae, M. M., Torres, L. M. B., Lima-Landman, M. T. R., & Lapa, A. J. (2008). Inhibition of gastric acid secretion by a standardized aqueous extract of *Cecropia glaziovii* Sneth and underlying mechanism. *Phytomedicine*, *15*(6-7), 462-469. 10.1016/j.phymed.2008.02.00

Stange, V. S., Gomes, T. D., Andrade, M. A. D., & Batitucci, M. D. C. P. (2009). Evaluation of mutagenic effect of crude hydroalcoholic extract, using in vivo alive bioassays and phytochemical screening of *Cecropia glaziovii* Sneth (embaúba), *Cecropiaceae*. *Braz. J. Pharmacog.*, *19*, 637-642. 10.1590/S0102-695X2009000400023

Tanae, M. M., Lima-Landman, M. T. R., De Lima, T. C. M., Souccar, C., & Lapa, A. J. (2007). Chemical standardization of the aqueous extract of *Cecropia glaziovii* Sneth endowed with antihypertensive, bronchodilator, antacid secretion and antidepressant-like activities. *Phytomedicine*, *14*(5), 309-313. 10.1016/j.phymed.2007.03.002

Vitale, S., Colanero, S., Placidi, M., Di Emidio, G., Tatone, C., Amicarelli, F., & D'Alessandro, A. M. (2022). Phytochemistry and Biological Activity of Medicinal Plants in Wound Healing: An Overview of Current Research. *Molecules (Basel, Switzerland)*, 27(11), 3566. 10.3390/molecules27113566

Wang, P. (2018). H, Huang B-S, Horng H-C, Yeh C-C, Chen Y-J. Wound healing. *J Chin Med Assoc*, 2(81), 94-101. 10.1016/j.jcma.2017.11.002

Young, A., & McNaught, C. E. (2011). The physiology of wound healing. *Surgery (Oxford)*, 29(10), 475-479. 10.1016/j.mpsur.2011.06.011

Table 1. Formula for preparation of gel containing *C. glaziovii* 5%

Components	Quantity
CMC	0.3g
EDTA	0.01g
Preservative solution	0.33ml
Purified water q.s.p.	10ml
<i>Cecropia glaziovii</i>	5%

Table 2. Experimental groups

Groups (6 animals per group)	Description	Euthanasia and material collection
Positive control group - PC (subdivided into 3, 7, 14, and 21 days of treatment)	With a lesion in the dorsal region, treated only with base gel.	4th, 8th, 15th, and 22nd day according to the subdivision.
<i>Cecropia glaziovii</i> Group - CEC (subdivided into 3, 7, 14, and 21 days of treatment)	With a lesion in the dorsal region and treated with <i>Cecropia glaziovii</i> gel.	4th, 8th, 15th, and 22nd day according to the subdivision.

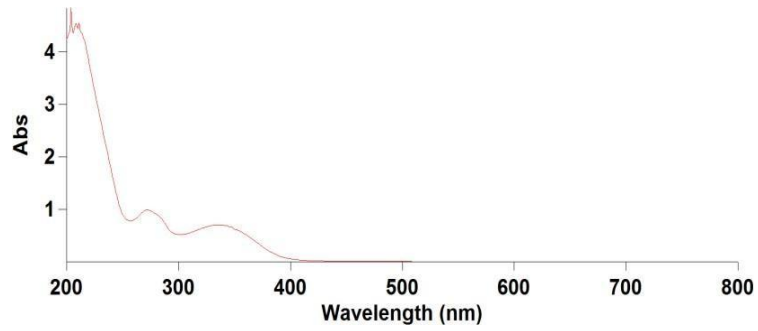


Fig. 1: Plot of molar absorbance versus wavelength for the 5% *C. glaziovii* solution.



Fig. 2: *C. glaziovii* gel.
Source: Collection of the author.

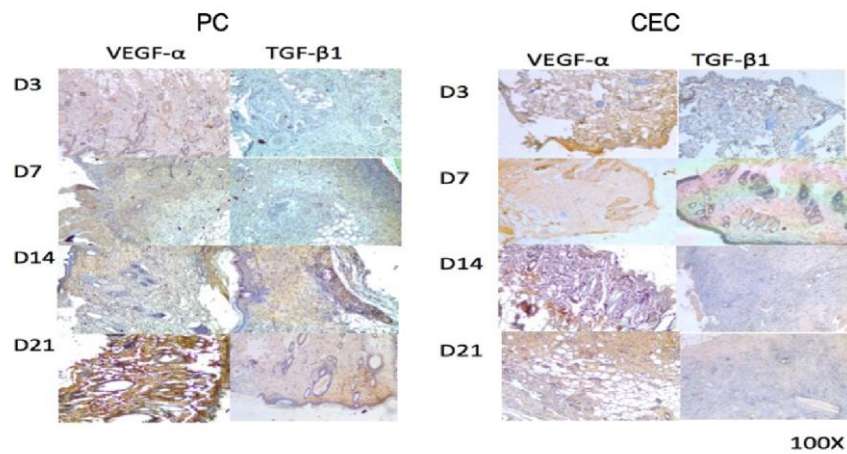


Figure 3 - Photomicrograph of immunohistochemical sections of the PC and CEC groups at 3, 7, 14, and 21 days of treatment with primary anti-VEGF and anti-TGF antibodies. Optical microscopy, 100x.

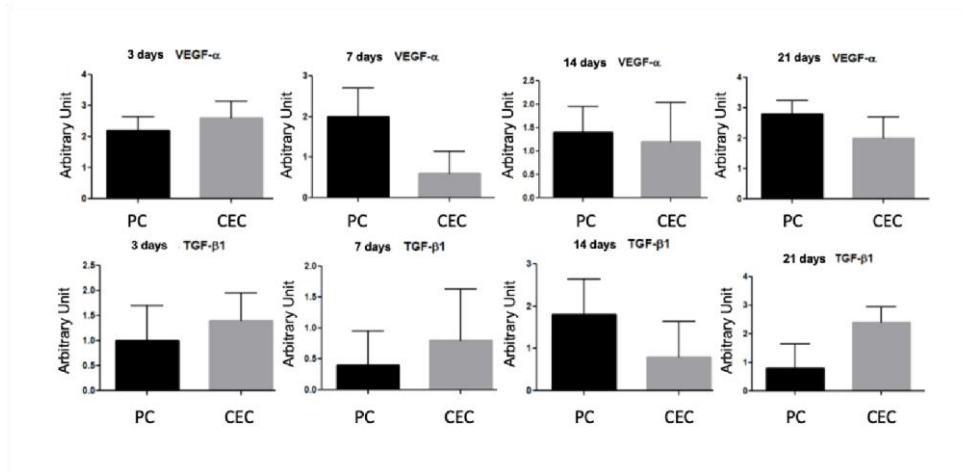


Figure 4 - Graphs with mean values for quantitative analysis of VEGF- α and TGF- β 1 from the PC and CEC groups at 3, 7, 14, and 21 days of treatment.

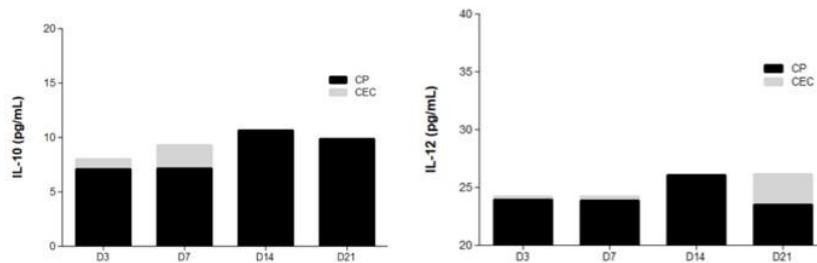


Figure 5 - Graphs with mean values and standard deviation for quantitative analysis of IL-10, MCP-1, IL-12p70 in the groups PC and CEC at 3, 7, 14, and 21 days of treatment.

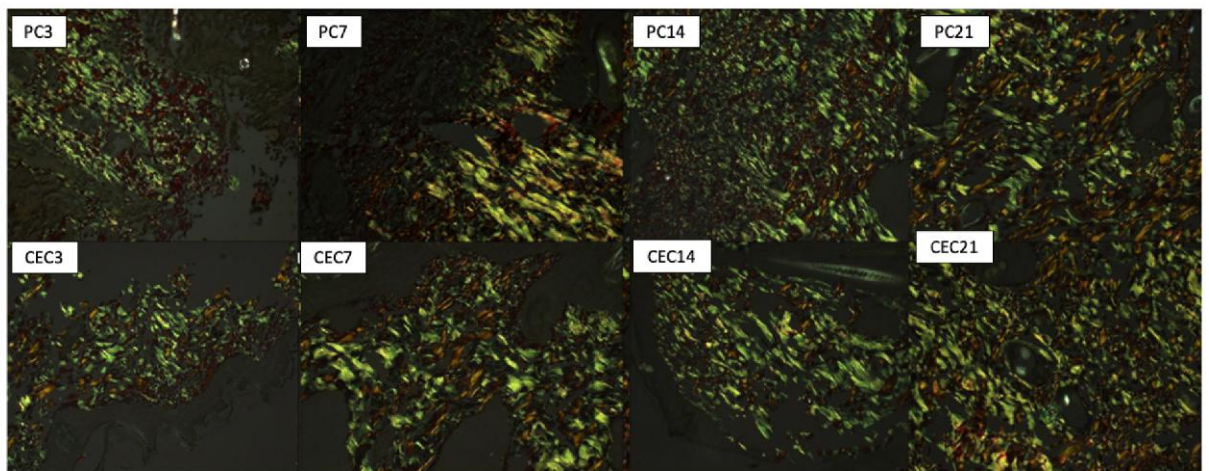


Figure 6 - Photomicrography of the animals of the PC and CEC groups at 3, 7, 14, and 21 days of treatment. Polarization microscopy, 400x. *Picosirius green* staining.

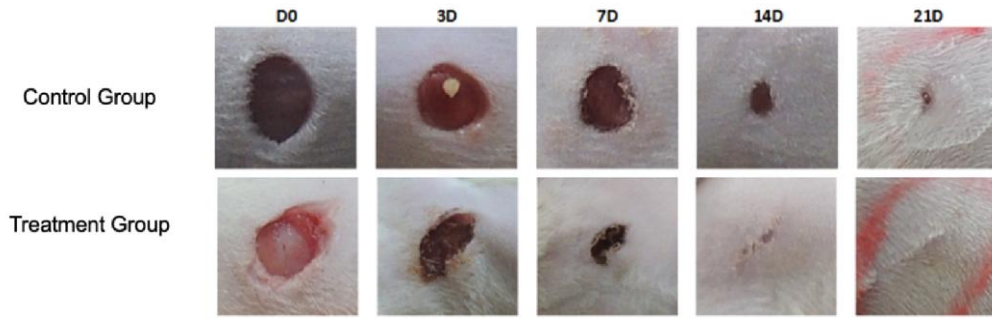


Figure 7 - Lesions in the PC and CEC groups at the day of the lesion and at 3, 7, 14, and 21 days of treatment.

UNDER PEER REVIEW